University of Nebraska - Lincoln
DigitalCommons@University of Nebraska - Lincoln

Special Education and Communication Disorders Faculty Publications

Department of Special Education and Communication Disorders

1-1-2007

Vestibular-evoked myogenic potentials

Julie A. Honaker
University of Nebraska at Lincoln, jhonaker2@unl.edu

Ravi N. Samy
University of Cincinnati College of Medicine, samyrs@ucmail.uc.edu

Follow this and additional works at: http://digitalcommons.unl.edu/specedfacpub

Part of the Special Education and Teaching Commons

Honaker, Julie A. and Samy, Ravi N., "Vestibular-evoked myogenic potentials" (2007). *Special Education and Communication Disorders Faculty Publications.* Paper 23.
http://digitalcommons.unl.edu/specedfacpub/23

This Article is brought to you for free and open access by the Department of Special Education and Communication Disorders at DigitalCommons@University of Nebraska - Lincoln. It has been accepted for inclusion in Special Education and Communication Disorders Faculty Publications by an authorized administrator of DigitalCommons@University of Nebraska - Lincoln.

Published in *Current Opinion in Otolaryngology & Head and Neck Surgery* 15 (2007), pp. 330–334. Copyright © 2007 Lippincott Williams & Wilkins. Used by permission.

Vestibular-evoked myogenic potentials

Julie A. Honaker and Ravi N. Samy

The Neuroscience Institute, Department of Otolaryngology, Head and Neck Surgery, University of Cincinnati College of Medicine, Cincinnati, Ohio, USA

Corresponding author — Ravi N. Samy, MD, FACS, The Neuroscience Institute, Department of Otolaryngology Head and Neck Surgery, University of Cincinnati, Cincinnati Children's Hospital Medical Center, 231 Albert Sabin Way, Cincinnati, OH 45267-0528, USA; tel 513 558-3563, fax 513 558-7702, email ravi.samy@uc.edu

Abstract

Purpose of review: This article reviews the literature on vestibular-evoked myogenic potential testing, a short latency electromyogram evoked by high acoustic stimuli and recorded via surface electrodes over the sternocleidomastoid muscle. Applications and refinements of this technique are described for different pathologies and in adults and children.

Recent findings: Various techniques for electrode placement have been described to elicit a vestibular-evoked myogenic potential response, which has been clinically investigated in normal individuals, under pathological conditions, and in adult and pediatric patients. As vestibular-evoked myogenic potential amplitude is linearly related to the level of background activity of the sternocleidomastoid muscle, maintaining steady contraction of the muscle can be challenging in some patients.

Summary: Vestibular-evoked myogenic potential testing may provide additional information about the vestibular system and allow site of lesion testing (e.g. saccule and inferior vestibular nerve) in patients of all ages. Its role has yet to be defined in the diagnosis and treatment of common vestibular disorders, including Meniere's disease, vestibular neuronitis, labyrinthitis, and other diseases. Further research is needed to support its clinical usefulness in patients with balance disorders, to optimize patient selection, and to establish its cost effectiveness.

Keywords: clinical vestibular tests, vestibular-evoked myogenic potential, vestibular function

Abbreviations: SCM — sternocleidomastoid muscle; VEMP — vestibular-evoked myogenic potential

Introduction

Vestibular-evoked myogenic potential (VEMP) testing is a relatively noninvasive method to assess patients with vestibular disorders [1]. Although they are among the most recent of innovations to the clinical vestibular testing, these protocols were initially discussed in the early 1960s [2]. VEMPs are believed to be a good indicator of saccular and inferior vestibular nerve function in clinical evaluations. When compared with the most commonly ordered clinical vestibular tests (e.g. electronystagmogram and rotary chair) that evaluate the pathway between the horizontal semicircular canal and the oculomotor nuclei (via the vestibulo-ocular reflex or VOR), this electrophysiological test is specific to otolith (saccule) and vestibulospinal reflex function. The VEMP pathway has been speculated to include the saccule, inferior vestibular nerve, vestibular nucleus, and medial and lateral vestibulospinal tract to the ipsilateral sternocleidomastoid muscle (SCM) [3]. Thus, VEMPs indirectly measure vestibular function through a vestibulocollic reflex.

Methods of vestibular-evoked myogenic potential recording

The VEMPs are short latency electromyograms (EMGs) evoked by high-acoustic stimuli at the ipsilateral ear and recorded via surface electrodes over a tonically contracted SCM [4,5]. They can be used for site of lesion testing because the testing has primarily an ipsilateral response. As this response is present in patients with deafness, the response arises from activation of the vestibular apparatus and not the cochlea. The amplitude has been shown to be diminished or absent in patients with normal hearing and decreased vestibular function [5,6]. Early research by Colebatch and Halmagyi [1,4–6] established that loud clicks evoked an initial inhibitory potential to the tonically contracted ipsilateral SCM by stimulating the vestibular system. This underlying theory gave rise to the possibility of VEMPs as a new form of investigating vestibular or balance disorders.

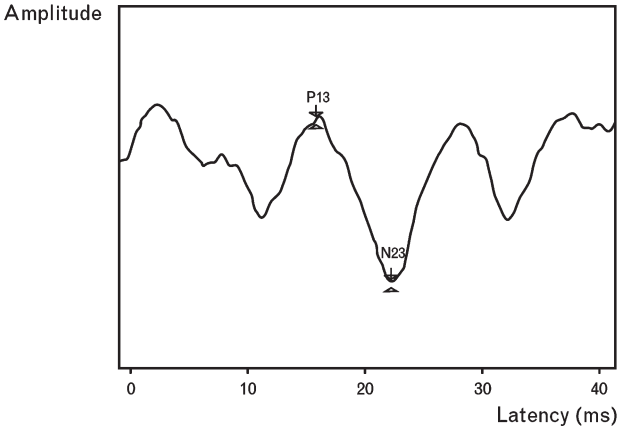

Figure 1. Example of a normal vestibular-evoked myogenic potential waveform

Vestibular-evoked myogenic potential waveform

The response waveforms are labeled p13-n23, n34, and p44. The first two responses, however, are the most easily recorded and noted. Although the potential starts at approximately 8 ms, it has a first positive peak at 13 ms and a second negative peak at 23 ms [5] (Fig. 1).

Vestibular-evoked myogenic potential response techniques: electrode placement and sternocleidomastoid muscle contraction

Numerous articles published within the past decade have reported on the experimental and clinical benefits of VEMP testing. The technique for VEMP testing is simple; equipment suitable for recording brainstem auditory-evoked potentials is also capable of recording VEMPs [3]. Bilateral active electrodes are placed over the middle or upper portion of the SCMs [4,7]. Reference and ground electrodes are placed over the upper sternum and midline of the forehead, respectively. The patient should lie supine; the head is either slightly raised, or elevated and turned as far as possible to activate the SCM. Some researchers instruct the patient to remain seated either pressing the forehead against a bar in front of them [8], or turning the head to the contralateral side to contract the sternocleidomastoid muscle [9–13]. In a unique approach to contract the SCM muscles, Ferber-Viart et al. [14] had their patients seated in armchairs with their chins pointed down to their chests. A rubber ball that was connected to a recording device was placed under the chins. This setup allowed continuous monitoring of the contraction of muscles. In a comparison of head elevation versus head rotation methods, Wang and Young [15] obtained VEMPs for 20 healthy volunteers and 12 patients with cochleo-vestibular pathologies. With a pillow placed under the head, each patient was instructed either to maintain the head elevated in the pitch plane or rotate the head sideways to one shoulder with head down in the yaw plane. On the second day of VEMP testing, the order was reversed so head rotation was followed by head elevation. The results indicated a greater response rate for the elevation method (100%) compared with the rotation method (70%). The rotation method also revealed significantly smaller amplitude scores. According to Wang and Young [15], head rotation may serve as an alternative method to elicit VEMPs when responses cannot be elicited with the head elevation. Ito et al. [16*] examined changes in VEMP waveform morphology for five different head positions (upright, nose up, ear up, nose down, and ear down) relative to gravity. The VEMP responses, which were obtained via 500 Hz tone-burst in all positions, elicited no significant changes in VEMP amplitudes. Slight changes in n23 latencies were observed with the patient in an upright position. The VEMP amplitude has been shown to be linearly related to the level of background activity of the SCM [17]. Consequently, how to maintain steady contraction of the SCM muscle can be challenging in some elderly patients and young children.

Vestibular-evoked myogenic potential response techniques: acoustic stimuli and stimulation rate

In addition to the EMG recording, loud clicks between 95 and 105 dB above normal hearing level are presented to the patient via an insert or supra-aural headphones [14]. Researchers who have outlined the use of tone bursts as an alternative to click presentation successfully used tone bursts of 500 and 1000 Hz [18]. Typically, 100– 250 VEMP responses are averaged for each ear; stimulation rates are set at approximately 3 or 5 Hz [17]. Researchers hypothesize that the reason VEMP amplitude decreases as repetition rate increases could be an adaptation of vestibular end organs. It is felt that the 5 Hz stimulation rate is optimal for clinical use [18]. Although the most common presentation method for eliciting VEMP responses is air conduction sound presentation, the utility of bone conduction has gained some attention; a stimulus rate of 10 Hz could be used clinically to produce a high amplitude wave for bone-conduction presentation [19].

Normative data

The VEMP p13-n23 response waveform can be obtained in nearly all normal individuals younger than 65 years old without significant conductive hearing loss [1]. Healthy individuals occasionally lack a VEMP response after repeated trials, possibly because of insufficient muscular effort and fatigue [17]. Brantberg and Fransson [20] reported that binaural acoustic stimulation led to symmetric VEMPs that could save time and muscle fatigue. Welgampola and Colebatch [21] and Ochi and Ohashi [12] reported that in patients older than 60–65 years, click-evoked VEMP amplitudes decreased; this decrease was probably caused by morphological changes in the ves-

tibular system that led to a decreased magnitude of the VEMP response. Ochi and Ohashi addressed the possibility that the decline in response amplitude was not a result of age but reduced tension in the SCM muscle during recording. In a 2007 study to evaluate age-related VEMP changes in amplitude for 1000 patients, Brantberg et al. [22] reported that decline in VEMP amplitude increases with age (>60 years of age) and VEMP latencies increase with age. The authors speculated that these decreased amplitudes may be associated with age-related structural changes within the middle ear.

Differential diagnosis with vestibular-evoked myogenic potential testing

The VEMP response has been clinically investigated in several pathological conditions, including acoustic neuromas [9,10,23–26], vestibular neuronitis [27,28], Meniere's disease [11,29,30], sensorineural hearing loss, [5,31,32], multiple sclerosis [8,33], and superior canal dehiscence syndrome [34,35].

Central lesions

Pollak et al. [36] argued that reports of VEMP findings in central lesions are scarce. Hypothesizing that cerebellar lesions may impact VEMP waveform morphology, the researchers reported on patients who underwent testing, including 19 patients after a cerebellar ischemic cerebrovascular accident (CVA) and 15 patients with lower brainstem ischemic CVA. Mean latencies of VEMP waveform in each group did not significantly differ from those obtained in normal controls. Further studies to compare VEMP with brainstem lesions were recommended as the authors found no significant changes in the VEMP pattern between patients with cerebellar lesions and controls or between patients with brainstem strokes and controls.

Meniere's disease

Murofushi et al. [11] reviewed the results of VEMPs in patients with Meniere's disease, vestibular neuronitis, acoustic neuromas, and multiple sclerosis. The researchers established that in patients with Meniere's disease or vestibular neuronitis, the latency of the waveform was not affected; however, the amplitude of the waveform was greatly affected, which could be considered an abnormal response. In patients with multiple sclerosis and other central vestibular disorders, the amplitude of the waveform was intact; however, the latency was prolonged, which could be suggestive of a lesion of the vestibulospinal system. Patients with Meniere's disease have exhibited increased VEMP thresholds and altered frequency tuning of the VEMP response [37]. Lin et al. [38] questioned if this change in VEMP response was also seen in unaffected ears of patients with unilateral Meniere's disease. Through postmortem histopathologic evaluation of the temporal bone in patients with unilateral Meniere's disease and 82 current patients with unilateral Meniere's disease, the authors concluded that endolymphatic hydrops appears to precede symptoms of Meniere's disease. Their study, however, showed that 25% of the asymptomatic ears had saccular endolymphatic hydrops. These VEMP results indicated that 27% of the patients had increased VEMP thresholds and altered frequency tuning. Even with the researchers' conclusions, however, it remains unproven if patients with abnormal VEMP responses in the asymptomatic ear will ultimately develop symptoms of Meniere's disease. In a related study, Timmer et al. [39] hypothesized that VEMP abnormalities would be greater in the ears of patients with Meniere's disease with drop attacks than in patients with normal ears or those with Meniere's ears without drop attacks. In a retrospective review, the authors performed VEMP testing on three groups of individuals: patients with Meniere's disease without a history of drop attacks, those diagnosed with Meniere's disease and a history of drop attacks, and normal controls. The VEMP response was absent in 41% of ears affected by drop attacks and in 13% of ears affected by Meniere's disease; VEMP response was always present in normal ears. The alterations of frequency tuning and increased threshold findings were present in the patients with Meniere's disease as well as those with Meniere's disease and drop attacks. Unaffected ears of patients with Meniere's disease, however, also showed slight threshold and tuning changes. Timmer et al. and Lin et al. concluded that VEMP measures may provide value when monitoring patients with Meniere's disease.

Vestibular-evoked myogenic potential response in children

Compared with the numerous studies on VEMP response in adults, limited normative data exist in children. Kelsch et al. [40] examined the reproducibility of VEMP testing in children with depiction of the latencies, thresholds, and amplitudes. Thirty preschool and school-aged children underwent comprehensive audiograms and click VEMP testing. The VEMPs were obtained at 90 dB above normal hearing level for the children aged 3–11 years; however, the p13-n23 latencies occurred earlier than those described by Colebatch et al. [5]. The VEMP responses have been recorded in infants aged 1–12 months [41]. Identification of the maturity of the sacculocollic reflex maturity at birth via VEMP testing had remained unexplored until the 2007 study by Chen et al. [42*], in which tone-burst stimulation was given during VEMP testing for 20 newborns. Chen et al. found normal VEMP responses in 40% of the ears, prolonged VEMP in 35%, and in 25% absent VEMPs. In infants, activation of the SCM could not be performed with conventional head elevation methods. Rather the head rotation method may serve as a means to evaluate sacculocollic reflex maturation in infants. Infants with

absent or prolonged results may indicate incomplete maturity of the reflex pathway. With the increasing occurrence of pediatric patients with symptoms of dizziness, VEMP testing may be a means to evaluate unilateral vestibular function.

Conclusion

VEMP testing is a relatively new clinical testing modality that may provide additional information about the vestibular system and allow site of lesion testing (e.g. saccule and inferior vestibular nerve) in both pediatric and adult patients. Its role has yet to be defined in the diagnosis and treatment of common vestibular disorders, including Meniere's disease, vestibular neuronitis, labyrinthitis, and other diseases. Further research is needed to support the clinical usefulness of this test in everyday balance disorder practice, to identify the appropriate candidates for VEMP testing, and establish the cost-effectiveness of the test. At our institution, we are currently obtaining normative data and will be evaluating alterations in VEMP testing, such as after endolymphatic mastoid shunt procedures.

Acknowledgments

The authors thank Mary Kemper of The Neuroscience Institute for her valuable assistance and expertise as a medical editor.

References and recommended reading

*Papers of particular interest, published within the annual period of review, have been highlighted with an asterisk: **

1 Colebatch J. Vestibular evoked potentials. Curr Opin Neurol 2001; 14:21– 26.

2 Bickford RG, Jacobson JL, Cody DTR. Averaged potentials to sound and other stimuli in man. Ann N Y Acad Sci 1964; 112:204–223.

3 Halmagyi GM, Curthoys IS. Otolith function tests. In: Wolf SL, editor. Vestibular rehabilitation, 2nd ed. Philadelphia: F.A. Davis; 2000. pp. 196– 214.

4 Colebatch J, Halmagyi GM. Vestibular evoked potentials in human neck muscles before and after unilateral vestibular deafferentation. Neurology 1992; 42:1635–1636.

5 Colebatch J, Halmagyi GM, Skuse NF. Myogenic potentials generated by a click-evoked vestibulocullic reflex. J Neurol 1994; 57:190–197.

6 Halmagyi GM, Colebatch JG. Vestibular evoked myogenic potentials in the sternomastoid muscle are not of lateral canal origin. Acta Otolaryngol (Stockh) 1995; 520:1–3.

7 Sheykholeslami K, Murofushi T, Kaga K. The effect of sternocleidomastoid electrode location on vestibular evoked myogenic potential. Auris Nasus Larynx 2001; 28:41–43.

8 Versino M, Colnaghi S, Callieco R, et al. Vestibular evoked myogenic potentials in multiple sclerosis patients. Clin Neurophysiol 2002; 113: 1464–1469.

9 Matsuzaki M, Murofushi T, Mizuno M. Vestibular evoked myogenic potentials in acoustic tumor patients with normal auditory brainstem responses. Eur Arch Otorhinolaryngol 1999; 256:1–4.

10 Murofushi T, Matsuzaki M, Mizuno M. Vestibular evoked myogenic potentials in patients with acoustic neuromas. Arch Otolaryngol Head Neck Surg 1998; 124:509–512.

11 Murofushi T, Shimizu K, Takegoshi H, Cheng P. Diagnostic value of prolonged latencies in the vestibular evoked myogenic potential. Arch Otolaryngol Head Neck Surg 2001; 127:1069–1072.

12 Ochi K, Ohashi T. Age-related changes in the vestibular-evoked myogenic potentials. Otolaryngol Head Neck Surg 2003; 129:655– 659.

13 Ochi K, Ohashi T, Nishino H. Variance of vestibular-evoked myogenic potentials. Laryngoscope 2001; 111:522–527.

14 Ferber-Viart C, Duclaux R, Colleaux B, Dubreuil C. Myogenic vestibular-evoked potentials in normal subjects: a comparison between responses obtained from sternomastoid and trapezius muscles. Acta Otolaryngol (Stockh) 1997; 117:472–481.

15 Wang C, Young Y. Comparison of the head elevation versus rotation methods in eliciting vestibular evoked myogenic potentials. Ear Hear 2006; 27:376– 381.

16* Ito K, Karino S, Murofushi T. Effect of head position on vestibular evoked myogenic potentials with toneburst stimuli. Acta Otolaryngol 2007; 127:57– 61. *This paper outlines the strength of VEMP when using tone burst stimuli regardless of head position during testing.*

17 Wang S, Young Y. Vestibular evoked myogenic potentials using simultaneous binaural acoustic stimulation. Hear Res 2003; 185:43–48.

18 Wu C, Murofushi T. The effect of click repetition rate on vestibular evoked myogenic potential. Acta Otolaryngol (Stockh) 1999; 119:29–32.

19 Sheykholeslami K, Kermany MH, Kaga K. Frequency sensitivity range of the saccule to bone-conducted stimuli measured by vestibular evoked myogenic potentials. Hear Res 2001; 160:58–62.

20 Brantberg K, Fransson P. Symmetry measures of vestibular evoked myogenic potentials using objective detection criteria. Scand Audiol 2001; 30:189– 196.

21 Welgampola MS, Colebatch JG. Vestibulocollic reflexes: normal values and the effect of age. Clin Neurophysiol 2001; 112:1971–1979.

22 Brantberg K, Granath K, Schart N. Age-related changes in vestibular evoked potentials. Audio Neurootol 2007; 12:247–253.

23 Magliulo G, Gagliardi M, Appiani G, Amico R. Preservation of the saccular nerve and of vestibular evoked myogenic potential during vestibular schwannoma surgery. Otol Neurotol 2003; 24:308–311.

24 Patko T, Vidal P, Vibert N, et al. Vestibular evoked myogenic potentials in patients suffering from an unilateral acoustic neuroma: a study of 170 patients. Clin Neurophysiol 2003; 114:1344–1350.

25 Tsutsumi T, Komatsuzaki A, Noguchi Y, Tokano H. Postoperative vestibular-evoked myogenic potentials in cases with vestibular schwannomas. Acta Otolaryngol 2001; 121:490–493.

26 Tsutsumi T, Tsunoda A, Noguchi Y, Komatsuzaki A. Prediction of the nerves of origin of vestibular schwannomas with vestibular evoked myogenic potentials. Am J Otol 2000; 21:712–715.

27 Murofushi T, Halmagyi GM, Yavor RA, et al. Absent vestibular evoked myogenic potentials in vestibular neurolabyrinthitis: an indicator of inferior vestibular nerve involvement? Arch Otolaryngol Head Neck Surg 1996; 122:845–848.

28 Ochi K, Ohashi T, Watanabe S. Vestibular evoked myogenic potential in patients with unilateral vestibular neuritis: abnormal VEMP and its recovery. J Laryngol Otol 2003; 117:104–108.

29 de Waele C, Huy PT, Diard J, et al. Saccular dysfunction in Meniere's disease. Am J Otol 1999; 20:223–232.

30 Young Y, Huang T, Cheng P. Assessing the stage of Meniere's disease using vestibular evoked myogenic potentials. Arch Otolaryngol Head Neck Surg 2003; 129:815–818.

31 Ozeki H, Matsuzaki M, Murofushi T. Vestibular evoked myogenic potentials in patients with bilateral profound hearing loss. J Otorhinolaryngol Relat Spec 1999; 61:80–83.

32 Wu C, Young Y. Vestibular evoked myogenic potentials are intact after sudden deafness. Ear Hear 2002; 23:235–238.

33 Sartucci F, Logi F. Vestibular-evoked myogenic potentials: a method to assess vestibulo-spinal conduction in multiple sclerosis patients. Brain Res Bull 2002; 59:59–63.

34 Brantberg K, Bergenius J, Tribukait A. Vestibular-evoked myogenic potentials in patients with dehiscence of the superior semicircular canal. Acta Otolaryngol 1999; 119:633–640.

35 Streubel S, Cremer P, Carey J, et al. Vestibular-evoked myogenic potentials in the diagnosis of superior canal dehiscence syndrome. Acta Otolaryngol (Suppl) 2001; 545:41–49.

36 Pollak L, Kushnir M, Stryjer R. Diagnostic value of vestibular evoked myogenic potentials in cerebellar and lower-brainstem stroke. Neurophysiol Clin 2006; 36:227–233.

37 Rauch SD, Zhou G, Kujawa SG, et al. Vestibular-evoked myogenic potentials show altered tuning in patients with Meniere's disease. Otol Neurotol 2004; 25:333–338.

38 Lin M, Timmer FCA, Oriel BS, et al. Vestibular evoked myogenic potentials (VEMP) can detect asymptomatic saccular hydrops. Laryngoscope 2006; 116:987–992.

39 Timmer FCA, Zhou G, Guinan JJ, et al. Vestibular evoked myogenic potential (VEMP) in patients with Meniere's disease with drop attacks. Laryngoscope 2006; 116:776–779.

40 Kelsch TA, Schaefer LA, Esquivel CR. Vestibular evoked myogenic potentials in young children: test parameters and normative data. Laryngoscope 2006; 116:895–900.

41 Sheykholesami K, Kaga K, Megerian CA, Arnold JE. Vestibular-evoked myogenic potentials in infancy and early childhood. Laryngoscope 2005; 115:1440–1444.

42* Chen C, Wang S, Wang C, et al. Vestibular evoked myogenic potentials in newborns. Audio Neurotol 2007; 12:59–63. *This paper provides an innovative method for eliciting VEMP in newborns.*