University of Nebraska - Lincoln
DigitalCommons@University of Nebraska - Lincoln

Papers in Veterinary and Biomedical Science | Veterinary and Biomedical Sciences, Department of

1-1-1992

Diarrhea associated with *Enterococcus durans* in calves

Douglas G. Rogers
University of Nebraska - Lincoln, drogers1@unl.edu

David H. Zeman
South Dakota Animal Disease Research and Diagnostic Laboratory, Department of Veterinary Science, Brookings, SD

E. Denis Erickson
University of Nebraska - Lincoln

Follow this and additional works at: http://digitalcommons.unl.edu/vetscipapers

Part of the Veterinary Medicine Commons

Rogers, Douglas G.; Zeman, David H.; and Erickson, E. Denis, "Diarrhea associated with *Enterococcus durans* in calves" (1992). *Papers in Veterinary and Biomedical Science.* Paper 30.
http://digitalcommons.unl.edu/vetscipapers/30

This Article is brought to you for free and open access by the Veterinary and Biomedical Sciences, Department of at DigitalCommons@University of Nebraska - Lincoln. It has been accepted for inclusion in Papers in Veterinary and Biomedical Science by an authorized administrator of DigitalCommons@University of Nebraska - Lincoln.

J Vet Diagn Invest 4:471-472 (1992)

Diarrhea associated with *Enterococcus durans* in calves

Douglas G. Rogers, David H. Zeman, E. Denis Erickson

Enterococci in the alimentary tract of animals are believed to be commensal bacteria.[3] However, *Enterococcus durans* has been associated with diarrhea in foals, piglets, and puppies.[1,4,5] The possibility that *E. durans* is associated with diarrhea in calves has not been established, although gram-positive cocci adhered to villi, occasionally together with Cryptosporidia, have been seen histologically in the small intestine of diarrheic calves.[4] This report describes the association of *E. durans* and diarrhea in 4 calves,

Samples from 3 1-3-week-old diarrheic mixed breed beef calves (calves 1, 2, and 3) were submitted for laboratory evaluation. The samples submitted varied with each case but included fresh and formalin-fixed jejunum (3), ileum (2), colon (l), abomasum (l), spleen (3), liver (2), and lung (1) and 1 liter of milky-white intestinal content (1). Calf 4 was a 1-week-old mixed breed beef calf that was presented dead for necropsy. The owner reported that this calf had died without clinical signs. At necropsy, the presence of watery

From the Veterinary Diagnostic Center, University of Nebraska, Lincoln, NE 68583-0907 (Rogers, Erickson), and the South Dakota Animal Disease Research and Diagnostic Laboratory, Department of Veterinary Science, Brookings, SD 57007-1396 (Zeman).

Received for publication January 23, 1992.

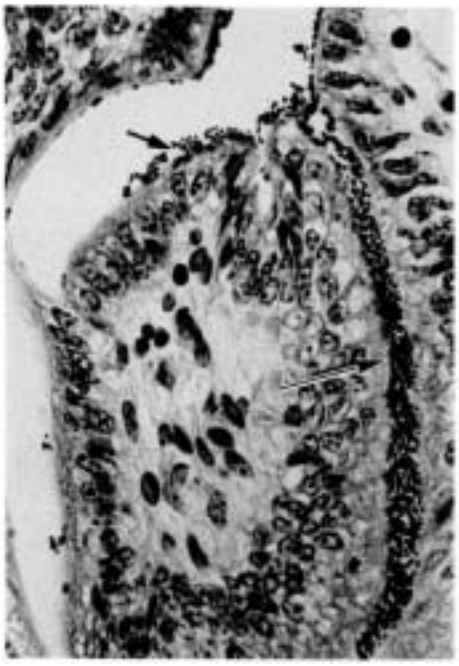

Figure 1. Jejunum from calf 1 with diarrhea. Bacteria (arrows) adhered to villi. Brown-Brenn Gram stain.

Table 1. Results of laboratory evaluations of tissues from 4 diarrheic calves.

Calf no.	Histopathology: Small intestine	Histopathology: Colon	Bacteriology*	Virology†
1	hyperemia, mild villus atrophy, moderate numbers gram-positive‡ cocci adhered to villi, desquamated apical enterocytes, small numbers of neutrophils in lamina propria and crypts	no lesions	large numbers of *Enterococcus durans*	negative
2	hyperemia, mild villus atrophy, moderate numbers of gram-positive cocci adhered to villi, desquamated apical enterocytes, small numbers of neutrophils in lamina propria and crypts	not submitted	large numbers of *E. durans*	negative
3	hyperemia, mild villus atrophy, moderate numbers of gram-positive cocci adhered to villi	not submitted	large numbers of *E. durans*, small numbers of hemolytic *Escherichia coli*	BVDV positive (small intestine)
4	hyperemia, moderate villus atrophy, large numbers gram-positive cocci and cryptosporidia adhered to villi, multifocal cryptal necrosis	multifocal cryptal necrosis	large numbers of *E. durans*	BVDV positive, direct immunofluorescence (small intestine); rotavirus positive, electron microscopy (intestinal contents)

* Isolates from small intestine.

† Appropriate samples were evaluated for rotavirus, coronavirus, and bovine viral diarrhea virus (BVDV) by direct immunofluorescence and for BVDV by virus isolation; intestinal contents (when available) were evaluated for virus by electron microscopy.

‡ Brown-Brenn Gram stain.

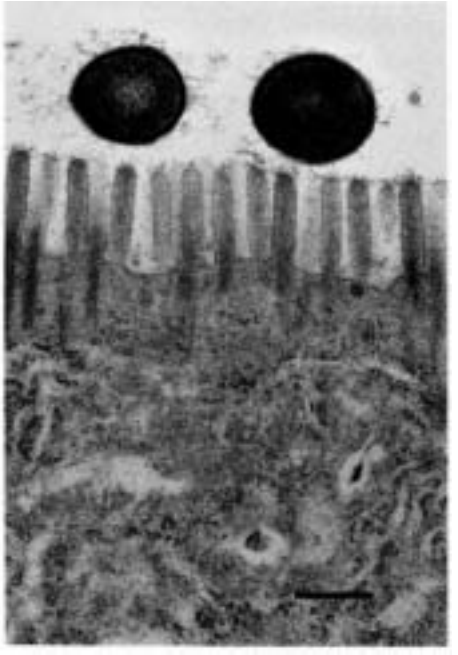

Figure 2. Jejunum from calf 1 with diarrhea. Bacteria closely associated with microvilli of enterocyte. Note rim of flocculent electron-dense material surrounding cocci. Bar = 0.5 μm.

ingesta in the distal jejunum, ileum, and colon was the most significant finding. Appropriate tissue samples from the 4 calves were processed for microscopic evaluation, aerobic and anaerobic bacteriologic culture, virologic evaluation using direct immunofluorescence, virus isolation, and, when feasible, electron microscopic examination of intestinal contents. In addition, samples of formalin-fixed small intestine from 1 calf were immersed in 3% glutaraldehyde in 0.1 M sodium phosphate buffer (pH 7.2) and processed for transmission electron microscopy.

Enterucoccus duruns was isolated in large numbers from the small intestine of each of the four calves (Table 1). Isolates of *E. durans* produced alpha hemolysis on 5% sheep blood agar plates and were identified by conventional and commercial[a] methods.[2] *Enterococcus durans* was considered to be strongly associated with diarrhea in calves 1, 2, and 3, and the histologic findings from these calves correlated with those cases involving foals[5] Bacteria were adhered to intestinal villi (Fig. 1). Ultrastructural examination of samples of small intestine from calf 1 revealed cocci adhered to or closely associated with microvilli on villus enterocytes. Cocci were 0.5-0.7 μm in diameter and often were surrounded by a rim of flocculent electron-dense material (Fig. 2). Detailed ultrastructural examination was not possible because of mild postmortem decomposition in the samples. The significance of the isolation of bovine viral diarrhea virus (BVDV) and small numbers of hemolytic *Escherichia coli* from the small intestine of calf 3 could not be determined; there were no lesions suggestive of BVDV infection. The possibility that BVDV caused cryptal necrosis in the small intestine and colon from calf 4 was considered. The cause of diarrhea in calf 4 was attributed to multiple pathogens, including *Elaterococcus durans.*

The pathogenesis of diarrhea associated with *E. durans* adherence is unknown. The bacterium is believed to adhere to villus enterocytes by fimbriaeelike structures.[1,4,5] Isolates of *E. durans* from foals do not produce enterotoxin in the isolated loops of pig intestine but they do depress brush border enzyme activity, possibly causing malabsorption[5] It is unknown whether treatment with antibiotics predisposes the small intestine to adherence by *E. durans.* Calf 1 was the only calf known to have been treated with an antibiotic prior to death.

Acknowledgement. We thank Tom Bargar for technical assistance. This report is submitted as paper no. 9821, Agricultural Research Division, Institute of Agriculture and Natural Resources, University of Nebraska-Lincoln.

Sources and manufacturers

a. Rapid Strep, API Analytical Products, Plainview, NY.

References

1. Collins JE, Bergeland ME, Lindemann CJ, Duimstra JR: 1988, *Enterococcus (Streptococcus) durans* adherence in the small intestine of a diarrheic pup. Vet Pathol 25:396-398.
2. Collins MD, Jones D, Farrow JAE, et al.: 1984, *Enterococcus avium* nom. rev., comb. nov.; *E. casselifavus* nom. rev., comb. nov.; *E. durans* nom. rev., comb. nov.; *E. galfinarum* comb. nov.; and *E. malodoratus* sp. nov. Int J Syst Bacterial 34:220-223.
3. Diebel RH: 1964, The group D streptococci. Bacterial Rev 28: 330-366.
4. Johnson DD, Duimstra JR, Gates CE, McAdaragh JP: 1985, Enteric *Streptococcusdurans:* an adhering streptococcus as a cause of diarrhea in suckling piglets? Proc A Young Conf, Lincoln, NE, pp 1-8.
5. Tzipori S, Hayes J, Sims L: 1984, *Streptococcus durans:* an unexpected enteropathogen of foals. J Infect Dis 150:589-593.