University of Nebraska - Lincoln
DigitalCommons@University of Nebraska - Lincoln

Canadian Cooperative Wildlife Health Centre: Newsletters & Publications | Wildlife Damage Management, Internet Center for

10-1-1994

Canadian Cooperative Wildlife Health Centre, Volume 2-3, Fall 1994

Follow this and additional works at: http://digitalcommons.unl.edu/icwdmccwhcnews

Part of the Environmental Sciences Commons

"Canadian Cooperative Wildlife Health Centre, Volume 2-3, Fall 1994" (1994). *Canadian Cooperative Wildlife Health Centre: Newsletters & Publications.* Paper 31.
http://digitalcommons.unl.edu/icwdmccwhcnews/31

This Article is brought to you for free and open access by the Wildlife Damage Management, Internet Center for at DigitalCommons@University of Nebraska - Lincoln. It has been accepted for inclusion in Canadian Cooperative Wildlife Health Centre: Newsletters & Publications by an authorized administrator of DigitalCommons@University of Nebraska - Lincoln.

Canadian Cooperative Wildlife Health Centre

Centre Canadien Coopératif de la Santé de la Faune

Newsletter 2 - 3, Fall 1994

Feature Articles
Conditions Encountered in Hunter-Killed Game
Canine Distemper in New Hosts
Hantavirus Pulmonary Syndrome in British Columbia

Disease Updates:
Atlantic Region
Avian cholera and predation in nesting common eiders in New Brunswick
Drowning in northern gannets
Fetal mummification in beaver
Québec Region:
Prevalence of oral papilloma in White suckers
Tyzzer diseases in muskrats
Hepatic carcinoma in an Atlantic tomcod
Intestinal adenocarcinoma in a beluga whale
Ontario Region:
Botulism in Ring-billed Gulls
Lead Poisoning in Loons
Miscellaneous
Western/Northern Region:
Tiger salamander die-off
Botulism outbreak in Alberta
Waterbird mortality in Saskatchewan
Carbofuran poisoning in Saskatchewan

Feature Articles

Conditions Encountered in Hunter-Killed Game

The vast majority of wild animals are healthy and game meat, if properly handled, is wholesome. However, hunters are sometimes concerned about the appearance or safety of meat they have harvested. In some cases, this concern is a result of unfamiliarity with the appearance of normal structures, such as lymph nodes. Many of the concerns about game meat result from improper handling of the meat by the hunter. A full discussion of meat handling is not possible here, but the basic rules are very simple: Keep the meat clean, Cool meat as soon as possible, and Keep it cool.

The following are some disease conditions occasionally encountered in game animals:

a) Parasites

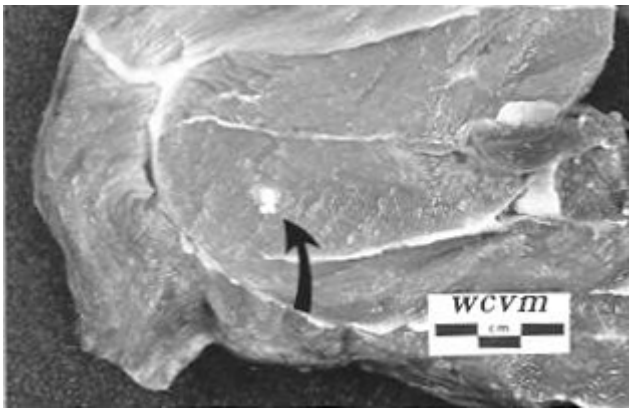

Figure 1. Cyst of the tapeworm Taenia ovis krabbei in moose muscle.

Larval tapeworm cysts: Tapeworms usually require two animal hosts to complete their life cycle. The species of concern here are those in which the larval or immature stage occurs in muscle or other tissues of game animals. If these larvae are eaten by an appropriate carnivore, the adult tapeworm will develop within the intestine of the carnivore. The larval stage of these tapeworms is not infectious for humans; however, many of the tapeworms found in game animals will develop in dogs. Game meat or viscera infected with larval tapeworms should never be fed raw to dogs or discarded where dogs may eat it. This is particularly important in the case of Echinococcus granulosus because dogs infected with that parasite will pass eggs in their feces that are infectious for humans.

Figure 2. Cysts of Taenia hydatigena that were attached to the internal surface of the abdomen of a bighorn sheep.

a) Taenia ovis krabbei: The larval stage of this tapeworm occurs as a yellow-white 1-2 cm cyst (Fig. 1) in skeletal (meat) or heart muscle of moose and caribou, and less commonly in the same tissues of elk, deer and bighorn sheep. Older animals may be heavily parasitized. The adult tapeworm occurs in the intestine of wolves and dogs. The parasite is destroyed by freezing or cooking. Heavily infected meat cannot be satisfactorily trimmed to remove the parasite and is aesthetically unpleasant but not dangerous.

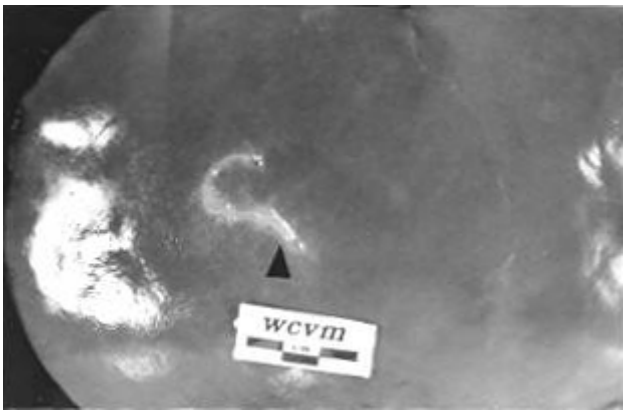

Figure 3. Tract made by a larva of Taenia hydatigena in the liver of a mule deer.

b) Taenia hydatigena: The larval stage may occur as a 2-3 cm fluid-filled cyst in the liver or attached to the abdominal wall (Fig. 2), or as a "worm-like" cyst in the liver (Fig. 3) of deer, moose, elk and bighorn sheep. The adult occurs in wolves, coyotes and dogs. The cysts can be readily trimmed from tissues and the meat is unaffected.

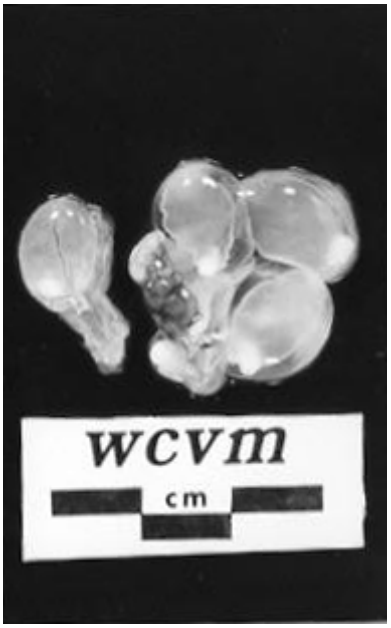

Figure 4. Larval cysts of Taenia pisiformis from the abdomen of a white-tailed jackrabbit.

c) Taenia pisiformis: The larval stage occurs as pea-sized cysts (Fig. 4) attached to the surface of the abdominal viscera of hares and rabbits. The cysts are usually removed with the viscera and the meat is unaffected. The adult stage occurs in coyotes, foxes and dogs.

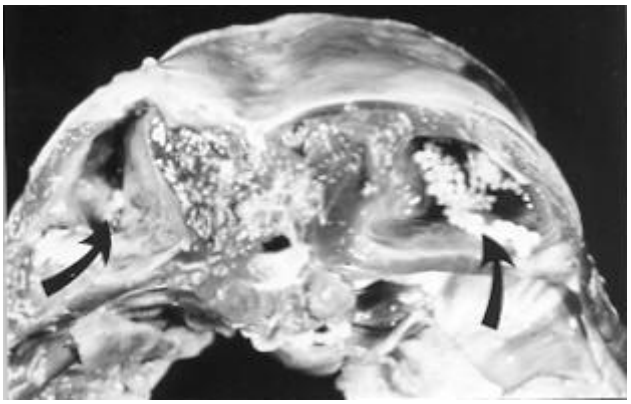

Figure 5. Cross-section through the back (loin) of a jackrabbit showing large cysts of Taenia serialis between the muscles. Each cyst contains many small white larvae.

d) Taenia serialis: The larvae occur as large (up to several cm in diameter) cysts under the skin and between muscles of rabbits, hares and squirrels (Fig. 5). The cysts can be easily trimmed from the tissues so the meat is unaffected. The adult stages occur in foxes, coyotes and dogs.

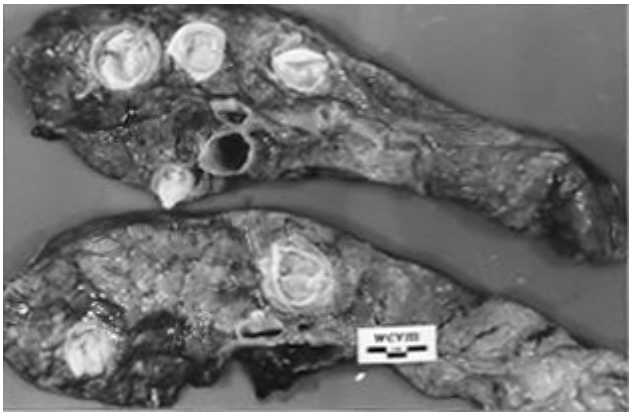

Figure 6. Cross-section through the lung of a moose. Several large hydatid cysts of Echinococcus granulosus have been opened to show the white lining membrane.

e) Echinococcus granulosus: The larval stage, called a "hydatid" cyst, is found in the lungs or liver of moose, elk, caribou, deer, and wild sheep. The cysts are white, fluid-filled, spherical and may range in size from a few millimetres to 15 cm; commonly they are marble to golfball -sized (Fig. 6). Because the cysts are removed with the lungs or liver ,the meat is unaffected. Cysts can be trimmed from the liver. Organs from animals infected with this parasite must not be fed to dogs or discarded where they are accessible by dogs. The eggs shed by infected dogs are infectious to humans and can cause severe disease. The adult tapeworm normally occurs in the intestine of wolves. Eggs passed in the feces of wolves remain infective for a long time and some eggs may cling to the fur beneath the tail. Trappers and biologists who handle wolf feces and pelts, should do so with caution.

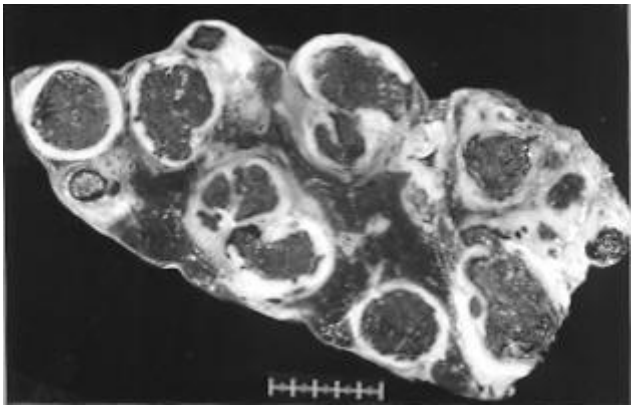

Figure 7. Cross-section through the liver of a moose. The large circular structures are thick-walled cysts filled with grey-black debris caused by the liver fluke Fascioloides magna.

Liver Flukes: The large liver fluke Fascioloides magna is found in certain areas of most provinces in Canada. It can infect elk, moose, deer, and caribou, as well as cattle, sheep and goats. The parasite is located in the liver and is usually noticed by the hunter because

the liver is misshapen and contains pockets or channels filled with grey or black putty-like material. The liver of infected moose is often shrunken, firm and distorted with extensive white fibrous tissue (Fig.7). This parasite has a complex life cycle involving freshwater snails. Meat from infected animals is not affected by the parasite. Sarcocystis in ducks: This is a protozoan parasite that causes yellow-white, rice grain-like cysts (Fig.8) in the muscle of dabbling ducks. It has a complex life cycle in which the striped skunk serves as the other host. The cysts are composed of a massive number of individual, microscopic parasites. The parasite is not infectious for humans but heavily infected ducks are aesthetically unpleasant . The cysts change color and become "invisible" in cooked meat.

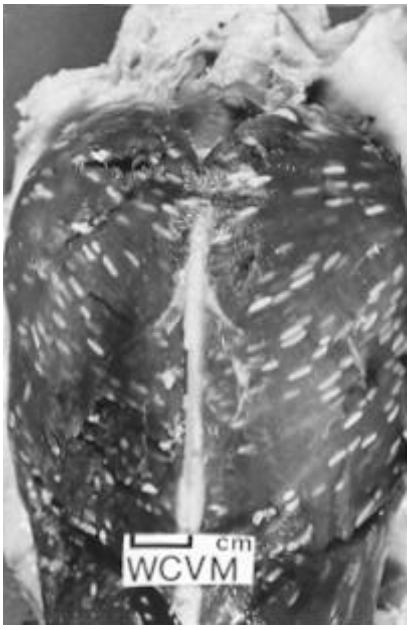

Figure 8. Sarcocystis cysts in the breast muscle of a mallard.

Abscesses: Abscesses result from introduction of bacteria into tissues and appear as pockets filled with semi-liquid pus. Many abscesses are secondary to trauma, such as gore wounds in males or bite wounds from predators. The content of abscesses must be treated as potentially infectious for humans. This is particularly true in barren ground caribou in which abscesses may contain the bacterium Brucella suis. In general, if the abscess is localized to a single area of the carcass and the animal appears otherwise normal, the affected portion can be trimmed off and discarded and the rest of the meat used. Care must be taken to ensure that other parts of the carcass do not become contaminated with contents of the abscess. If an abscess is accidentally cut into, the knife should not be used again until it has been washed thoroughly and sterilized either in boiling water or by soaking in a 1:5 solution of chlorine bleach in water. If abscesses are found in more than one site or if there is any evidence of ill health, e.g. emaciation, the animal likely had a generalized infection and the carcass should not be used for human consumption.

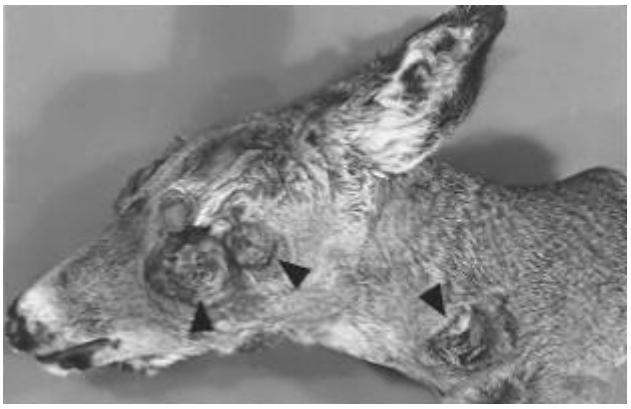

Figure 9. Skin tumours (papillomas) on the head of a white-tailed deer. This is an unusually severe case; most infected animals have only a single mass present.

Skin tumours: A variety of skin growths occur on rabbits, squirrels and big-game animals (Fig. 9). These are usually classed by pathologists as "fibromas" or "papillomas" which are benign tumours of fibrous tissue or skin, similar to warts in humans and in cattle. These tumours are caused by a virus that is distinct in each species, as are the viruses that cause warts in humans and in cattle. The tumours are removed with the skin and do not affect the suitability of the meat.

Canine Distemper in New Hosts

Canine distemper is an important disease of canids, mustelids and raccoons. Recently, canine distemper virus (CDV), or other closely related members of the Morbillivirus group, have caused disease outbreaks in several unusual species. The first of these was a distemper-like disease that occurred among Baikal seals Phoca sibirica in Siberia in 1987, and then in harbour seals Phoca vitulina in Europe in 1988. These outbreaks were followed by very widespread evidence of infection with morbilliviruses among sea mammals throughout the world. The virus causing mortality among seals in most areas has now been identified as Phocid distemper virus, a new virus similar to CDV; however, the virus that killed seals in Siberia is distinct from that in other seals and is considered to be CDV (1). Canine distemper virus has also been reported as a pathogen of giant pandas Ailuropoda melanoleuca in China (2). CDV was reported as the cause of abnormal behaviour in collared peccaries in southern Arizona. (3). Recently, an outbreak of canine

distemper has affected 20-30% of African lions Panthera leo in the Serengeti region of Tanzania (4). The initial signs in the lions were of nervous system involvement. Gross and microscopic findings in the lions were reported to be non-specific except for inclusion bodies in bile duct and epididymal epithelium. (1) Heide-Jorgensen et al. 1992, Diseases of Aquatic Organism 13:37-62. (2) Mainka et al. 1992, Journal of Wildlife Diseases 30:86-89. (3) Noon et al. 1992. Proceedings , Wildlife Disease Assoc. 41st Annual Meeting, (4). Information provided by M. Woodford, IUCN/SSC, Washington, D.C.

Hantavirus Pulmonary Syndrome in British Columbia

In June 1994, three cases of Hantavirus Pulmonary Syndrome (HPS) were reported in British Columbia. These are the first reported cases of this infection in Canada. A previously unknown hantavirus, currently known as the Muerto Canyon virus, has been associated with this illness. As of June, 1994, 83 cases of HPS had been diagnosed in North America. HPS is a recently described severe respiratory disease. Typically, patients with HPS experience acute "flu-like" symptoms that rapidly progress to severe and often fatal pulmonary edema and hypotension. To date, the proportion of infected persons who die (case fatality rate) of HPS has approached 60%. Prior to the initial outbreak of HPS in the southwestern United States in May 1993, hantaviruses in North America had not been associated with disease in humans.

Rodents, particularly the deer mouse (Peromyscus maniculatus), are primary reservoir for the Muerto Canyon virus. Deer mice are widespread in Canada and the United States and preliminary investigations suggest that the distribution of the Muerto Canyon virus parallels that of the deer mouse. To date, there is no evidence to suggest that infected animals show clinical signs nor is there evidence that domestic pets can be infected by the Muerto Canyon Virus. Pet ownership does not appear to put people at increased risk of developing the disease. Transmission to people is thought to occur by inhalation of aerosolized virus from rodents' saliva, urine or feces. Transmission by ingestion of food or water contaminated by rodents' saliva or excretions has not been eliminated however. To date, person-to-person transmission has not been documented.

All three affected people in B.C. lived and worked in the south central portion of the province in bunchgrass biogeographic zones. Each of the patient had potential occupational or "at home" exposure to rodents. Both the home and workplace of two patients were heavily infested with mice. Of particular concern to local wildlife workers is the occurrence of a case in a wildlife ecologist involved in rodent population studies.

A principal question to be addressed in future investigations is "Is the natural history of H.P.S. in B.C. the same as has been described in the United States?" Initially, the public health response to H.P.S. in B.C. will concentrate on improving disease surveillance and case finding, evaluating potential reservoirs for the virus, and identifying and educating potential risk-groups. To meet these objectives, education programs targeted at public

health officials and private physicians will provide detailed information regarding the diagnostic criteria, sample collection and submission, and the surveillance case definition for HPS. The dissemination of such information throughout the province is intended to improve identification and reporting of cases. Increasing physicians awareness of HPS will probably increase the number of potential and confirmed cases reported in B. C.

A sero-survey of rodents in B.C. was initiated in July, 1994. Areas sampled include the residence and work places of the affected patients as well as other sites where rodent studies are already underway. The purpose of this survey is to assess the distribution of rodents exposed to Muerto Canyon virus in the southern interior, paying particular attention to deer mice. Once the primary animal reservoir in B.C. has been identified, a more extensive survey will be undertaken to determine the geographic distribution of the Muerto Canyon virus in the province.

The identification and education of specific high risk groups is an important component of the initial response to this disease in B.C.. People whose occupational activities bring them into contact with rodents, such as wildlife biologists, pest control officers, and laboratory workers, are potentially at risk for infection. Because of the high case fatality rate of this disease and the unquantified risk of infection in B. C., public announcements were made via mass media sources directed at persons whose domestic or leisure activities expose them to rodents.

People involved with wildlife may be approached by the public for advice regarding hantaviruses. People should be discouraged from keeping wild rodents as pets. Deer mice, white footed mice and chipmunks can be infected by the Muerto Canyon Virus. People should also be advised to carefully dispose of rodents caught in traps or killed by their pets. Rubber or plastic gloves should be used to handle carcasses. Dead rodents should be place in a plastic bag with household disinfectant before burning or burying the body and bag.

The occurrence of HPS in B.C. should remind veterinarians and wildlife workers to take proper precautions when handling domestic and wild species capable of harbouring zoonotic diseases. Specific precautions should be taken when handling wild rodents, particularly deer mice. These include rubber or plastic gloves, appropriate respiratory protection, protective eye gear, and disposable or washable coveralls/lab coats. People should also consider the use of such protective wear if they are working in areas with heavy rodent infestations.

Interim recommendations for reducing the risk of hantavirus infection concentrate on reducing the exposure of people to rodents or rodent excrement by 1) removing rodents from homes, 2) preventing the entry of rodents into homes, 3) cleaning areas contaminated by rodents, and 4) avoiding contact with rodents when in rural environments or wilderness. Craig Stephen DVM - Epidemiology Researcher, Department of Health Care and Epidemiology,University of British Columbia; and Communicable Disease Epidemiology Section, British Columbia Centre for Disease Control

Disease Updates

Atlantic Region

Avian cholera and predation in nesting common eiders in New Brunswick

In mid-June 1994, heavy mortality was observed in adult female common eiders at a nesting colony on Hardwood Island, an island located in the Bay of Fundy near St. Andrews, New Brunswick. The estimated mortality during this time was 35 birds, roughly 50% of the females in the colony. Although predation was assumed to account for most of the mortality, a few dead eiders had no external injuries. Two such birds submitted to the New Brunswick Provincial Veterinary Laboratory had many tiny focal areas of necrosis in the liver. A moderate to heavy growth of Pasteurella multocida, the bacteria causing avian cholera, was recovered from the samples of liver, spleen and lung from both birds. The *P. multocida* isolates were not serotyped.

A few weeks after the first submission, there was continued mortality on the island and two dead female eiders were submitted to the Canadian Cooperative Wildlife Health Centre, Atlantic Region. These birds were in excellent body condition and the only gross abnormality detected was skinning of the head and neck region with marked hemorrhage in the underlying subcutaneous tissues. Significant lesions were not identified microscopically and bacteriology revealed only common post mortem contaminants in liver, lung and intestinal tissues. Therefore, predation was suggested as the likely cause of death. A mustelid such as a mink was considered as the potential predator due to the concentration of wounds in the head and neck region.

P. multocida was not recovered from birds submitted to investigate similar deaths in the same eider colony in 1993 ; mortality was attributed solely to predation. Any future mortality problems at eider nesting colonies in the Bay of Fundy will be monitored to try to ascertain the respective roles of avian cholera and predation. (Contribution from Dr. J.P. Goltz, New Brunswick Provincial Veterinary Laboratory and Susan Bowes, New Brunswick Department of Natural Resources.)

Drowning in northern gannets

An undetermined number of dead northern gannets were found on the north shore of New Brunswick in late April. Approximately 30 dead gannets were found in western Prince Edward Island in late May. Several birds from both sites were examined. All were adults in good body condition. The only significant findings were pulmonary congestion and, in several birds, the presence of a large amount of clear fluid in the subcutaneous air pockets. These air pockets are normal anatomical features of northern gannets; they communicate with the air sacs and, as the bird prepares to dive, they are inflated to cushion its body when it strikes the water. All these birds were presumed to have drowned as a result of entanglement in fishing nets. There was much inshore fishing activity for herring at the time. This kind of mortality among adult gannets probably occurs regularly, but its impact on populations of this species seems poorly documented.

(Contribution from Neil Burgess and Nev Garrity, Canadian Wildlife Service, Sackville, New Brunswick, and Ross Bernard, PEI Fish & Wildlife Division.)

Fetal mummification in beaver

The uterus of an adult female beaver in good body condition, trapped on Prince Edward Island in fall 1993, contained a full-term fetus that was very dry and whose extremities had partly disintegrated. No other lesion was found in this animal. In late fall 1988, another female beaver, also trapped on Prince Edward Island, had been submitted because of her poor body condition. Her uterus was attached to adjacent organs by a moderate amount of scar tissue and contained two full-term fetuses embedded in purulent material; both fetuses were intact, except for the head of one , which had disintegrated. In neither case could the primary cause of the problem be determined. Both may represent instances of fetal mummification or of failure to expel all the fetuses at the time of birth. In both cases, the reproductive life of the animal would likely have been ended.

Québec Region

Prevalence of oral papilloma in White suckers

Fish have been proposed as sentinel organisms for water pollution and the oral papillomas described in white suckers (Catastomus commersoni) have been specifically mentioned as possible biomarkers of environmental contamination. There is a strong correlation between areas of high pollution in the Great Lakes and high prevalence of this neoplasm. With this in mind we wanted to compare the prevalence of papillomas at two sites in the St. Lawrence River differing in their contamination by industrial pollutants. During the summer of 1994, white suckers were collected from two areas on the St-Lawrence river, Québec: one adjacent to Québec City, the other in Rivière des Prairies (between Montréal and Laval). Rivière des Prairies is a heavily polluted river draining a very large urban area. Québec City is much smaller than Montréal and less industrialized, with, consequently, less contamination of the river sediments. The white sucker is a bottom feeding fish and is therefore in extensive contact with any pollutant present in the river sediments. In our survey, 176 white suckers were caught from Rivière des Prairies with fyke nets over a period of one week and 56.3% were found to be affected by oral papillomas. In the Quebec City region, 212 fish were caught over the summer (May through August) and 10.8% had oral papillomas. This large difference in prevalences is similar to the results reported from the Great Lakes. The prevalence in Rivière des Prairies is similar to that reported for parts of heavily contaminated areas such as Hamilton harbour, while that seen for Québec City resembles the background prevalence of slightly contaminated Great Lake areas. These results lead us to believe that the same mechanisms of tumour induction which have been proposed for the Great Lakes are also present in the St. Lawrence river.

Tyzzer diseases in muskrats

A male muskrat found dead on April 26, 1994 in the Parc Régional de Pointe aux Prairies (Island of Montreal) was submitted frozen to the Quebec regional center. Seven dead muskrats were found during 1993 and 1994 in the same area. The animal submitted by the park warden was slightly underweight and its liver was congested and riddled with many small, circular, yellowish dots of variable dimension. Microscopically these areas corresponded to variably-sized areas of necrosis surrounded by several layers of neutrophils. A Warthin-Starry stain permitted the visualization of a few clumps of large, elongated bacilli in the cytoplasm of several hepatocytes on the edge of the necrotic foci. The morphology of these organisms is compatible with that of Clostridium piliforme ("Bacillus piliformis"). From these lesions a diagnosis of Tyzzer's disease was made.

This disease, which is not transmissible to man, is caused by a bacteria (Clostridium piliforme). Epidemics have been reported in muskrats from other regions of North America. Clostridium piliforme can be present in the intestine of muskrats without causing any signs of illness and the carrier animals liberate the spores into the environment through their feces. The spores stay infectious for a long time in mud or in the muskrat shelters and these animals infect themselves by ingesting the spores. The disease manifests itself when the animals are stressed by malnutrition, overpopulation, drought, frost or when the animals visit highly contaminated areas and ingest large numbers of spores. There are no known effective control measures for this disease in wild animals. Given this information, we suspect that the muskrats in the Parc Régional de Pointe aux Prairies are carriers of this disease and that they became ill after being exposed to an unidentified stress.

Hepatic carcinoma in an Atlantic tomcod

During last winter, livers of Atlantic tomcod (Microgadus tomcod) caught in the St. Anne river, a tributary of the St. Lawrence river, were examined for evidence of neoplastic changes. Out of 54 Atlantic tomcod livers examined, only one tumour (hepatic carcinoma) was found. This tumour, which was barely visible upon macroscopic examination, was slightly darker and more friable than the surrounding tissue. This neoplasm had well-defined borders, was unencapsulated and contrasted sharply with the adjacent parenchyma. The neoplastic cells of this mass were markedly pleomorphic, closely packed and separated by a thin connective tissue stroma. A few mitotic figures were present.

The prevalence of hepatic tumours in the St. Lawrence river Atlantic tomcod is much lower than that reported in the same species in the Hudson River (New Jersey). Different authors have observed that between 26% and 86% of Atlantic tomcods from the Hudson river were affected by hepatic adenomas or carcinomas. A cause and effect relationship between these neoplasms and contamination by carcinogenic chemicals has been proposed. If such a relation exists, the St. Lawrence river population of Atlantic tomcod would appear to be less exposed to such chemicals than the Hudson river population.

Intestinal adenocarcinoma in a beluga whale

A male adult beluga whale was found dead in Baie des Sable on the St. Lawrence river on May 28th ,1994. Upon examination of the intestines, a constriction was noted approximately 7.5 m from the stomachs. The normal diameter of the intestine (6 cm) was decreased to 1 cm at the constriction site. In this segment, the intestinal wall, normally 0.5 cm thick, was 3 cm thick. The thickened wall was homogeneously white and very firm. The proximal intestinal segment was moderately dilated. The intestinal wall thickening consisted of small, randomly-distributed, poorly-formed tubules and acini lined by a simple cuboidal to low columnar well-differentiated epithelium. These glandular structures were separated by an abundant fibrous stroma. Accordingly, this neoplasm was designated as a scirrhous annular stenosing intestinal adenocarcinoma (malignant tumor of the intestine).

Over the last eleven years, four such cases have been seen in beluga whales by our group. This type of cancer is very rare in other animal species and raises the question of a possible predisposition of this beluga population to this cancer caused by exposure to chemical carcinogens, immunosuppression or genetic susceptibility. Dr. Daniel Martineau and Dr. Stéphane Lair - CCWHC Quebec Region

Ontario Region

Botulism in Ring-billed Gulls

Staff from the Metropolitan Toronto Conservation Authority submitted carcasses and sick birds from the Leslie St. spit on Toronto's waterfront. There are many thousands of nesting birds on this site. The majority of the birds submitted for examination were ring-billed gulls, but herring gulls and Canada geese were also affected. Sick birds were weak and showed evidence of hindlimb paresis or paralysis. Severely affected birds had difficulty holding the head erect. A total of 12 birds received complete post-mortem examination. Botulism, due to ingestion of toxin produced by the bacterium Clostridium botulinum, Type C was confirmed in 5 adult ring-billed gulls and 1 adult herring gull. It was not confirmed in the juvenile ring-billed gulls nor the Canada geese, despite the fact that they showed similar clinical signs. The source of toxin was not identified. The month of June was extremely warm, which likely provided favourable conditions for proliferation of the bacteria.

Lead Poisoning in Loons

Eight loons submitted by the Ministry of Natural Resources and 4 by a member of the public have been examined this summer. In 5 of the 12 birds, lead fishing sinkers were found in the stomach. The majority of these birds had lesions compatible with lead intoxication: emaciation, esophageal dilation and impaction, and fissuring and bile staining of the mucosa of the stomach. Tissue levels of lead and mercury were measured

by the Canadian Wildlife Service. Levels in the kidneys of affected birds ranged from 27.60 to 480.00 ppm dry weight. Liver levels ranged from 17.40 to 95.10 ppm dw.

The occurrence of lead sinker ingestion in such a high proportion of birds examined is in contrast to previous results in this laboratory, in which only 3 of 27 loons examined harboured obvious sources of lead or had elevated levels of lead in tissues. The number of cases is likely insufficient to determine whether this reflects geographic differences in fishing activity within loon habitat or whether it represents a changing pattern over time. The effects of lead fishing sinkers on loons and other fish-eating birds is likely to become a more controversial issue as data of this sort accumulate.

Miscellaneous

Parvovirus enteritis (feline panleukopenia virus infection) continues to be a significant cause of mortality in raccoons, particularly juveniles, in some wildlife rehabilitation centres. Infection with canine distemper virus continues to be diagnosed as a cause of neurologic disease in raccoons from a variety of locations in the province. In recent months, several raccoons have been examined at the request of inspectors from various humane societies as part of cruelty investigations. Recent increase in media attention to raccoon rabies may be raising public concerns about raccoons in urban areas. Alternatively, it may only be a manifestation of the inevitable conflicts between raccoons and urban householders. Severe destructive encephalitis due to migrating ascarid larvae (presumed to be Baylisascaris procyonis) has been seen in several species of rodents, including groundhogs, grey squirrels and a porcupine. A skunk from an urban area had lesions of widespread soft tissue mineralization without evidence of chronic renal disease. These lesions are compatible with intoxication with a Vitamin D analogue rodenticide. Toxicology results are pending. Tularemia was diagnosed in a beaver from eastern Ontario. Previous mortalities were observed in this vicinity, but no estimate of the total number of animals that may have been affected was available.

Northern and Western Region

Tiger salamander die-off

On June 24th over 100 tiger salamander larvae were found dead in a dugout near Suffield, Alberta by Canadian Wildlife Service personnel. Inspection of carcasses revealed small focal areas of hemorrhage on the skin and in many of the internal organs. The bacteria Aeromonas hydrophila and Flavobacterium sp. were consistently isolated in large numbers from various organs. These larvae appear to have died of a bacterial septicemia, a condition commonly referred to as red-leg disease. Bacteria responsible for this condition, such as Aeromonas hydrophila, can frequently be isolated from water samples and healthy individuals in the population. Red-leg is thought to be precipitated by environmental stressors such as overcrowding and poor water quality, but this disease as well as all other causes of mortality in free-living amphibians are poorly understood.

Given the concern over declining amphibian populations in many areas, every effort should be made to obtain an accurate diagnosis in die-offs such as this.

Botulism outbreak in Alberta

In August 1994, Alberta experienced its worst waterfowl disease die off on record. The combined toxins associated with avian botulism and focal blue-green algae blooms resulted in the mortality of an estimated 70-80,000 waterfowl and shorebirds on Pakowki Lake. Over 25,000 carcasses were collected during a cooperative cleanup operation involving staff and equipment from Alberta Fish and Wildlife Services, Environment Canada, and Ducks Unlimited Canada. Additional logistical support was provided by Alberta Agriculture, the County of Forty Mile, and Agriculture Canada. Species collected were primarily green-winged teal, gadwall, northern shoveler, mallard, and lesser yellowlegs. A few raptors and songbirds also were collected.

Pakowki Lake, in the extreme southeast corner of the province, forms in a shallow dish of alkali substrate in which a small amount of water results in a large surface area. Abundant rain in 1993 and in the spring of 1994 filled the lake and provided excellent habitat for a wide range of species, particularly shorebirds. In addition, waterfowl production on the prairies has been high this year.

Neither botulism nor blue-green algae poisoning are unusual events on many prairie lakes. The unusual aspects of this die off are the numbers of birds involved, and the speed and force with which the cleanup operations were implemented. Without the cooperative nature of the cleanup, as outlined in the Alberta Waterfowl Disease Contingency Plan, the 125-150,000 birds using the lake and the legions of migrating birds soon to arrive, would have been at considerable risk. M.J. Pybus, Wildlife Disease Research Biologist, Alberta Fish & Wildlife Services.

Waterbird mortality in Saskatchewan

Old Wives lake in south central Saskatchewan, near Moose Jaw, was the site of a large waterbird dieoff with known mortality approaching 16,000. Carcasses were discovered September 6th by Saskatchewan Wetlands Conservation Corporation biologists but the dieoff likely occurred late August based on the level of decomposition. An investigation by Canadian Wildlife Service and Canadian Cooperative Wildlife Health Centre personnel revealed no recent mortality or clinically ill birds. Dead birds were predominately ducks (66% pintails and 18% green-winged teal) although some Franklin gulls, shorebirds and 210 white pelicans were identified. A cause for the die-off was not identified due to late detection of the outbreak. Botulism is suspected based on the history of this marsh and recent weather conditions. Old Wives Lake is a shallow, alkali waterbody similar to Pakowki Lake. Gary Bogdan, CWS Saskatoon and Trent Bollinger CCWHC

Carbofuran poisoning in Saskatchewan

Two incidents of carbofuran poisoning were detected during a small scale field monitoring exercise undertaken by the Canadian Wildlife Service and a third was independently reported by a member of the public. The poisonings occurred in May and involved 4 different species of sparrows, 15 American goldfinch, a shrew, and a vole. Three, 4, and 15 carcasses were found at each of the 3 sites, respectively. Carbofuran granules used at seeding were implicated in all three incidents.

Results of the monitoring exercise suggest the following: 1) corncob granules used to incorporate carbofuran are attractive to birds and small mammals and mortality may be widespread; 2) finding carcasses in agricultural fields is usually a significant event, every bird found in the course of the monitoring exercise had been killed by carbofuran; 3) secondary poisoning of predators and scavengers (eagles, red-tailed hawks, etc.) is possible given the high residue levels found in crop contents. Pierre Mineau, National Wildlife Research Centre, CWS. Trent Bollinger, CCWHC.

Copyright © 1999/2001
CCWHC

Online @ http://wildlife1.usask.ca/newsletters/newsletter2-3.htm