University of Nebraska - Lincoln
DigitalCommons@University of Nebraska - Lincoln

Virology Papers | Virology, Nebraska Center for

9-1-2005

Extraneural Prion Neuroinvasion without Lymphoreticular System Infection

Jason C. Bartz
Creighton University, Omaha, Nebraska, jbartz@creighton.edu

Crista DeJoia
Montana State University, Bozeman, Montana

Tammy Tucker
Montana State University, Bozeman, Montana

Anthony E. Kincaid
Creighton University, Omaha, Nebraska

Richard A. Bessen
Montana State University, Bozeman, Montana

Follow this and additional works at: http://digitalcommons.unl.edu/virologypub

Part of the Virology Commons

Bartz, Jason C.; DeJoia, Crista; Tucker, Tammy; Kincaid, Anthony E.; and Bessen, Richard A., "Extraneural Prion Neuroinvasion without Lymphoreticular System Infection" (2005). *Virology Papers.* Paper 37.
http://digitalcommons.unl.edu/virologypub/37

This Article is brought to you for free and open access by the Virology, Nebraska Center for at DigitalCommons@University of Nebraska - Lincoln. It has been accepted for inclusion in Virology Papers by an authorized administrator of DigitalCommons@University of Nebraska - Lincoln.

JOURNAL OF VIROLOGY, Sept. 2005, p. 11858–11863 Vol. 79, No. 18
0022-538X/05/$08.00+0 doi:10.1128/JVI.79.18.11858–11863.2005
Copyright © 2005, American Society for Microbiology. All Rights Reserved.

Extraneural Prion Neuroinvasion without Lymphoreticular System Infection

Jason C. Bartz,[1] Crista DeJoia,[2] Tammy Tucker,[2] Anthony E. Kincaid,[3] and Richard A. Bessen[2]*

Department of Medical Microbiology & Immunology[1] and Department of Physical Therapy,[3] Creighton University, Omaha, Nebraska 68178, and Department of Veterinary Molecular Biology, Montana State University, Bozeman, Montana 59717[2]

Received 23 March 2005/Accepted 22 June 2005

While prion infection of the lymphoreticular system (LRS) is necessary for neuroinvasion in many prion diseases, in bovine spongiform encephalopathy and atypical cases of sheep scrapie there is evidence to challenge that LRS infection is required for neuroinvasion. Here we investigated the role of prion infection of LRS tissues in neuroinvasion following extraneural inoculation with the HY and DY strains of the transmissible mink encephalopathy (TME) agent. DY TME agent infectivity was not detected in spleen or lymph nodes following intraperitoneal inoculation and clinical disease was not observed following inoculation into the peritoneum or lymph nodes, or after oral ingestion. In contrast, inoculation of the HY TME agent by each of these peripheral routes resulted in replication in the spleen and lymph nodes and induced clinical disease. To clarify the role of the LRS in neuroinvasion, the HY and DY TME agents were also inoculated into the tongue because it is densely innervated and lesions on the tongue, which are common in ruminants, increase the susceptibility of hamsters to experimental prion disease. Following intratongue inoculation, the DY TME agent caused prion disease and was detected in both the tongue and brainstem nuclei that innervate the tongue, but the prion protein PrP^{Sc} was not detected in the spleen or lymph nodes. These findings indicate that the DY TME agent can spread from the tongue to the brain along cranial nerves and neuroinvasion does not require agent replication in the LRS. These studies provide support for prion neuroinvasion from highly innervated peripheral tissues in the absence of LRS infection in natural prion diseases of livestock.

In scrapie infection of sheep and chronic wasting disease infection of cervids, prion agent infection and replication in the gut-associated lymphoreticular system (LRS) precede entry into the nervous system following oral prion exposure (1, 15, 29, 35). After infection of the LRS, the prion agent enters peripheral nerves and retrogradely spreads to the central nervous system, where it can replicate to high levels. The scrapie agent also retrogradely spreads from the enteric nervous system to the dorsal motor nucleus of the vagus in the brainstem via the vagus nerve (21, 28, 36). These modes of neuroinvasion are postulated to be dependent on prior agent amplification in the LRS. This is supported by studies using mice that are not susceptible to prion infection via extraneural routes of inoculation as a result of a permanent or transient loss of functional germinal centers in lymphoid follicles (17–20, 22).

However, in bovine spongiform encephalopathy (BSE)-infected cattle and atypical scrapie, the role of the LRS in prion neuroinvasion is less clear, and perhaps not essential. In natural cases of BSE, prion infectivity has not been detected in lymph nodes or spleen, and the disease-specific isoform of the prion protein PrP^{Sc} was not found in the distal ileum (31). Following experimental oral exposure of calves to the BSE agent, BSE infectivity was found in the distal ileum and in a single sample of tonsil but not in the spleen or lymph nodes (13, 30, 37, 38). The paucity of the BSE agent in the LRS suggests that there may be alternative routes of prion neuroinvasion that could involve direct infection of the nervous system.

In atypical cases of scrapie the distribution of the scrapie agent in the LRS and brain is different from that found in classical scrapie. PrP^{Sc} has not been found in lymph nodes from sheep with atypical scrapie (6) and there is a notable absence of PrP^{Sc} immunostaining in the dorsal motor nucleus of the vagus in the brainstem (6, 10, 25), which suggests that scrapie agent neuroinvasion does not occur via the vagus nerve. These findings raise the possibility that scrapie infection was not established via agent entry into the gut and, importantly, that infection of the LRS is not necessary for prion neuroinvasion in a subset of prion diseases.

To investigate the role of LRS infection in prion neuroinvasion, we used an experimental model of transmissible mink encephalopathy (TME) in hamsters. We tested the hypothesis that LRS-independent neuroinvasion could occur following inoculation of a densely innervated peripheral tissue, such as the tongue. Previous studies have demonstrated that intratongue inoculation of the HY strain of the TME agent resulted in rapid disease onset consistent with TME agent neuroinvasion via the hypoglossal nerve (4). We examined the ability of the DY TME agent, which does not replicate in the spleen (3), to establish TME infection following several extraneural routes of inoculation. Following intraperitoneal, intra-lymph node, or oral exposure to the DY TME agent, hamsters did not develop clinical disease and neither DY TME agent infectivity nor PrP^{Sc} was detected in the LRS. In contrast, intratongue inoculation of hamsters with the DY TME agent resulted in prion

* Corresponding author. Mailing address: Department of Veterinary Molecular Biology, P. O. Box 173610, Montana State University, Bozeman, MT 59717. Phone: (406) 994-1563. Fax: (406) 994-4303. E-mail: rbessen@montana.edu.

disease in the absence of LRS infection. The initial sites of DY TME agent deposition in the brainstem following intratongue inoculation were consistent with prion neuroinvasion via the tongue-associated cranial nerves. This study suggests that neuroinvasion from highly innervated peripheral tissues does not require LRS infection and has clinical implications for a subset of prion diseases in livestock in which prion replication in the LRS is either greatly restricted or not apparent.

MATERIALS AND METHODS

Animal inoculations and tissue collection. All procedures involving animals were approved by the Institutional Animal Care and Use Committee and comply with the Guide for the Care and Use of Laboratory Animals (24). Weanling (4 to 5 weeks old) outbred male Golden Syrian hamsters (Harlan Sprague Dawley, IN) were inoculated with a 1% (wt/vol) brain homogenate from an HY TME- or DY TME agent-infected hamster containing $10^{7.5}$ or $10^{5.4}$ median lethal doses per ml, respectively. Hamsters were inoculated by the intracerebral (25 μl), intraperitoneal (100 μl), or intratongue (20 μl) route. Animals were observed three times per week for the onset of neurological disease as previously described (8). Animals were sacrificed by CO_2 asphyxiation and tissues were removed and frozen for Western blot analysis, or the animals were perfused with fixative and the brainstem was prepared for PrP^{Sc} immunohistochemistry.

Hamster bioassay for DY TME agent infectivity. Tissues (i.e., lymph nodes, spleen, and brain) were aseptically collected from hamsters at various time points following mock inoculation or intraperitoneal (i.p.) inoculation with the DY TME agent. The tissues were minced with disposable razor blades and sterile saline was added to a final volume of 250 μl. The tissue was homogenized using a 26-gauge needle prior to sonication in a cup horn sonicator (Fisher Scientific, Atlanta, GA). Tissue homogenates were inoculated intracerebrally into Syrian hamsters and the time to onset of clinical symptoms was recorded.

Tissue preparation and Western blot of PrP^{Sc}. For PrP^{Sc} analysis of brain from clinically ill hamsters, a 5% (wt/vol) homogenate in Dulbecco's phosphate-buffered saline without Ca^{2+} or Mg^{2+} (Mediatech, Herndon, VA) was digested with 4 units per ml of proteinase K (Roche Diagnostics Corporation, Indianapolis, IN). Homogenates were incubated at 37°C for 1 hour with constant agitation followed by the addition of phenylmethylsulfonyl fluoride to a concentration of 5 mM. Proteinase K-digested brain homogenates (0.25-mg equivalents) were analyzed for PrP^{Sc} content by sodium dodecyl sulfate (SDS)-polyacrylamide gel electrophoresis (PAGE) and Western blot as described below.

The spleen and lymph nodes were homogenized in 10 mM Tris-HCl [pH 7.5] containing 5 mM $MgCl_2$ to produce a 20% (wt/vol) tissue homogenate. Tissue homogenates were incubated with 100 units per ml of Benzonase nuclease (Novagen, Inc., Madison, WI) at 37°C for 1 hour with constant agitation. An equal volume of buffer was added to make a 10% (wt/vol) tissue homogenate containing buffer A (10% [wt/vol] *N*-lauroylsarcosine in 10 mM Tris-HCl [pH 7.5], 100 mM NaCl, 1 mM EDTA, and 1 mM dithiothreitol). Tongues taken from all animals and the brains from hamsters that did not develop clinical symptoms were directly homogenized in buffer A.

Enrichment for PrP^{Sc} from brain, tongue, spleen, and lymph nodes was performed as previously described (3–5). SDS-PAGE and Western blot were performed as previously described using monoclonal anti-PrP antibody 3F4 hybridoma supernatant at a 1:10,000 dilution (23) (gift of V. Lawson, National Institute of Allergy and Infectious Diseases, Rocky Mountain Laboratories, Hamilton, MT) (16).

Immunohistochemistry. Immunostaining for PrP^{Sc} in brainstem was performed as previously described (4, 23). Briefly, animals were intracardially perfused with paraformaldehyde-lysine-periodate fixative followed by postfixation in paraformaldehyde-lysine-periodate fixative for 5 to 7 h. Paraffin-embedded tissue sections (5 μm) were subjected to antigen retrieval by treatment with formic acid for 20 min, followed by a streptavidin-biotin blocking step. PrP^{Sc} was detected by successive incubation with monoclonal 3F4 hybridoma supernatant, horse anti-mouse immunoglobulin G biotin conjugate (Vector Laboratories, Burlingame, CA), and streptavidin conjugated to horseradish peroxidase (Biosource, San Diego, CA). Visualization of PrP^{Sc} staining was performed using 3-amino-9-ethylcarbazole (0.5 mg per ml) in 100 mM sodium acetate (pH 5.0) and 0.01% H_2O_2. Tissue was counterstained with hematoxylin. A minimum of three animals per group and 15 tissue sections per animal were examined with a Nikon E600 microscope for each antibody staining procedure.

TABLE 1. Incubation period of HY TME and DY TME agents in hamsters following neural and extraneural inoculation

Inoculation route	Mean time to onset of clinical signs (days) ± SEM	
	HY TME	DY TME
Cerebrum	60 ± 1 (5/5)[a]	168 ± 5 (5/5)
Sciatic nerve[b]	68 ± 2 (6/6)	210 ± 9 (5/6)
Tongue	79 ± 2 (6/6)	262 ± 7 (5/6)
Peritoneum	93 ± 19 (5/5)	>500 (0/5)
Oral	122 ± 3 (5/5)	>600 (0/5)
Submandibular lymph node	190 ± 20 (3/3)	>475[c] (0/3)

[a] Number affected/number inoculated.
[b] Reference 3.
[c] One intercurrent death at 477 days and two others clinically normal at >690 days postinoculation.

RESULTS

Pathogenicity of the HY and DY TME agents by neural and extraneural routes of inoculation. To investigate the role of the LRS in prion neuroinvasion, hamsters were initially inoculated into the peripheral or central nervous system by the intrasciatic nerve and intracerebral routes, respectively, with the HY and DY TME agents (Table 1). All neural inoculation groups were susceptible to prion disease, with the HY TME agent-inoculated groups having a shorter incubation period than the DY TME agent-inoculated hamsters, as reported previously (5, 7). The HY and DY TME agents were also inoculated into hamsters by several extraneural routes, including intraperitoneal (i.p.), intratongue, intra-lymph node, and per os. Animal groups inoculated with the HY TME agent all developed clinical disease, with the intratongue route (79 ± 2 days) having the shortest incubation period and the intralymph node route the longest incubation period (190 ± 20 days) (Table 1). However, inoculation of the DY TME agent by these peripheral routes only produced disease in the intratongue group at 262 ± 7 days postinoculation. At 475 to 600 days postinoculation, clinical signs of DY TME were not observed in the i.p., intra-lymph node, and per os groups (Table 1). These findings suggest that DY TME agent neuroinvasion is either delayed or absent following peripheral inoculation with the exception of the intratongue inoculation group.

Since prion agent infection or disease is typically observed following i.p. inoculation in rodent models of prion disease, we tested the hypothesis that DY TME agent neuroinvasion is blocked due to the inability of the DY TME agent to either replicate in the LRS or spread from the LRS to the peripheral nervous system. In a previous study DY TME agent infectivity was not found in the spleen, sympathetic chain, or brain following i.p. inoculation (3).

To investigate whether the lymph nodes are a potential site of DY TME agent replication, the medial iliac and mesenteric lymph nodes as well as the spleen were collected from hamsters at 60 and 120 days after i.p. inoculation with the DY TME agent. TME agent infectivity in these tissues was subsequently measured by hamster bioassay. Lymph node and spleen homogenates from one mock-infected and two DY TME agent-infected hamsters at each of the collection times postinoculation were intracerebrally inoculated into hamsters. At 400 days postinoculation none of the hamsters developed clinical symp-

TABLE 2. TME agent infectivity in tissues from hamsters intraperitoneally inoculated with the DY TME agent

Inoculation[a]	Time postinoculation (days)	Incubation period (days)		
		Spleen	Medial iliac LN	Mesenteric LN
Mock 1	60	>400 (0/4)[b]	>400 (0/4)	>400 (0/4)
DY TME 1	60	>400 (0/4)	>400 (0/4)	>400 (0/4)
DY TME 2	60	>400 (0/4)	>400 (0/4)	>400 (0/4)
Mock 2	120	>400 (0/4)	>400 (0/4)	>400 (0/4)
DY TME 3	120	>400 (0/4)	>400 (0/4)	>400 (0/4)
DY TME 4	120	>400 (0/4)	>400 (0/4)	>400 (0/4)

[a] Hamsters were intraperitoneally inoculated with $10^{4.4}$ median lethal doses of the DY TME agent or a normal brain homogenate (mock). The spleen and lymph nodes (LN) were collected from two mock-inoculated and four DY TME agent-inoculated hamsters at the indicated times postinoculation for animal bioassay.

[b] Number affected/number inoculated.

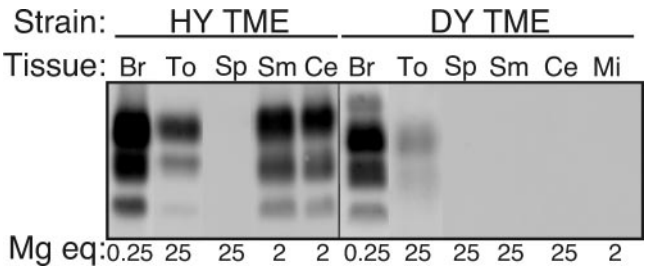

FIG. 2. Tissue distribution of PrP^{Sc} following intratongue inoculation of the HY TME and DY TME agents. Hamsters were inoculated in the tongue and sacrificed after the onset of clinical symptoms. The brain (Br), tongue (To), spleen (Sp), submandibular lymph node (Sm), cervical lymph node (Ce), and medial iliac lymph node (Mi) were collected and prepared for PrP^{Sc} analysis and Western blot as described for Fig. 1. Tissue amounts are indicated in milligram equivalents (Mg eq).

toms of disease (Table 2). A control hamster group was intracerebrally inoculated with a brain homogenate containing a low dose of the DY TME agent (e.g., $10^{2.2}$ median lethal doses) and they developed clinical disease at 204 ± 1 day postinfection. These findings indicate that the DY TME agent does not replicate in the lymph nodes or spleen during the first 120 days following i.p. inoculation. Therefore, we propose that prion neuroinvasion does not occur following peripheral inoculation as a result of the inability of the DY TME agent to establish infection in the LRS.

The accumulation of the HY and DY TME agents in the brain, LRS, and tongue of TME agent-infected hamsters at clinical disease was investigated by PrP^{Sc} Western blot in order to determine the sites of TME agent infection. Following intracerebral and i.p. inoculation of the HY TME agent, PrP^{Sc} was found in the brain, submandibular lymph node, and spleen of clinically ill hamsters (Fig. 1). For the DY TME agent, PrP^{Sc} was found in the brain following intracerebral inoculation but was not detected in the spleen or submandibular lymph nodes at the time of clinical disease. Following i.p. inoculation of the DY TME agent, PrP^{Sc} was not found in the brain, spleen, or

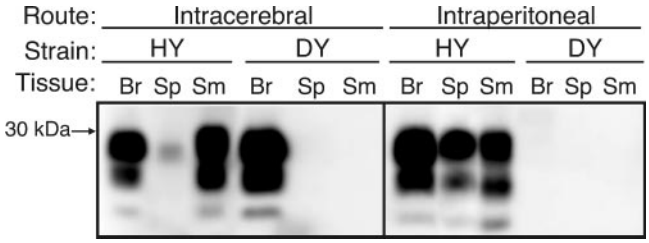

FIG. 1. Tissue distribution of PrP^{Sc} following inoculation of TME agents by neural and extraneural routes. Hamsters were inoculated with the HY TME or DY TME agent by either the intracerebral or intraperitoneal route. Hamsters were sacrificed after the onset of clinical disease and from clinically normal, aged DY TME agent-inoculated hamsters at greater than 500 days after intraperitoneal inoculation. The brain (Br), spleen (Sp), and submandibular lymph nodes (Sm) were collected for PrP^{Sc} analysis. Brain homogenates, containing 0.15 to 0.25 mg equivalents of tissue, and PrP^{Sc}-enriched preparations from the spleen and lymph nodes (25 mg equivalents) were prepared as described in the text and analyzed by SDS-PAGE and PrP Western blot. The positions of molecular mass markers are indicated to the left of the panel in kilodaltons.

submandibular lymph node in clinically normal hamsters at 500 days postinfection (Fig. 1), which was consistent with the absence of TME agent infectivity in lymph nodes or spleen (Table 2).

Following intratongue inoculation of the HY and DY TME agents, PrP^{Sc} was found in both the brain and tongue at clinical disease, but PrP^{Sc} was only detected in the lymph nodes from HY TME agent-inoculated hamsters (Fig. 2). DY PrP^{Sc} was absent from the spleen and the submandibular, cervical, and medial iliac lymph nodes from hamsters that developed clinical signs of DY TME following intratongue inoculation, even though up to 10-fold more lymph node tissue was analyzed compared to HY TME agent-infected hamsters. These findings indicate that DY PrP^{Sc} does not accumulate in the lymph nodes and spleen, and this result is in agreement with the bioassay data (Table 2), which indicate a lack of DY TME agent infectivity in these tissues. Based on these studies, we propose that prion neuroinvasion via the tongue does not require prior agent infection in the LRS.

PrP^{Sc} distribution in the nervous system following intratongue inoculation of the TME agent. The initial sites of PrP^{Sc} deposition in the central nervous system following intratongue inoculation of the HY and DY TME agents were investigated by PrP^{Sc} immunohistochemistry in order to determine the primary route of TME agent neuroinvasion. As previously described, intratongue inoculation of the HY TME agent resulted in detection of PrP^{Sc} in the hypoglossal nucleus at 2 weeks postinfection (4). In the current study there was a progressive increase in the amount of HY PrP^{Sc} deposition in the hypoglossal nucleus following intratongue inoculation of the HY TME agent, and PrP^{Sc} was found within the cytoplasm of the hypoglossal motor neurons early after brainstem infection (Fig. 3B). As TME agent infection progressed, the cytoplasm became progressively filled with large PrP^{Sc} aggregates. At later time points postinfection, PrP^{Sc} deposits were present in the nucleus of the solitary tract and portions of the reticular formation, as previously described (4). Neurons in these locations are known to synapse with the motor neurons in the hypoglossal nucleus, and infection of these second-order neurons is consistent with trans-synaptic spread of the HY TME agent.

Following intratongue inoculation of the DY TME agent,

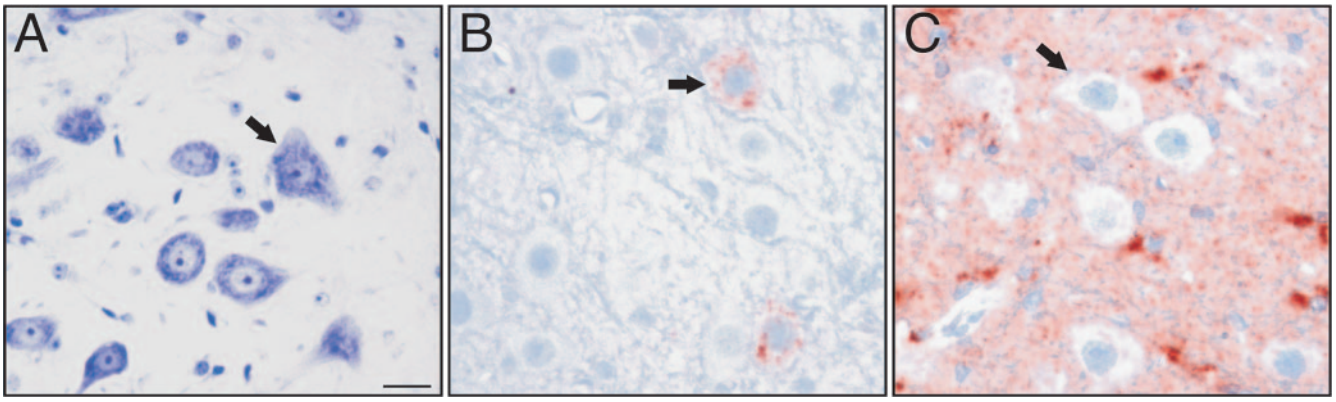

FIG. 3. PrP^{Sc} deposition in the hypoglossal nucleus of hamsters following intratongue inoculation of the HY TME and DY TME agents. Hamsters were inoculated by the intratongue route with the HY TME agent (B) or DY TME agent (C). Brain was collected from HY TME- and DY TME agent-infected hamsters at 4 weeks (i.e., 35% of the HY TME agent incubation period had elapsed) and 23 weeks (i.e., 60% of the DY TME agent incubation period had elapsed) postinfection, respectively, and prepared for immunohistochemistry as described in Materials and Methods. PrP^{Sc} immunohistochemistry (red punctate signal) revealed staining in the hypoglossal nucleus that included intrasomata PrP^{Sc} deposits in motor neurons in HY TME agent infection and neuropil PrP^{Sc} deposits with a paucity of intrasomata staining in DY TME agent infection. Tissue was counterstained with hematoxylin (B and C). Nissl stain (A) of the hypoglossal nucleus from a mock-infected hamster illustrates somata of motor neurons. Arrowheads indicate hypoglossal motor neurons. Bar, 20 μm.

PrP^{Sc} was first detected in the hypoglossal nucleus at 12 weeks postinfection; there was also evidence for PrP^{Sc} deposition in the nucleus of the solitary tract and reticular formation at this time point. This initial distribution of DY PrP^{Sc} in the brainstem following intratongue inoculation was similar to that for the HY TME agent except that there was no obvious delay in PrP^{Sc} deposition in the nucleus of the solitary tract after deposition in the hypoglossal nucleus. PrP^{Sc} deposits were not found in the brainstem at 8 weeks following intratongue inoculation of the DY TME agent; time points between 8 and 12 weeks were not examined.

The most striking difference in the hypoglossal nucleus between the HY and DY TME agent strains was the pattern of immunoreactivity. In both early and late DY TME agent infection of the hypoglossal nucleus, PrP^{Sc} deposition was primarily found in the neuropil or associated with glia, but PrP^{Sc} deposits were infrequently observed in the cytoplasm of motor neurons (Fig. 3C). These deposits had a punctate staining pattern, but large PrP^{Sc} aggregates in the somata were not found in DY TME agent infection, unlike HY TME agent infection. PrP^{Sc} was not found in the spinal cord of either the HY TME or DY TME agent-infected hamsters at the time of initial PrP^{Sc} detection in the brainstem for each TME agent (data not shown). This PrP^{Sc} distribution in the nervous system was consistent with retrograde spread of the HY TME and DY TME agents along the axons of the hypoglossal nerve to the hypoglossal nucleus. In addition, for the DY TME agent, we cannot exclude a role for spread along the axons of the chorda tympani branch of the facial nerve or the glossopharyngeal nerve, which both project from the tongue to the nucleus of the solitary tract in the brainstem.

DISCUSSION

In this report we investigated the role of the LRS in prion neuroinvasion in order to address a subset of prion diseases of livestock where infection of the LRS either is restricted or does not appear to be essential for neuroinvasion. We tested the hypothesis that prion neuroinvasion by the DY TME agent is independent of LRS infection following inoculation by several extraneural routes, including the tongue. Intraperitoneal inoculation of the DY TME agent did not result in (i) TME agent infectivity in lymph nodes or spleen, (ii) PrP^{Sc} deposition in lymph nodes, spleen or brain, and (iii) clinical disease. In a prior study, DY TME agent infectivity was not detected in the spleen, sympathetic chain, or brain of hamsters at 80 to 405 days postinoculation of the DY TME agent by the i.p. route (3). Based on these findings, we conclude that the DY TME agent does not replicate in the LRS.

To test whether the lack of DY TME agent replication in the LRS was due to an inability of this agent to be transported to the LRS, hamsters were directly inoculated in the submandibular lymph node. These animals did not develop clinical TME after 400 days postinoculation. The DY TME agent is the only reported prion agent that fails to replicate in the LRS following intraspecies inoculation of an immunocompetent host. Although subclinical prion infection has been described in rodents following extraneural inoculation, PrP^{Sc} or infectivity is found in LRS tissues of these hosts. In mice the 87V scrapie agent can establish a subclinical infection for the life span of the host following i.p. inoculation, but scrapie infectivity was detected in the spleen within weeks of inoculation (9, 12). Other studies reported subclinical RML scrapie infection of mice following oral ingestion, but scrapie infectivity was found in lymph nodes and brain in these aged mice (32). These subclinical infections are distinct from extraneural inoculation with the DY TME agent, in which PrP^{Sc} or DY TME agent infectivity has not been found in LRS tissues. Based on our studies we conclude that the DY TME agent can be used to investigate the routes of prion neuroinvasion that are independent of prion agent replication in the LRS.

The pathogenicity of the DY TME agent following routes of exposure that are known to be dependent on agent replication in the LRS prior to neuroinvasion were compared to inocula-

tion in the tongue, a densely innervated peripheral tissue. The tongue was chosen as a site of inoculation for several reasons: (i) it is in direct contact with the prion agent during oral ingestion; (ii) lesions on the tongue increase the susceptibility of hamsters to HY TME agent infection when the agent is directly applied to the tongue (4); (iii) infections or lesions in the oral cavity and tongue are common in ruminant species; and (iv) prion infection of the tongue has been reported in the tongue of scrapie-infected sheep (2, 11) (R. A. Bessen, unpublished data). Hamsters were susceptible to DY TME disease following intratongue, intracerebral, and intra-sciatic nerve inoculation but not following i.p., intra-lymph node, or per os inoculation. In the intratongue, intracerebral, intra-sciatic nerve, and i.p inoculation groups, DY PrP^{Sc} was not found in lymph nodes or spleen and DY TME agent infectivity in the LRS, sympathetic chain, or brain was not detected following i.p. inoculation (3, 5).

It is possible that intratongue inoculation, unlike i.p. inoculation, of the DY TME agent could result in replication in the LRS. This outcome is unlikely since HY PrP^{Sc} was found in the LRS of hamsters following neural and extraneural inoculation (3–5) but there was no evidence for DY TME agent infection in the LRS following inoculation by similar routes. Based on the lack of DY TME agent infectivity and PrP^{Sc} in LRS tissues following i.p. inoculation and the absence of DY TME agent disease following several extraneural routes of inoculation, we conclude that neuroinvasion following intratongue inoculation of the DY TME agent is not dependent on prion agent replication in the LRS. This conclusion is consistent with a previous study using transgenic mice that express PrP^{C} under the control of the neuron-specific enolase promoter, in which these mice were susceptible to scrapie following extraneural prion agent inoculation (26).

DY TME agent neuroinvasion via the tongue is consistent with axonal transport along cranial nerves. Detection of PrP^{Sc} in the brainstem at 12 weeks postinfection following intratongue inoculation of the DY TME agent was at a time when DY TME agent infectivity was not detected in lymph nodes or spleen following i.p. inoculation. The initial sites of DY PrP^{Sc} deposition in the central nervous system following intratongue inoculation were the hypoglossal nucleus and nucleus of the solitary tract. This distribution is consistent with retrograde spread of the DY TME agent within the axons of the hypoglossal nerve to the hypoglossal nucleus, and the chorda tympani branch of the facial nerve and/or glossopharyngeal nerve to the nucleus of the solitary tract in the brainstem. In order to determine the principal route of DY TME agent neuroinvasion from the tongue, additional analysis between 8 and 12 weeks postinfection is necessary to determine the initial sites(s) of entry of the DY TME agent into the brainstem.

For the HY TME agent, following initial PrP^{Sc} deposition in the hypoglossal nucleus there was a longer delay before PrP^{Sc} appeared in the nucleus of the solitary tract compared to the DY TME agent, suggesting that the HY TME agent spread to the nucleus of the solitary tract via fibers that originate in the nucleus of the solitary tract and terminate on the hypoglossal motor neurons (4). This spread to the nucleus of the solitary tract across synapses is consistent with trans-synaptic spread of pseudorabies and rabies virus transneuronal tracers following intratongue inoculation (14, 33, 34).

Direct prion neuroinvasion from extraneural tissues has implications for BSE and atypical scrapie in which there appears to be a reduced role for the LRS in neuroinvasion. Our findings indicate that infection of peripheral tissues that are densely innervated, such as the tongue, can result in direct neuroinvasion via cranial nerves without LRS infection. The tongue is a unique tissue in that it receives dense sensory and motor innervation from four cranial nerves. In fact, the density of motor innervation of the tongue is much greater than the density of motor innervation of other muscle groups (27). Exposure of the tongue to the prion agent during oral ingestion makes it a potential site of agent entry and neuroinvasion, especially if lesions have disrupted the mucosal epithelium (4). Although there are no epidemiological data that indicate this is a common route of prion agent entry, the tongue is a highly innervated peripheral tissue that may be a relevant site of neuroinvasion for a subset of prion diseases of livestock in which evidence for LRS infection is lacking.

ACKNOWLEDGMENTS

This work was supported by Public Health Service grant R01 AI-055043 from the National Institute of Allergy and Infectious Diseases, by the National Research Initiative of the USDA Cooperative State Research, Education, and Extension Service, grant number 2002-35204-14259, and by NIH grant P20 RR-020185-01 from the National Center for Research Resources.

Special thanks go to Lisa Hughes for excellent technical assistance.

REFERENCES

1. **Andreoletti, O., P. Berthon, D. Marc, P. Sarradin, J. Grosclaude, L. van Keulen, F. Schelcher, J. M. Elsen, and F. Lantier.** 2000. Early accumulation of PrP(Sc) in gut-associated lymphoid and nervous tissues of susceptible sheep from a Romanov flock with natural scrapie. J. Gen. Virol. **81:**3115–3126.
2. **Andreoletti, O., S. Simon, C. Lacroux, N. Morel, G. Tabouret, A. Chabert, S. Lugan, F. Corbiere, P. Ferre, G. Foucras, H. Laude, F. Eychenne, J. Grassi, and F. Schelcher.** 2004. PrPSc accumulation in myocytes from sheep incubating natural scrapie. Nat. Med. **10:**591–593.
3. **Bartz, J. C., J. M. Aiken, and R. A. Bessen.** 2004. Delay in onset of prion disease for the HY strain of transmissible mink encephalopathy as a result of prior peripheral inoculation with the replication-deficient DY strain. J. Gen. Virol. **85:**265–273.
4. **Bartz, J. C., A. E. Kincaid, and R. A. Bessen.** 2003. Rapid prion neuroinvasion following tongue infection. J. Virol. **77:**583–591.
5. **Bartz, J. C., A. E. Kincaid, and R. A. Bessen.** 2002. Retrograde transport of transmissible mink encephalopathy within descending motor tracts. J. Virol. **76:**5759–5768.
6. **Benestad, S. L., P. Sarradin, B. Thu, J. Schonheit, M. A. Tranulis, and B. Bratberg.** 2003. Cases of scrapie with unusual features in Norway and designation of a new type, Nor98. Vet. Rec. **153:**202–208.
7. **Bessen, R. A., and R. F. Marsh.** 1994. Distinct PrP properties suggest the molecular basis of strain variation in transmissible mink encephalopathy. J. Virol. **68:**7859–7868.
8. **Bessen, R. A., and R. F. Marsh.** 1992. Identification of two biologically distinct strains of transmissible mink encephalopathy in hamsters. J. Gen. Virol. **73:**329–334.
9. **Bruce, M. E.** 1985. Agent replication dynamics in a long incubation period model of mouse scrapie. J. Gen. Virol. **66:**2517–2522.
10. **Buschmann, A., G. Luhken, J. Schultz, G. Erhardt, and M. H. Groschup.** 2004. Neuronal accumulation of abnormal prion protein in sheep carrying a scrapie-resistant genotype (PrPARR/ARR). J. Gen. Virol. **85:**2727–2733.
11. **Casalone, C., C. Corona, M. I. Crescio, F. Martucci, M. Mazza, G. Ru, E. Bozzetta, P. L. Acutis, and M. Caramelli.** 2005. Pathological prion protein in the tongues of sheep infected with naturally occurring scrapie. J. Virol. **79:**5847–5849.
12. **Collis, S. C., and R. H. Kimberlin.** 1985. Long-term persistence of scrapie infection in mouse spleens in the absence of clinical disease. FEMS Lett. Microbiol. Lett. **29:**111–114.
13. **European Commission for Food Safety: Scientific Steering Committee.** 2002. Update of the opinion on TSE infectivity distribution in ruminant tissues. http://europa.eu.int/comm/food/fs/bse/scientific_advice08_en.html.
14. **Fay, R. A., and R. Norgren.** 1997. Identification of rat brainstem multisynaptic connections to the oral motor nuclei using pseudorabies virus III. Lingual muscle motor systems. Brain Res. Rev. **25:**291–311.

15. **Heggebo, R., C. M. Press, G. Gunnes, K. I. Lie, M. A. Tranulis, M. Ulvund, M. H. Groschup, and T. Landsverk.** 2000. Distribution of prion protein in the ileal Peyer's patch of scrapie-free lambs and lambs naturally and experimentally exposed to the scrapie agent. J. Gen. Virol. **81:**2327–2337.
16. **Kascsak, R. J., R. Rubenstein, P. A. Merz, M. Tonna-DeMasi, R. Fersko, R. I. Carp, H. M. Wisniewski, and H. Diringer.** 1987. Mouse polyclonal and monoclonal antibody to scrapie-associated fibril proteins. J. Virol. **61:**3688–3693.
17. **Klein, M. A., R. Frigg, E. Flechsig, A. J. Raeber, U. Kalinke, H. Bluethmann, F. Bootz, M. Suter, R. M. Zinkernagel, and A. Aguzzi.** 1997. A crucial role for B cells in neuroinvasive scrapie. Nature **390:**687–690.
18. **Mabbott, N. A., F. Mackay, F. Minns, and M. E. Bruce.** 2000. Temporary inactivation of follicular dendritic cells delays neuroinvasion of scrapie. Nat. Med. **6:**719–720.
19. **Mabbott, N. A., A. Williams, C. F. Farquhar, M. Pasparakis, G. Kollias, and M. E. Bruce.** 2000. Tumor necrosis factor alpha-deficient, but not interleukin-6-deficient, mice resist peripheral infection with scrapie. J. Virol. **74:**3338–3344.
20. **Mabbott, N. A., J. Young, I. McConnell, and M. E. Bruce.** 2003. Follicular dendritic cell dedifferentiation by treatment with an inhibitor of the lymphotoxin pathway dramatically reduces scrapie susceptibility. J. Virol. **77:**6845–6854.
21. **McBride, P. A., W. J. Schulz-Schaeffer, M. Donaldson, M. E. Bruce, H. Diringer, H. A. Kretzschmar, and M. Beekes.** 2001. Early spread of scrapie from the gastrointestinal tract to the central nervous system involves autonomic fibers of the splanchnic and vagus nerves. J. Virol. **75:**9320–9327.
22. **Montrasio, F., R. Frigg, M. Glatzel, M. A. Klein, F. Mackay, A. Aguzzi, and C. Weissmann.** 2000. Impaired prion replication in spleens of mice lacking functional follicular dendritic cells. Science **288:**1257–1259.
23. **Mulcahy, E. R., J. C. Bartz, A. E. Kincaid, and R. A. Bessen.** 2004. Prion infection of skeletal muscle cells and papillae in the tongue. J. Virol. **78:**6792–6798.
24. **National Research Council.** 1996. Guide for the care and use of laboratory animals. National Academy Press, Washington, D.C.
25. **Orge, L., A. Galo, C. Machado, C. Lima, C. Ochoa, J. Silva, M. Ramos, and J. P. Simas.** 2004. Identification of putative atypical scrapie in sheep in Portugal. J. Gen. Virol. **85:**3487–3491.
26. **Race, R., M. Oldstone, and B. Chesebro.** 2000. Entry versus blockade of brain infection following oral or intraperitoneal scrapie administration: role of prion protein expression in peripheral nerves and spleen. J. Virol. **74:**828–833.
27. **Sawczuk, A., and K. M. Mosier.** 2001. Neural control of tongue movement with respect to respiration and swallowing. Crit. Rev. Oral Biol. Med. **12:**18–37.
28. **Sigurdson, C. J., T. R. Spraker, M. W. Miller, B. Oesch, and E. A. Hoover.** 2001. PrP(CWD) in the myenteric plexus, vagosympathetic trunk and endocrine glands of deer with chronic wasting disease. J. Gen. Virol. **82:**2327–2334.
29. **Sigurdson, C. J., E. S. Williams, M. W. Miller, T. R. Spraker, K. I. O'Rourke, and E. A. Hoover.** 1999. Oral transmission and early lymphoid tropism of chronic wasting disease PrPres in mule deer fawns (Odocoileus hemionus). J. Gen. Virol. **80:**2757–2764.
30. **Somerville, R. A., C. R. Birkett, C. F. Farquhar, N. Hunter, W. Goldmann, J. Dornan, D. Grover, R. M. Hennion, C. Percy, J. Foster, and M. Jeffrey.** 1997. Immunodetection of PrPSc in spleens of some scrapie-infected sheep but not BSE-infected cows. J. Gen. Virol. **78:**2389–2396.
31. **Terry, L. A., S. Marsh, S. J. Ryder, S. A. Hawkins, G. A. Wells, and Y. I. Spencer.** 2003. Detection of disease-specific PrP in the distal ileum of cattle exposed orally to the agent of bovine spongiform encephalopathy. Vet. Rec. **152:**387–392.
32. **Thackray, A. M., M. A. Klein, and R. Bujdoso.** 2003. Subclinical prion disease induced by oral inoculation. J. Virol. **77:**7991–7998.
33. **Travers, J. B., N. Montgomery, and J. Sheridan.** 1995. Transneuronal labeling in hamster brainstem following lingual injections with herpes simplex virus-1. Neuroscience **68:**1277–1293.
34. **Ugolini, G.** 1995. Specificity of rabies of virus as a transneuronal tracer of motor networks: Transfer from hypoglossal motorneurons to connected second-order and higher-order central nervous system cell groups. J. Comp. Neurol. **356:**457–480.
35. **van Keulen, L. J., B. E. Schreuder, R. H. Meloen, G. Mooij-Harkes, M. E. Vromans, and J. P. Langeveld.** 1996. Immunohistochemical detection of prion protein in lymphoid tissues of sheep with natural scrapie. J. Clin. Microbiol. **34:**1228–1231.
36. **van Keulen, L. J., B. E. Schreuder, M. E. Vromans, J. P. Langeveld, and M. A. Smits.** 1999. Scrapie-associated prion protein in the gastrointestinal tract of sheep with natural scrapie. J. Comp. Pathol **121:**55–63.
37. **Wells, G. A., S. A. Hawkins, R. B. Green, A. R. Austin, I. Dexter, Y. I. Spencer, M. J. Chaplin, M. J. Stack, and M. Dawson.** 1998. Preliminary observations on the pathogenesis of experimental bovine spongiform encephalopathy (BSE): an update. Vet. Rec. **142:**103–106.
38. **Wells, G. A., J. Spiropoulos, S. A. Hawkins, and S. J. Ryder.** 2005. Pathogenesis of experimental bovine spongiform encephalopathy: preclinical infectivity in tonsil and observations on the distribution of lingual tonsil in slaughtered cattle. Vet. Rec. **156:**401–407.