University of Nebraska - Lincoln
DigitalCommons@University of Nebraska - Lincoln

Virology Papers | Virology, Nebraska Center for

11-1-2005

Interspecies Transmission of Chronic Wasting Disease Prions to Squirrel Monkeys (*Saimiri sciureus*)

Richard F. Marsh
University of Wisconsin, Madison

Anthony E. Kincaid
Creighton University, Omaha, Nebraska

Richard A. Bessen
Montana State University, Bozeman, Montana

Jason C. Bartz
Creighton University, Omaha, Nebraska, jbartz@creighton.edu

Follow this and additional works at: http://digitalcommons.unl.edu/virologypub

Part of the Virology Commons

Marsh, Richard F.; Kincaid, Anthony E.; Bessen, Richard A.; and Bartz, Jason C., "Interspecies Transmission of Chronic Wasting Disease Prions to Squirrel Monkeys (*Saimiri sciureus*)" (2005). *Virology Papers.* Paper 38.
http://digitalcommons.unl.edu/virologypub/38

This Article is brought to you for free and open access by the Virology, Nebraska Center for at DigitalCommons@University of Nebraska - Lincoln. It has been accepted for inclusion in Virology Papers by an authorized administrator of DigitalCommons@University of Nebraska - Lincoln.

JOURNAL OF VIROLOGY, Nov. 2005, p. 13794–13796 Vol. 79, No. 21
0022-538X/05/$08.00+0 doi:10.1128/JVI.79.21.13794–13796.2005
Copyright © 2005, American Society for Microbiology. All Rights Reserved.

NOTES

Interspecies Transmission of Chronic Wasting Disease Prions to Squirrel Monkeys (*Saimiri sciureus*)

Richard F. Marsh,[1]† Anthony E. Kincaid,[2] Richard A. Bessen,[3] and Jason C. Bartz[4]*

Department of Animal Health and Biomedical Sciences, University of Wisconsin, Madison 53706[1]; Department of Physical Therapy[2] and Department of Medical Microbiology and Immunology,[4] Creighton University, Omaha, Nebraska 68178; and Department of Veterinary Molecular Biology, Montana State University, Bozeman, Montana 59718[3]

Received 3 May 2005/Accepted 10 August 2005

Chronic wasting disease (CWD) is an emerging prion disease of deer and elk. The risk of CWD transmission to humans following exposure to CWD-infected tissues is unknown. To assess the susceptibility of nonhuman primates to CWD, two squirrel monkeys were inoculated with brain tissue from a CWD-infected mule deer. The CWD-inoculated squirrel monkeys developed a progressive neurodegenerative disease and were euthanized at 31 and 34 months postinfection. Brain tissue from the CWD-infected squirrel monkeys contained the abnormal isoform of the prion protein, PrP-res, and displayed spongiform degeneration. This is the first reported transmission of CWD to primates.

Chronic wasting disease (CWD) is a prion disease of elk and deer in North America that was first identified at cervid research facilities in Colorado and Wyoming in the late 1960s (17, 18). CWD has been identified on cervid game farms from Montana to New York and has been diagnosed in wild deer and elk in Colorado, Wyoming, Nebraska, South Dakota, Wisconsin, New Mexico, Illinois, and Utah and in Saskatchewan, Canada (1, 14, 15). The geographic distribution of CWD in deer and elk has been expanding and will likely result in an increase in human exposure to the CWD agent. Although there have been no cases of human prion disease linked to CWD infection, the risk of interspecies transmission of CWD to humans following consumption of CWD-infected tissues is uncertain (5, 13).

One approach to assess the susceptibility of humans to animal prion diseases is by experimental transmission to nonhuman primates (9–11). To investigate the susceptibility of nonhuman primates to CWD, two adult female squirrel monkeys (*Saimiri sciureus*) were intracerebrally (i.c.) inoculated with 200 μl of a 20% (wt/vol) brain homogenate from a female mule deer in the clinical phase of CWD (inoculum was a gift from Elizabeth Williams, Department of Veterinary Sciences, University of Wyoming, Laramie, WY). Both CWD-inoculated squirrel monkeys developed a progressive neurological disease and were euthanized at the terminal stages of disease at 31 and 34 months postinfection, respectively (data on clinical symptoms and the time to onset of disease were not available).

To determine whether the abnormal form of the prion protein, PrP-res, was present in the CWD-infected squirrel monkeys, brain homogenates were analyzed by Western blotting as previously described using the anti-PrP monoclonal antibody 6H4 (Prionics AG, Switzerland) (2). For this analysis, a 5% (wt/vol) brain homogenate in Dulbecco's phosphate-buffered saline (Mediatech, Inc.) from CWD-infected squirrel monkeys, a CWD-infected elk, or an uninfected mouse was either digested with proteinase K (PK) (4 U/ml; United States Biochemical) for 1 h at 37°C with agitation or was not digested with PK. In the samples that were not digested with PK, PrP migrated between 21 and 35 kDa in the CWD-infected squirrel monkeys (Fig. 1, lanes 1 and 2) and between 30 and 35 kDa in the CWD-infected elk (Fig. 1, lane 3) and in the uninfected mouse sample (Fig. 1, lane 4). In the samples that were digested with PK, PrP-res were detected in the two CWD-infected squirrel monkeys (Fig. 1, lanes 5 and 6) and in the CWD-infected elk sample (Fig. 1, lane 7). In the PK-digested uninfected mouse brain, PrP was not detected (Fig. 1, lane 8), indicating that PK digestion completely removed the PK-sensitive isoform of PrP. In both CWD-infected squirrel monkeys, the migration of the three PrP-res polypeptides on sodium dodecyl sulfate-polyacrylamide gels was similar. The diglycosylated PrP-res polypeptide migrated at 30 kDa similar to what has been reported for squirrel monkeys infected with sporadic Creutzfeldt-Jakob disease (CJD), kuru, and scrapie (4). The relative abundance of PrP-res in the brain from the squirrel monkey that was sacrificed at 34 months postinfection (Fig. 1, lane 5) was greater than that in the squirrel monkey sacrificed at 31 months postinfection (Fig. 1, lane 6) and may represent differences in the state of disease progression when the animals were sacrificed.

Histological examination of the brain, brain stem, and spinal cord from the squirrel monkey that was euthanized at 31 months postinfection revealed widespread spongiform changes that are consistent with CWD-induced neurodegeneration.

* Corresponding author. Mailing address: Department of Medical Microbiology and Immunology, Creighton University, 2500 California Plaza, Omaha, NE 68178. Phone: (402) 280-1811. Fax: (402) 280-1875. E-mail: jbartz@creighton.edu.

† Deceased.

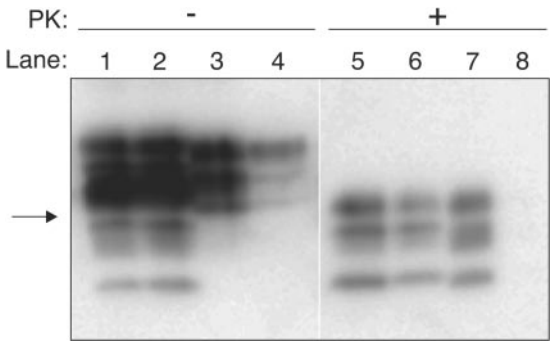

FIG. 1. Deposition of the abnormal isoform of the prion protein, PrP-res, in the brain of squirrel monkeys inoculated with chronic wasting disease. Western blot analysis of 250-μg tissue equivalents of brain homogenates digested with proteinase K or not digested with proteinase K was performed. The brain homogenates were from a CWD-infected squirrel monkey that was sacrificed at 34 months (lanes 1 and 5) or at 31 months postinfection (lanes 2 and 6), a CWD-infected elk (lanes 3 and 7), and an uninfected mouse (lanes 4 and 8). The arrow indicates the location of the 29-kDa molecular mass marker.

Spongiform lesions in the neuropil were predominantly located in subcortical gray matter structures of the forebrain. There was widespread spongiform change in the putamen, caudate nucleus, nucleus accumbens, lateral and medial hypothalamus, hippocampal formation (CA 1), amygdala, and dorsomedial thalamus (Fig. 2). Diffuse spongiosis was found in the interpeduncular nucleus and substantia nigra in the midbrain and in the reticular formation of the pons and medulla. Due to the limited number of histological sections, a detailed comparison of the neuropathology in CWD-infected squirrel monkeys and other prion transmission studies in squirrel monkeys was not possible.

The time to terminal disease following inoculation of squirrel monkeys with the CWD agent, 31 and 34 months, was longer than for squirrel monkeys that were i.c. inoculated with transmissible mink encephalopathy agent (9 to 12 months) and scrapie agent (16 months) but is within the reported range of the time to terminal disease following i.c. inoculation with sporadic CJD (11 to 37 months) and kuru (10 to 48 months) (6, 8). This variation in disease progression following experimental transmission of sporadic CJD, kuru, and CWD to squirrel monkeys could be due to differences in the inoculation dose, strain of the prion agent, or the ability to establish infection upon interspecies transmission. Regardless, this study illustrates that a nonhuman primate can develop a prion disease following i.c. inoculation with a brain homogenate from a CWD-infected mule deer.

Direct comparison of the ability of the CWD agent to cause disease in squirrel monkeys following experimental i.c. inoculation and the susceptibility of humans to CWD infection must be interpreted with caution. Although squirrel monkeys are susceptible to experimental infection with kuru and CJD, they are also susceptible to experimental infection with scrapie (8), and there is no epidemiological evidence to suggest that scrapie can be transmitted to humans (16). These data suggest, following direct cerebral inoculation, squirrel monkeys may not be a good experimental model for assessing human susceptibility to animal prion diseases. Oral exposure is the likely natural route of human exposure to CWD, and in experimental animals, this route is much less efficient at causing disease than i.c. inoculation (3, 7, 12). Therefore, the ability of scrapie and CWD to cause disease in primates by oral infection needs to be established to further resolve the issue of susceptibility of humans to CWD infection.

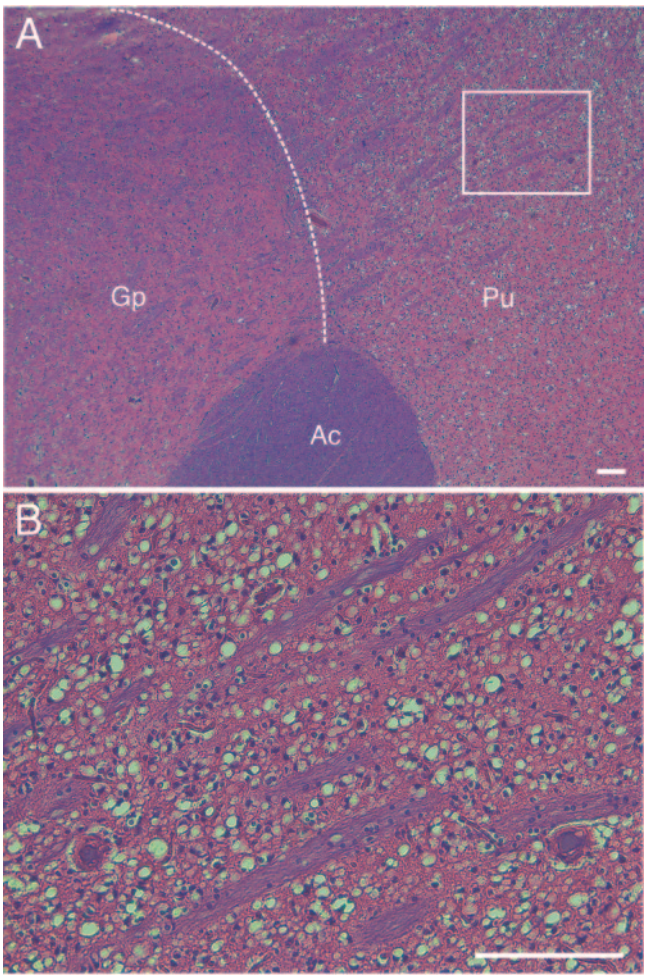

FIG. 2. Spongiform degeneration in brain tissue from a squirrel monkey inoculated with chronic wasting disease and euthanized at 31 months postinfection. (A) Low-power view of the lentiform nucleus, showing the distribution of spongiform changes in the putamen (Pu) and lack of spongiosis in the globus pallidus (Gp). Ac, anterior commissure. (B) High-power view of the area outlined in panel A that exhibits widespread spongiosis. Bars = 100 microns.

Richard Marsh, who performed the experimental transmission of CWD to squirrel monkeys, died in 1997 before these experiments were completed. Due to the emergence of CWD in deer and elk and the potential risk for CWD transmission to humans, we present his findings with additional tissue analysis.

We thank Al Jenny, USDA-APHIS-VS-NVSL for the gift of the CWD-infected elk tissue.

We dedicate the manuscript to Elizabeth Williams for her pioneering work on CWD.

REFERENCES

1. **Animal and Plant Health Inspection Services, Marketing and Regulatory Programs, U.S. Department of Agriculture.** 2005. [Online.] http://www.aphis.usda.gov/vs/nahps/cwd/cwd-distribution.html.

2. **Bartz, J. C., J. M. Aiken, and R. A. Bessen.** 2004. Delay in onset of prion disease for the HY strain of transmissible mink encephalopathy as a result of prior peripheral inoculation with the replication-deficient DY strain. J. Gen. Virol. **85:**265–273.
3. **Bartz, J. C., A. E. Kincaid, and R. A. Bessen.** 2003. Rapid prion neuroinvasion following tongue infection. J. Virol. **77:**583–591.
4. **Beekes, M., E. Baldauf, S. Cassens, H. Diringer, P. Keyes, A. C. Scott, G. A. Wells, P. Brown, C. J. Gibbs, Jr., and D. C. Gajdusek.** 1995. Western blot mapping of disease-specific amyloid in various animal species and humans with transmissible spongiform encephalopathies using a high-yield purification method. J. Gen. Virol. **76:**2567–2576.
5. **Belay, E. D., P. Gambetti, L. B. Schonberger, P. Parchi, D. R. Lyon, S. Capellari, J. H. McQuiston, K. Bradley, G. Dowdle, J. M. Crutcher, and C. R. Nichols.** 2001. Creutzfeldt-Jakob disease in unusually young patients who consumed venison. Arch. Neurol. **58:**1673–1678.
6. **Brown, P., C. J. Gibbs, Jr., P. Rodgers-Johnson, D. M. Asher, M. P. Sulima, A. Bacote, L. G. Goldfarb, and D. C. Gajdusek.** 1994. Human spongiform encephalopathy: the National Institutes of Health series of 300 cases of experimentally transmitted disease. Ann. Neurol. **35:**513–529.
7. **Diringer, H., J. Roehmel, and M. Beekes.** 1998. Effect of repeated oral infection of hamsters with scrapie. J. Gen. Virol. **79:**609–612.
8. **Gibbs, C. J., Jr., and D. C. Gajdusek.** 1973. Experimental subacute spongiform virus encephalopathies in primates and other laboratory animals. Science **182:**67–68.
9. **Gibbs, C. J., Jr., and D. C. Gajdusek.** 1972. Transmission of scrapie to the cynomolgus monkey (Macaca fascicularis). Nature **236:**73–74.
10. **Lasmezas, C. I., J. P. Deslys, R. Demaimay, K. T. Adjou, F. Lamoury, D. Dormont, O. Robain, J. Ironside, and J. J. Hauw.** 1996. BSE transmission to macaques. Nature **381:**743–744.
11. **Lasmezas, C. I., J. G. Fournier, V. Nouvel, H. Boe, D. Marce, F. Lamoury, N. Kopp, J. J. Hauw, J. Ironside, M. Bruce, D. Dormont, and J. P. Deslys.** 2001. Adaptation of the bovine spongiform encephalopathy agent to primates and comparison with Creutzfeldt-Jakob disease: implications for human health. Proc. Natl. Acad. Sci. USA **98:**4142–4147.
12. **Prusiner, S. B., S. P. Cochran, and M. P. Alpers.** 1985. Transmission of scrapie in hamsters. J. Infect. Dis. **152:**971–978.
13. **Raymond, G. J., A. Bossers, L. D. Raymond, K. I. O'Rourke, L. E. McHolland, P. K. Bryant, M. W. Miller, E. S. Williams, M. Smits, and B. Caughey.** 2000. Evidence of a molecular barrier limiting susceptibility of humans, cattle and sheep to chronic wasting disease. EMBO J. **19:**4425–4430.
14. **Sigurdson, C. J., and M. W. Miller.** 2003. Other animal prion diseases. Br. Med. Bull. **66:**199–212.
15. **Spraker, T. R., M. W. Miller, E. S. Williams, D. M. Getzy, W. J. Adrian, G. G. Schoonveld, R. A. Spowart, K. I. O'Rourke, J. M. Miller, and P. A. Merz.** 1997. Spongiform encephalopathy in free-ranging mule deer (Odocoileus hemionus), white-tailed deer (Odocoileus virginianus) and Rocky Mountain elk (Cervus elaphus nelsoni) in northcentral Colorado. J. Wildl. Dis. **33:**1–6.
16. **van Duijn, C. M., N. Delasnerie-Laupretre, C. Masullo, I. Zerr, R. de Silva, D. P. Wientjens, J. P. Brandel, T. Weber, V. Bonavita, M. Zeidler, A. Alperovitch, S. Poser, E. Granieri, A. Hofman, R. G. Will, and European Union (EU) Collaborative Study Group of Creutzfeldt-Jakob disease (CJD).** 1998. Case-control study of risk factors of Creutzfeldt-Jakob disease in Europe during 1993–95. Lancet **351:**1081–1085.
17. **Williams, E. S., and S. Young.** 1980. Chronic wasting disease of captive mule deer: a spongiform encephalopathy. J Wildl. Dis. **16:**89–98.
18. **Williams, E. S., and S. Young.** 1982. Spongiform encephalopathy of Rocky Mountain elk. J. Wildl. Dis. **18:**465–471.