University of Nebraska - Lincoln
DigitalCommons@University of Nebraska - Lincoln

Nebraska Game and Parks Commission -- Staff Research Publications

Nebraska Game and Parks Commission

4-1-1977

An Epornitic of Avian Cholera in Waterfowl and Common Crows in Phelps County, Nebraska, in the Spring, 1975

Joseph Zinkl
U.S. Fish and Wildlife Service

Norm Dey
Nebraska Game and Parks Commission

Joseph Hyland
Nebraska Game and Parks Commission

James Hurt
Nebraska Game and Parks Commission

Kenneth Heddleston
U.S. Department of Agriculture, Agricultural Research Service

Follow this and additional works at: http://digitalcommons.unl.edu/nebgamestaff

Part of the Environmental Sciences Commons

Zinkl, Joseph; Dey, Norm; Hyland, Joseph; Hurt, James; and Heddleston, Kenneth, "An Epornitic of Avian Cholera in Waterfowl and Common Crows in Phelps County, Nebraska, in the Spring, 1975" (1977). *Nebraska Game and Parks Commission -- Staff Research Publications.* Paper 43.
http://digitalcommons.unl.edu/nebgamestaff/43

This Article is brought to you for free and open access by the Nebraska Game and Parks Commission at DigitalCommons@University of Nebraska - Lincoln. It has been accepted for inclusion in Nebraska Game and Parks Commission -- Staff Research Publications by an authorized administrator of DigitalCommons@University of Nebraska - Lincoln.

AN EPORNITIC OF AVIAN CHOLERA IN WATERFOWL AND COMMON CROWS IN PHELPS COUNTY, NEBRASKA, IN THE SPRING, 1975

JOSEPH G. ZINKL,[1] NORM DEY,[2] JOSEPH M. HYLAND,[2] JAMES J. HURT[2] and KENNETH L. HEDDLESTON[3]

Abstract: In the spring of 1975, many species of waterfowl and common crows (*Corvus brachyrhynchos*) were found dead in Phelps County, Nebraska. About 25,000 waterfowl and at least 3,000 crows died in the epornitic. Few waterfowl were seen dying, but the crows experienced a chronic illness during which they became debilitated and were lethargic and dyspneic. Gross and microscopic lesions in the waterfowl were typical for acute avian cholera. The crows had dark, firm areas within the lungs, a loosely adhered yellow fibrous material in the pericardial sac and air sacs and, occasionally, liver abscesses. Microscopically, focal purulent pneumonia was present and a fibrinopurulent exudate overlaid a granulomatous reaction on the heart and lung surfaces. Isolation of *Pasteurella multocida* serotype 1 confirmed the diagnosis of acute and chronic avian cholera in the waterfowl and crows, respectively.

INTRODUCTION

Significant losses of wild birds have occurred in many parts of North America due to epornitics of avian cholera.[1,2,3] This report describes an outbreak of acute avian cholera in waterfowl that was accompanied by chronic avian cholera in common crows (*Corvus brachyrhynchos*). This epornitic occurred in south-central Nebraska during the height of the 1975 spring migration.

HISTORY

Following a brief snow storm on 2 April 1975, the Nebraska Game and Parks Commission received several reports of dead waterfowl on basins in the vicinity of Holdrege, Nebraska. Follow-up investigations by Commission personnel on 7 April disclosed an estimated 5,000 dead birds and resulted in a request for assistance from the U.S. Fish and Wildlife Health Laboratory. The first author was sent to the area to provide that assistance.

Concurrently, mortality also occurred among the Commission's flock of giant Canada geese (*Branta canadensis maxima*) at the nearby Sacramento-Wilcox Game Management area.[4] Two weeks earlier dead crows had been found on the Sacramento-Wilcox area, but crow mortality received little attention since crows in that area had suffered an epornitic of aspergillosis during the preceding fall[5] and the area manager assumed this same condition was reoccurring.

[1] U.S. Fish and Wildlife Service, Denver Wildlife Research Center, Bldg. 16, Federal Center, Denver, Colorado 80225, USA. Present address: Department of Clinical Pathology, University of California, Davis, California 95616, USA.

[2] Nebraska Game and Parks Commission, 2200 North 33rd Street, Lincoln, Nebraska 68503, USA.

[3] U.S. Department of Agriculture, Agricultural Research Service, National Animal Disease Center, Ames, Iowa 50010, USA.

This article is a U.S. government work, and is not subject to copyright in the United States.

FIELD OBSERVATIONS

Individuals from two species of geese, 13 species of ducks and American coots (*Fulica americana*) were examined at necropsy over a two day period between 8 and 10 April. Nearly all of these birds had large amounts of subcutaneous and abdominal fat, most had food in their proventriculus, and some had food in their esophagus. These observations are consistent with a rapid course of death. Gross lesions included 1-10 mm diameter necrotic foci scattered throughout the liver of all birds. Some birds had engorged spleens containing small white foci. In addition, petechial hemorrhages were present in the heart fat, in muscle, and in the abdominal fat. Also, the abdominal vessels, especially those on the external surface of the gizzard, were extremely engorged. A presumptive diagnosis of acute avian cholera was made on the basis of these lesions. This diagnosis was further substantiated by the findings of numerous bipolar Gram-negative rod-like organisms in liver impression smears stained with Wright's stain.

Gross lesions observed in crows were confined to the respiratory system, pericardial sac and liver. The air sacs and the pericardial sac contained a yellow fibrinous material that was loosely adhered to the adjacent organs. The lungs had dark, firm areas, which in some birds involved most of the lobe. Single or multiple liver abscesses were found in a few crows. Lesions suggestive of either aspergillosis or acute avian cholera were not found. A presumptive diagnosis could not be made from these lesions, but avian cholera was considered the most likely cause of mortality because of the close association of the crows with avian cholera infected waterfowl.

Although waterfowl rarely were seen dying, those observed usually were on their sternums and showing terminal convulsions, consisting of slow wing beating and opisthotonos; often their tails, wings, and legs were spread. Shortly before death waterfowl appeared disoriented and sometimes were seen flying upside-down before plunging into the water or on the ground. Death usually occurred within 5 min. after a sick bird was discovered. A clear nasal discharge often was seen at death.

CONTROL ACTIVITIES

On 9 April, carcass removal was initiated to prevent further contamination of water areas and to prevent scavengers, such as crows, from spreading the disease. Dead birds from all major water areas in the vicinity of Holdrege were burned in a pit that was later covered with earth. Before burning, the birds were identified to species and any leg bands present were removed. The greatest losses occurred among white-fronted geese (*Anser albifrons*), Canada geese (*Branta canadensis*), mallards (*Anas platyrhynchos*), pintails (*Anas acuta*), American wigeon (*Anas americana*), and green-winged teal (*Anas carolinensis*) (Table 1); these losses probably represent species abundance in the infected area rather than any differences in species susceptibility.

Clean-up operations were completed during the next two weeks, during which time the majority of the birds migrated north and the remaining reduced local population levels fell below the level needed to sustain the epornitic. A total of 13,749 waterfowl carcasses were burned during this time and it is estimated that 20-25,000 waterfowl died. Of this total, losses among geese were estimated to be 10,000 of the 75,000 geese (13.3%) and 15,000 of the 90,000 ducks at risk on the area (16.7%). In addition, 1,195 of the estimated 3,000 crows that died were burned, a loss representing 20% of the estimated 15,000 crows in the area. No attempts were made to clean up waterfowl or crow carcasses from the surrounding agricultural fields. Most of these carcasses were buried when farmers tilled their fields.

Because this epornitic of avian cholera was in the immediate area of previous sightings of migrating whooping cranes (*Grus americana*), contingency plans were formulated at the start of control activities to keep whooping cranes

TABLE 1. Birds burned during avian cholera outbreak in Nebraska in 1975.

Species	Number	Percent[a]
Geese		
White-fronted (*Anser albifrons*)	4,865	35.40
Canada (*Branta canadensis*)	749	5.40
Snow (*Chen hyperborea*)	5	0.04
TOTAL	5,619	40.84
Surface-feeding Ducks		
Mallard (*Anas platyrhynchos*)	2,882	21.00
Pintail (*Anas acuta*)	2,593	18.90
American Wigeon (*Anas americana*)	1,322	9.60
Gadwall (*Anas strepera*)	228	1.70
Northern Shoveler (*Anas clypeata*)	14	0.10
Green-winged teal (*Anas crecca carolinensis*)	730	5.30
Blue-winged Teal (*Anas discors*)	23	0.20
Wood Duck (*Aix sponsa*)	2	0.01
TOTAL	7,794	56.81
Diving Ducks		
Lesser Scaup (*Aythya affinis*)	47	0.30
Redhead (*Aythya americana*)	113	0.80
Canvasback (*Aythya valisineria*)	11	0.08
Ring-necked Duck (*Aythya collaris*)	3	0.02
Bufflehead (*Bucephala albeola*)	1	0.01
Ruddy Duck (*Oxyura jamaicensis*)	42	0.30
TOTAL	217	1.51
Others		
American Coot (*Fulica americana*)	114	0.80
Pied-billed Grebe (*Podilymbus podiceps*)	3	0.02
Common Mergansers (*Mergus merganser*)	1	0.01
Sandhill Crane (*Grus canadensis*)	1	0.01
TOTAL	119	0.84
GRAND TOTAL	13,749	
Common Crow (*Corvus brachyrhynchos*)	1,195	

[a]Percent of total dead waterfowl (excludes crows).

from using the area during the spring of 1975. Necessary permits were granted by the U.S. Fish and Wildlife Service to harass whooping cranes from the area if they arrived. In the evening of 17 April, nine whooping cranes landed on a basin in the epornitic area. Weather conditions the next morning prevented the use of aircraft to drive the cranes from the area and harassment from the ground only served to move them to another part of the same basin. That afternoon, an aircraft successfully herded seven of the whooping cranes north to the Platte River. The other two cranes flew to another pond in the area, but the next morning they also were moved north by harassment with the aircraft.

BACTERIOLOGY

Pasteurella multocida was isolated from the livers of 17 of 18 waterfowl and 6 of 8 crows, usually in pure culture. A gel diffusion test, using 16 different typing sera, revealed the isolates to be serotype 1. Subsequently, *P. multocida* was isolated from livers, lungs and air sacs of the crows necropsied on 28 April and 22 May. These isolates were not serotyped.

Amercian coot injected intramuscularly with as few as 300 bacteria died within 24 hr. Six of eight coot exposed to 2.3 X 10^7 bacteria/ml in their drinking water died within 16 hr.; the other two birds died within 2 days.

HISTOPATHOLOGY

Tissues taken at necropsy were fixed in 10% neutral buffered formalin, embeded in paraffin, sectioned at 8 μm and stained with hematoxylin and eosin. Livers of the waterfowl contained many bacteria colonies. Some of these were associated with foci of necrosis and acute inflammation consisting primarily of heterophils. Congestion was present in some livers. Necrosis, inflammation and bacteria were present in the spleens. There was no apparent relationship between species and frequency or severity of the lesions.

A fibrinopurulent exudate overlaying a granulomatous reaction consisting of fibrous tissue, capillaries, and a mononuclear infiltrate was seen on the heart, air sacs, and pleural surfaces of the lungs of crows (Fig. 1). Lung and liver adhesions were well developed granulation tissue. Lung lesions were focal or diffuse pneumonia consisting of necrosis, fibrin and cellular exudate. The periphery of these lesions contained many bacteria (Fig. 2). Abscesses in the liver contained cellular debris, heterophils and bacteria surrounded by a thin fibrous capsule. The surrounding liver sinusoids were dilated by inflammatory cells and contained many bacteria.

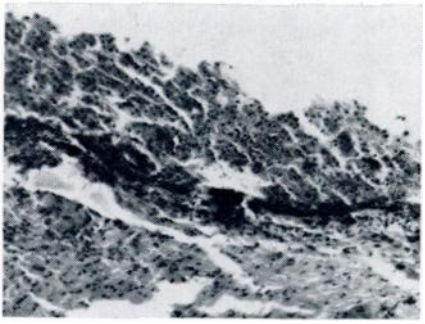

FIGURE 1. Fibrinopurulent exudate overlaying a narrow granulomatous reaction on the epicardium of a crow, H and E X 220.

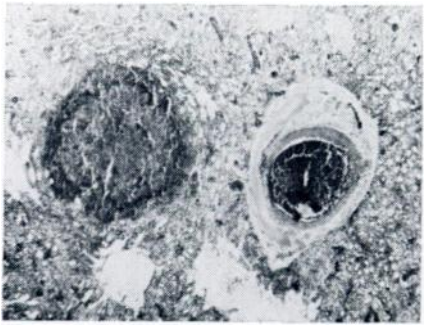

FIGURE 2. Focal necrosis containing bacteria, cellular debris, and inflammatory cells in the lung of a crow, H and E X 140.

DISCUSSION

This was the first confirmed outbreak of avian cholera in this area of Nebraska, although two previous epornitics in waterfowl along the Platte River in 1950 and 1964 also may have been due to avian cholera.[3] The factor initiating the 1975 outbreak is unknown. The spring storm on 2 April could have been a contributing factor, although carcasses collected in the field and observations of dead crows indicated mortality began at least two weeks prior to this time. Perhaps the greatest role of the storm was in further concentrating waterfowl, thereby facilitating rapid transmission of the disease. Other contributing factors could have been the low water conditions in the epornitic area and severe spring storms in northern Nebraska and in North and South Dakota. The shallow depths of the limited water areas available were conducive to the buildup of high concentrations of *P. multocida* from body discharges and tissues of infected birds. The severe weather to the north probably kept birds from continuing their migration.

The chronic nature of the disease observed in crows and the reports of crows dying in the area before the epornitic was recognized in waterfowl suggest that crows may have played an important role, if not as the original source of the outbreak, certainly in the transmission of the disease. Crows often were seen scavenging dead waterfowl, as well as feeding with geese in corn fields. Gulls are reported to be important in the transmission of avian cholera in California because of their scavenging habits and greater resistance to the disease than waterfowl;[3] perhaps crows filled a similar role during this epornitic.

The presence of nine whooping cranes on-site during a severe epornitic of avian cholera illustrates the potential danger of infectious disease to rare and endangered species. The wide host range of this disease and the high probability of the whooping cranes being exposed to the disease if they remained in the area justified the actions taken to move them. However, it should be recognized that special regulations govern rare and endangered species; without prior planning a delay of several days could have been encountered before the necessary permit was obtained to harass the whooping cranes from the area. Such a delay could have resulted in the loss of one or more of these whooping cranes.

LITERATURE CITED

1. FADDOUL, G. P., G. W. FELLOWS and J. BAIRD. 1967. Pasteurellosis in wild birds in Massachusetts. Avian Dis. 11: 413-418.
2. LOCKE, L. N. and R. C. BANKS. 1973. Avian cholera in cedar waxwings in Ohio. J. Wildl. Dis. 8: 106.
3. ROSEN, M. N. 1971. Avian cholera. In: *Infectious and Parasitic Diseases of Wild Birds.* Davis, J. W., Andersn, R. C., Karstad, L. and Trainer, D. O. (eds.) Iowa State Univ. Press, Ames, Iowa. p. 59-74.
4. ZINKL, J. G., J. J. HURT, J. M. HYLAND, N. DEY, D. STUDNICKA and D. D. KING. 1976. Treatment of captive giant Canada geese affected by avian cholera. Submitted to J. Wildl. Dis.
5. ———, J. M. HYLAND and J. J. HURT. 1976. Aspergillosis in common crows in Nebraska, 1974. J. Wildl. Dis. 13: 191-193.

Received for publication 25 October 1976