1-1-2011

AN UNUSUAL PRESENTATION OF A RIGHT OVARIAN DERMOID CYST

Justin B. Williams
Brooke Army Medical Center

Scott C. Orr
Brooke Army Medical Center

The Journal of Emergency Medicine, Vol. 41, No. 3, pp. 296–297, 2011
Published by Elsevier Inc.
Printed in the USA
0736-4679/$–see front matter

doi:10.1016/j.jemermed.2009.04.056

Visual Diagnosis in Emergency Medicine

AN UNUSUAL PRESENTATION OF A RIGHT OVARIAN DERMOID CYST

Justin B. Williams, MD* and Scott C. Orr, MD†

*Brooke Army Medical Center, Fort Sam Houston, Texas and †San Antonio Uniformed Services Health Education Consortium Emergency Medicine Residency Program, Brooke Army Medical Center, Fort Sam Houston, Texas

Reprint Address: Justin B. Williams, MD, SAUSHEC Emergency Medicine Residency, Brooke Army Medical Center, MCHE-EMR, 3851 Roger Brooke Dr., Fort Sam Houston, TX 78234-6200

INTRODUCTION

Dermoid cyst, or mature cystic teratoma, is the most common type of ovarian germ cell tumor. It is frequently multi-cystic, and contains sebaceous fluid as well as hair, teeth, bone, and skin. Dermoid cyst is a relatively common ovarian tumor that is an infrequent cause of abdominal and flank pain.

CASE REPORT

A 36-year-old nulliparous woman presented for right lower abdominal pain that began suddenly 24 h prior. It was severe, colicky pain with radiation to her right flank. She denied anorexia, fever, dysuria, hesitancy, frequency, vaginal bleeding or discharge, or change in bowel habits. Her last normal menstrual period was 1 month prior, and she was on depo-contraceptives. She was sexually active and monogamous. Her examination was significant for severe right lower quadrant abdominal tenderness with voluntary guarding, without rebound tenderness. She demonstrated right costovertebral angle tenderness. The pelvic and rectal examinations were normal. Urinalysis demonstrated moderate blood, ketones > 80 mg/dL, and a negative beta human chorionic gonadatropin. White blood cell count was 8400 cells per cubic mL, with 85% neutrophils. A non-contrast computed tomography (CT) scan of the abdomen and pelvis was obtained (Figure 1) followed by transvaginal ultrasonography (Figure 2).

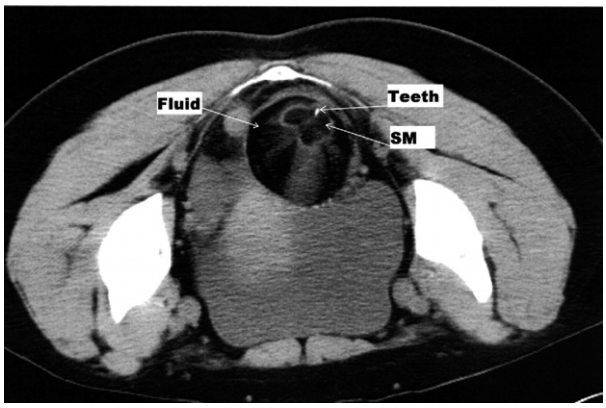

Figure 1. Non-contrast computed tomography scan of the abdomen and pelvis demonstrating a right ovarian dermoid cyst. Arrows demonstrate the classic fat (sebaceous material [SM])/fluid attenuation of a dermoid cyst with associated calcification/ossification (Teeth) representative of teeth or bone.

DISCUSSION

Dermoid cyst is a relatively common ovarian tumor that is an infrequent cause of abdominal and flank pain. Pain,

The conclusions and opinions reported by the authors do not necessarily reflect the official position of the U.S. Department of Defense or the United States Army.

RECEIVED: 4 September 2008; FINAL SUBMISSION RECEIVED: 20 January 2009;
ACCEPTED: 11 April 2009

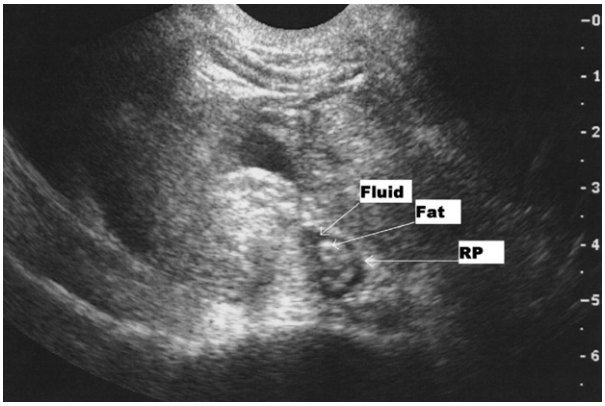

Figure 2. Transvaginal ultrasonography of the right ovary with the classic dermoid plug or Rokitansky protuberance (RP). The arrow demonstrates this classic ecogenic mass, representative of the fat/fluid interface within the dermoid cyst.

when it does occur, is from mass effect and ovarian torsion. These tumors have a classic radiographic and ultrasonographic appearance.

Dermoid cyst, or mature cystic teratoma, is the most common type of ovarian germ cell tumor, comprising up to 30% of all masses (1). They are bilateral in 10–13% of cases (2). The incidence of malignant elements in a teratoma is low (approximately 1–2%) (3). Gonadal dermoid cysts occur mostly during the reproductive years, between the ages of 20 and 40 years (4). They are frequently multi-cystic and contain sebaceous fluid as well as hair, teeth, bone, and skin. Typically, these tumors contain mature tissues of ectodermal (skin, brain), mesodermal (muscle, fat), and endodermal (mucinous or ciliated epithelium) origin (5). They have a characteristic CT scan appearance with fat/fluid level attenuation and calcification or ossification, as demonstrated in Figure 1 (6). The classic sonographic appearance is of a hyperechoic mass known as a dermoid plug or Rokitansky protuberance, as shown in Figure 2 (7). The Rokitansky protuberance is composed of the thickened area of ectodermal tissue from which hair and teeth arise. Pain is often related to the size of the mass, and ovarian torsion is common. Mature cystic teratomas grow slowly at an average rate of 1.8 mm each year, prompting some investigators to advocate non-surgical management of smaller (<6-cm) tumors (8).

In this case, our patient had ovarian torsion on laparotomy. Her pain was likely related not to the mass effect of the tumor but rather to the ischemic complications of the enlarged ovary twisting around its pedicle. Upon gross dissection, the tumor demonstrated a classic appearance of a mature cystic teratoma, demonstrating endodermal, mesodermal, and ectodermal tissues. The patient underwent right salpingo-oophorectomy followed by an uncomplicated post-operative course.

REFERENCES

1. Ayhan A, Bukulmez O, Genc C, Karamursel BS, Ayhan A. Mature cystic teratomas of the ovary: case series from one institution over 34 years. Eur J Obstet Gynecol Reprod Biol 2000;88:153–7.
2. Comerci JT Jr, Licciardi F, Bergh PA, Gregori C, Breen JL. Mature cystic teratoma: a clinicopathologic evaluation of 517 cases and review of the literature. Obstet Gynecol 1994;84:22–8.
3. Einarsson JI, Edwards CL, Zurawin RK. Immature ovarian teratoma in an adolescent: a case report and review of the literature. J Pediatr Adolesc Gynecol 2004;17:187–9.
4. Scully RE, Young RH, Clement PB. Tumors of the ovary, maldeveloped gonads, fallopian tube and broad ligament. Atlas of tumor pathology. Third series, fascicle 23. Washington, DC: Armed Forces Institute of Pathology; 1998.
5. Outwater EK, Siegelman ES, Hunt JL. Ovarian teratomas: tumor types and imaging characteristics. Radiographics 2001;21:475–90.
6. Garant M, Reinhold C. Dermoid cyst of the ovary: computed tomography diagnosis of an unusual case. Can Assoc Radiol J 1996; 47:107–10.
7. Exacoustos C, Romanini ME, Rinaldo D, et al. Preoperative sonographic features of borderline ovarian tumors. Ultrasound Obstet Gynecol 2005;25:50–9.
8. Caspi B, Appelman Z, Rabinerson D, Zalel Y, Tulandi T, Shoham Z. The growth pattern of ovarian dermoid cysts: a prospective study in premenopausal and postmenopausal women. Fertil Steril 1997; 68:501–5.