University of Nebraska - Lincoln
DigitalCommons@University of Nebraska - Lincoln

Transactions of the Nebraska Academy of Sciences and Affiliated Societies

Nebraska Academy of Sciences

1-1-1993

Histamine-Immunoreactive Fibers in the Brain of *Rana pipiens*

Wayne Briner
University of Nebraska at Kearney

Paul Guth
Tulane University School of Medicine

Charles Norris
Tulane University School of Medicine

Follow this and additional works at: http://digitalcommons.unl.edu/tnas

Part of the Life Sciences Commons

Briner, Wayne; Guth, Paul; and Norris, Charles, "Histamine-Immunoreactive Fibers in the Brain of *Rana pipiens*" (1993). *Transactions of the Nebraska Academy of Sciences and Affiliated Societies.* Paper 117.
http://digitalcommons.unl.edu/tnas/117

This Article is brought to you for free and open access by the Nebraska Academy of Sciences at DigitalCommons@University of Nebraska - Lincoln. It has been accepted for inclusion in Transactions of the Nebraska Academy of Sciences and Affiliated Societies by an authorized administrator of DigitalCommons@University of Nebraska - Lincoln.

1993. *Transactions of the Nebraska Academy of Sciences*, XX: 73–80

HISTAMINE-IMMUNOREACTIVE FIBERS IN THE BRAIN OF *RANA PIPIENS*

Wayne Briner[1,*,2], **Paul Guth**[2], and **Charles Norris**[2,3]

[1]Department of Psychology
University of Nebraska at Kearney
Kearney, Nebraska 68849*
[2]Department of Pharmacology and
[3]Department of Otolaryngology
Tulane University School of Medicine
New Orleans, Louisiana 70112

*Author and address for correspondence.

ABSTRACT

Histamine (HA) is a neurotransmitter that has been found in the brains of several species. We examined the brain of *Rana pipiens* using a well-characterized antibody to HA conjugated to 1-ethyl-3(3diamethylaminopropyl)-carbodiimide (EDCDI) with immunohistochemistry (IHC). Staining was enhanced by pre-treating the animals with histidine, colchicine, and quinacrine. IHC staining was done in the standard fashion using the "ABC" technique. HA-immunoreactive (HA-IR) fibers in the brain of *Rana pipiens* were distributed in a manner similar to that found in other species. The cerebral hemispheres were lightly labelled in nearly all regions. The hippocampus and diencephalon were labelled. The septal and nuclei and basal ganglia also contained HA-IR fibers. The optic tectum and torus semicircularis all demonstrated HA-IR fibers. In the optic tectum the HA-IR fibers were limited to the gray layers and central white layer. The brainstem contains widely distributed HA-IR fibers. The cerebellum was lightly labelled in the Purkinje and molecular cell and fibrous regions.

† † †

Histamine (HA) is a putative neurotransmitter/neuromodulator which can have either an excitatory or inhibitory effect on neurons, depending on the system (Haas, 1985). HA has been found in the brains of several animals including rat (Panula et al., 1984; Reiner et al., 1987; Steinbusch and Mulder, 1984; Takeda et al., 1987; Watanabe et al., 1984), *Carcinus maenas* (Arnould 1987), bovine (Arbones et al., 1988), lamprey (Brodin et al., 1990), *Xenopus laevis* (Airaksinen and Panula, 1990), cockroach (Pirvola et al., 1988), molluscs (Brownstein et al., 1974; Turner and Cottrel, 1977; Weinreich, 1977), and lobster (Claiborne and Selverston, 1984). HA is presumed to exist and play a role in the brains of nearly all animals. HA has been implicated in the function of the hypothalamic system, the sleep/wake cycle, autonomic functions (Pollard and Schwartz, 1987) and vestibular function (Housley et al., 1988).

Studies in this laboratory on the role of HA in the vestibular system of the frog led us to investigate the central distribution of HA in this species. In addition, the study of this primitive brain may provide insight into to the functioning of advanced nervous systems.

MATERIALS AND METHODS

Rana pipiens (15–30g, n = 12) was used. To enhance labelling of HA-IR fibers, the frogs were treated with colchicine (0.5 mg/animal; Steinbusch and Mulder, 1984) to block axoplasmic transport, histidine (1 mg/animal; Steinbusch and Mulder, 1984) the precursor to HA, and quinacrine (1 mg/animal) to block the degradation of HA (Taylor and Snyder, 1972). Drugs were simultaneously administered by intraperitoneal injection, four to six hours prior to sacrifice. The animals were anesthetized by placing them for several minutes in a refrigerator, after which they were pithed. The animals were transcardially perfused with normal saline followed by a 3% solution of 1-ethyl-3(3diamethylaminopropyl)-carbodiimide (EDCDI, Sigma) in 0.1M phosphate buffer at a pH of 7.4 (6 cc) followed by 4% phosphate buffered paraformaldehyde. The skull was opened and the head immersed in a phosphate buffered solution of 3% EDCDI and 4% paraformaldehyde for at least 12 hours at 5° C. The brain was dissected from the skull and placed in phosphate buffered 30% sucrose followed by embedding in OCT compound and sectioning on a cryostat.

Free floating sections were used. Endogenous peroxidase activity was quenched with hydrogen peroxide. All subsequent solutions were made in 0.9% saline with 1% Triton-X-100 buffered with 0.05M Tris (Aitken et al., 1987). The tissue was pre-incubated in 5% normal goat serum and then incubated in primary antibody, 1:1500, with 1% normal goat serum for 48 hours at 5° C. The polyclonal antibody is specific for the HA-EDCDI

conjugate and has been characterized by others who have shown that the antibody is specific to HA and does not cross react with serotonin, l-histidine, d-histidine, beta-alanyl-histidine, l-histydyl-l-leucine, and thyrotropin-releasing hormone (Panula et al., 1984, 1988). In addition, we found no staining when the antibody was preabsorbed with HA. Following incubation with the primary antibody the antigen-antibody complex was labelled using the "ABC" technique (Vector Laboratories, Burlingame, CA). The tissue was incubated in 1:1000 biotinylated secondary antibody for 24 hours at 5° C and then in 1:500 avidin-biotin conjugate for 2 hours at room temperature. The entire complex was reacted with 3,3'-diaminobenzidine tetrachloride (DAB) and hydrogen peroxide. The tissue was cleared with dimethyl-sulfoxide (DMSO; Grace and Llinas, 1985; Reiner et al., 1987) for 12 hours followed by ethanol and xylene. Cell bodies are not visualized with this particular method. The labelled fibers depicting a representative brain were reconstructed on an atlas modified from Kemali and Braitenberg (1969) and from Ariens Kappers et al. (1936) using bright-field light microscopy with a drawing tube.

RESULTS

We have found HA-IR fibers in regions of the frog brain that correspond to labelling in the mammalian brain. Figures 1–3 provide a graphical representation of the distribution of HA-IR fibers in the brain of *Rana pipiens*.

The cerebral hemispheres were lightly labeled throughout except for the very rostral and caudal portions which were devoid of fibers. The fibers extended from the ventral to dorsal portions of the cortex and were not confined to any particular layer. The basal, lateral, and dorsal pallium all demonstrated fibers as did the septal and basal ganglion (Fig. 1A). The hippocampus demonstrated a crisscross pattern of fibers except caudally and dorsally where the fibers were diminished (Figs. 1A, 1B).

The amygdala was nearly devoid of fibers with a few seen caudally (Figs. 1A, 1B). HA-IR fibers were not seen in the medial septal nucleus or the medial most region of the lateral septal nucleus. In *Xenopus*, fibers were seen in both the medial and lateral septum (Airaksinen and Panula 1990). The external hippocampal fibers were accompanied by HA-IR fibers. The septal olfactory cortical tract contains HA-IR fibers only in its most ventral aspect and these did not extend upward toward the hippocampus or dorsal cortical structures. The medial and lateral forebrain bundles contained fairly large numbers of HA-IR fibers (Figs. 1A, 1B, 1C, 4).

Rostral to the optic chiasm and diencephalon the preoptic nuclei were labelled with HA-IR fibers that ran parallel and perpendicular to the axis of the preoptic recess. The perpendicular fibers extended beyond the region of the preoptic nuclei. Some HA-IR fibers extended to the MFB and others into the thalamus and hypothalamus. The commissure of the hippocampus and the inferior commissure all contained fibers which had the same orientation as the unlabelled fibers (Figs. 1C, 4).

Nearly the entire diencephalon (Figs. 2A, 5) was labelled for HA-IR fibers. The hypothalamus was labelled in a pattern similar to that of the preoptic nuclei. The dorsal thalamus (including lateral geniculate, habenula and subhabenula) was labelled. The ventral thalamus was labelled in the periventricular area and in the lateral regions. Fibers extend from those regions to the dorsal thalamic area. The olfactory thalamic tract and medial and lateral hypothalamic tracts also contained HA-IR fibers.

In the region of the optic chiasm the HA-IR fibers were sparse. Some fibers were seen extending into the optic chiasm and others into the periventricular region of the dorsal thalamus. However, the caudal region of the diencephalon was deficient in HA-IR fibers (Fig. 2B).

Caudal to the optic chiasm and rostral to the anterior optic tectum some HA-IR fibers were seen in the periventricular area accompanying the fibers of the posterior commissure (Fig. 2C). At the level of the tectal ventricle and aqueduct of Sylvius there was widespread distribution of HA-IR fibers (Fig. 3A). HA-IR fibers were distributed to each of the three gray layers of the periventricular stratum and the central white layer of the optic tectum (Fig. 6). HA-IR fibers were not seen in the remaining layers. In some instances these fibers appeared continuous with other HA-IR fibers seen in ventral tecto-bulbar tract, lateral lemniscus, spinal tectal tract, and oculomotor nucleus.

HA-IR fibers were seen in the torus semicircularus, particularly the periventricular regions. The aqueductal region also contained HA-IR fibers radiating toward the torus semicircularus. The commissure ansulata contained HA-IR fibers oriented in the same direction as other fibers in the tract. The tegmentum of the mesencephlon contained a moderate number of fibers arranged in a crisscross pattern. HA-IR fibers were not seen in the interpeduncular nucleus or lateral ophthalmic tract.

The metencephalon at the region of the cerebellum contained a widespread but light distribution of HA-IR fibers (Fig. 3B). Included in this distribution of HA-IR fibers was the MLF, the trigeminal nuclei, cerebellar

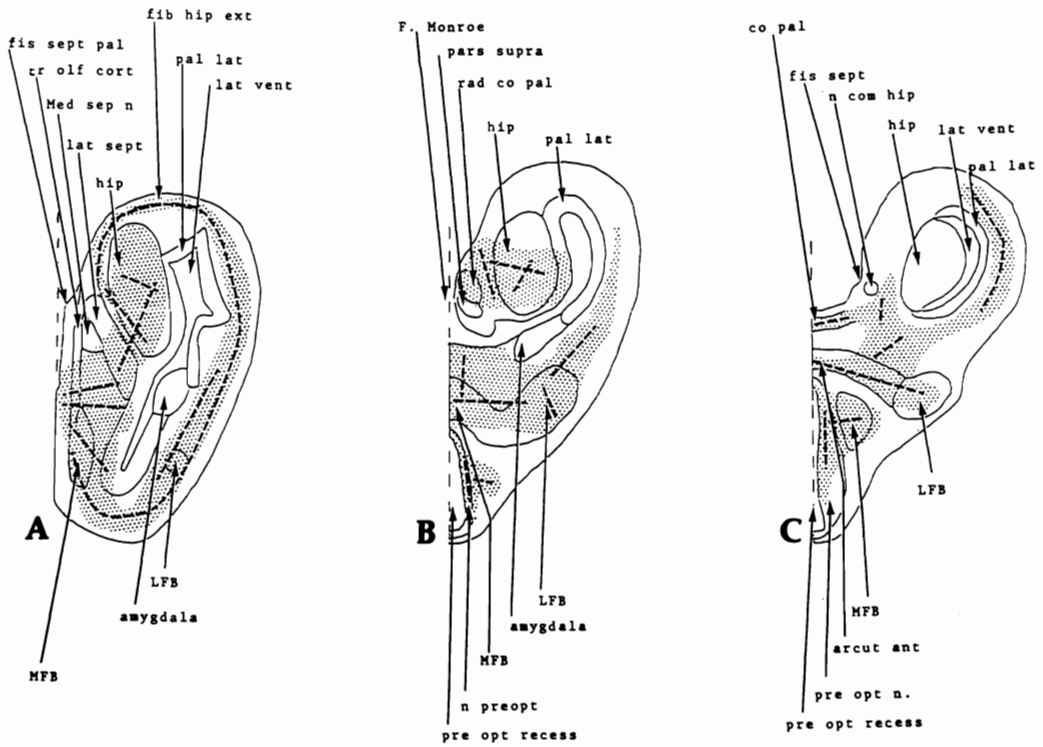

Figures 1A–C. Diagram of fiber distribution in the brain of *Rana pipiens*. Stippled areas indicate presence of HA-IR fibers. Dashed lines indicate general orientation of HA-IR fibers. The local "crisscross" pattern of fibers is not shown. Figures 1A–C. **1A**. Distribution of HA-IR fibers at the level of the cerebral hemispheres. **1B**. Distribution of HA-IR fibers at the region of the foramen of Monroe. **1C**. Diagram of section at most caudal end of hippocampus demonstrating the distribution of HA-IR fibers.

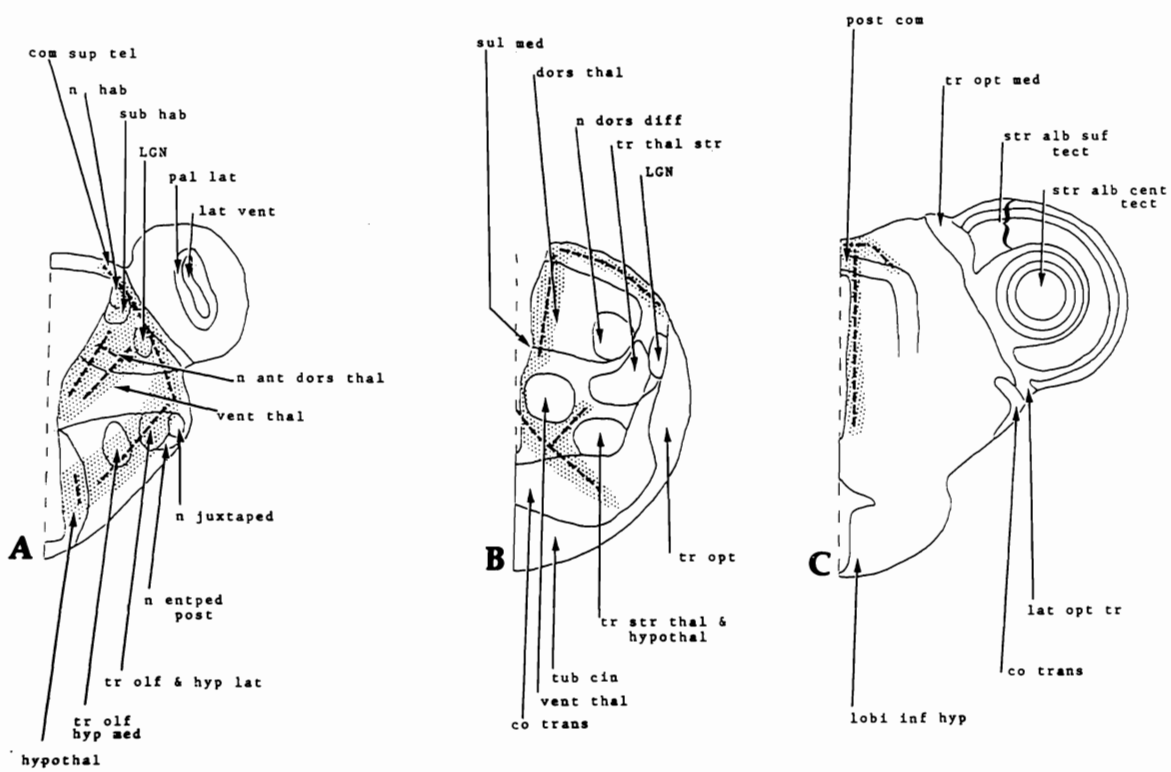

Figures 2A–C. **2A**. Diagram of HA distribution at anterior thalamic regions. **2B**. Diagram of HA distribution at posterior thalamic region. **2C**. Diagram of HA distribution at anterior most region of optic tectum.

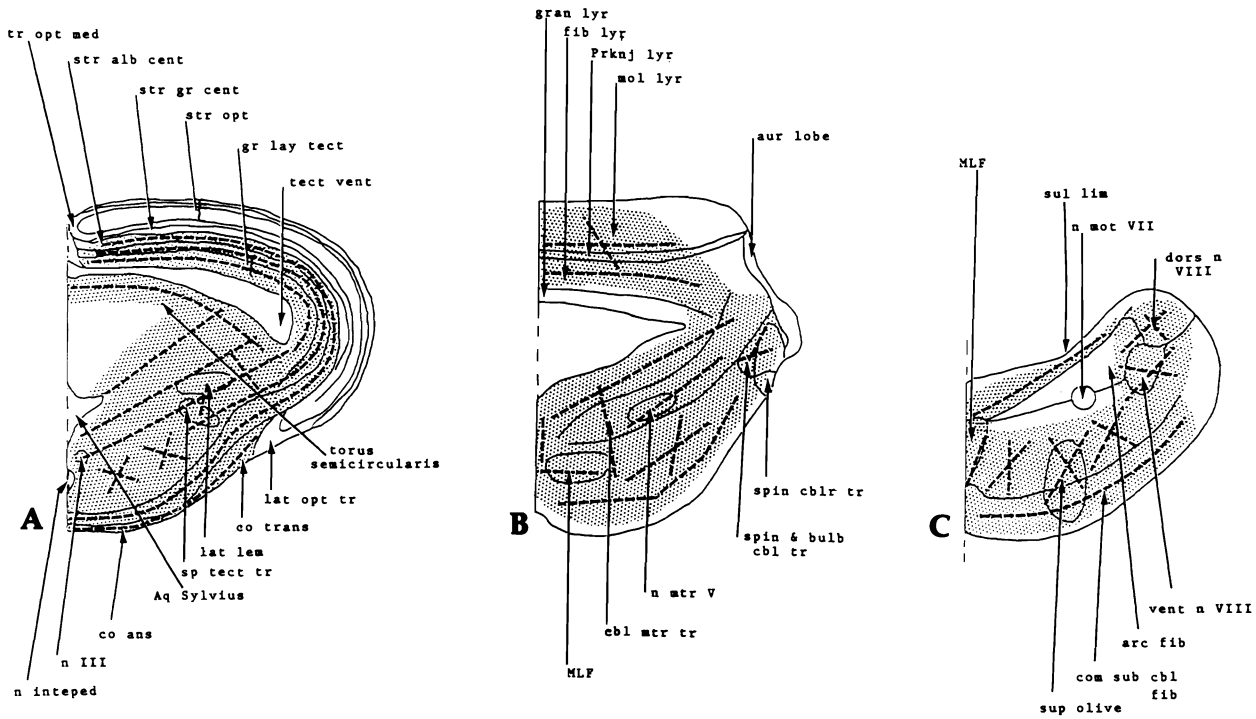

Figures 3A–C. **3A**. Diagram of HA distribution in mid-tectal level. **3B**. Diagram of HA distribution at level of cerebellum. **3C**. Diagram of HA distribution at level of VIII nerve root and nucleus.

motor tract, spinal cerebellar tract, and bulbar cerebellar tracts.

The cerebellum was very sparsely labelled. Some fibers originated in the fibrous region and extending through the Purkinje layer into the molecular region of the cerebellum. Some fibers traveled in a horizontal direction through the molecular layer and others through the fibrous layer. The auricular lobe did not contain HA-IR fibers and none were seen in the lateral regions of the cerebellum or granular layer (Fig. 3B). Airaksinen and Panula (1990) reported HA-IR fibers only in the granular layer of the cerebellum and cerebellar nuclei.

The tegmentum of the myelencephalon was characterized by widespread but sparse labelling of HA-IR with a crisscross pattern. Long fibers were seen following the fibers found in the commissure of subcerebellar fibers and MLF. Labelling was seen in the superior olivary complex, ventral and dorsal eighth nerve nuclei and the periventricular regions. No fibers were found in the area of the arcuate fibers or in the nucleus of the facial nerve or the root of the eighth nerve (Fig. 3C).

DISCUSSION/CONCLUSION

In mammals, HA neurons were located chiefly in the hypothalamic and mamillary nuclei and their associated structures (Panula 1986; Pollard and Schwartz, 1987; Steinbusch and Mulder, 1984; Watanabe et al., 1984) and project to almost all regions of the brain through two chief ascending pathways, the MFB and fornix/perforant path and the medial longitudinal fasiculis. The general distribution and pattern of fibers in this study of the frog is essentially the same as found in other species. The richest labelling of fibers occurs in the hypothalamic region and fibers appear to project to the rest of the amphibian brain via the MFB and LFB. The MLF of the frog is labelled for HA and this supports the contention that caudal regions are innervated via this tract.

The distribution of HA-IR fibers in the prosencephalon was similar to that for mammals save that we found few fibers in the amygdala. Airaksinen and Panula (1990) reported heavy labelling in the amygdala of *Xenopus*. Variations in amygdala labelling has been seen in the mammal. Small numbers of HA-IR fibers were found in the amygdala of the rat by Steinbusch

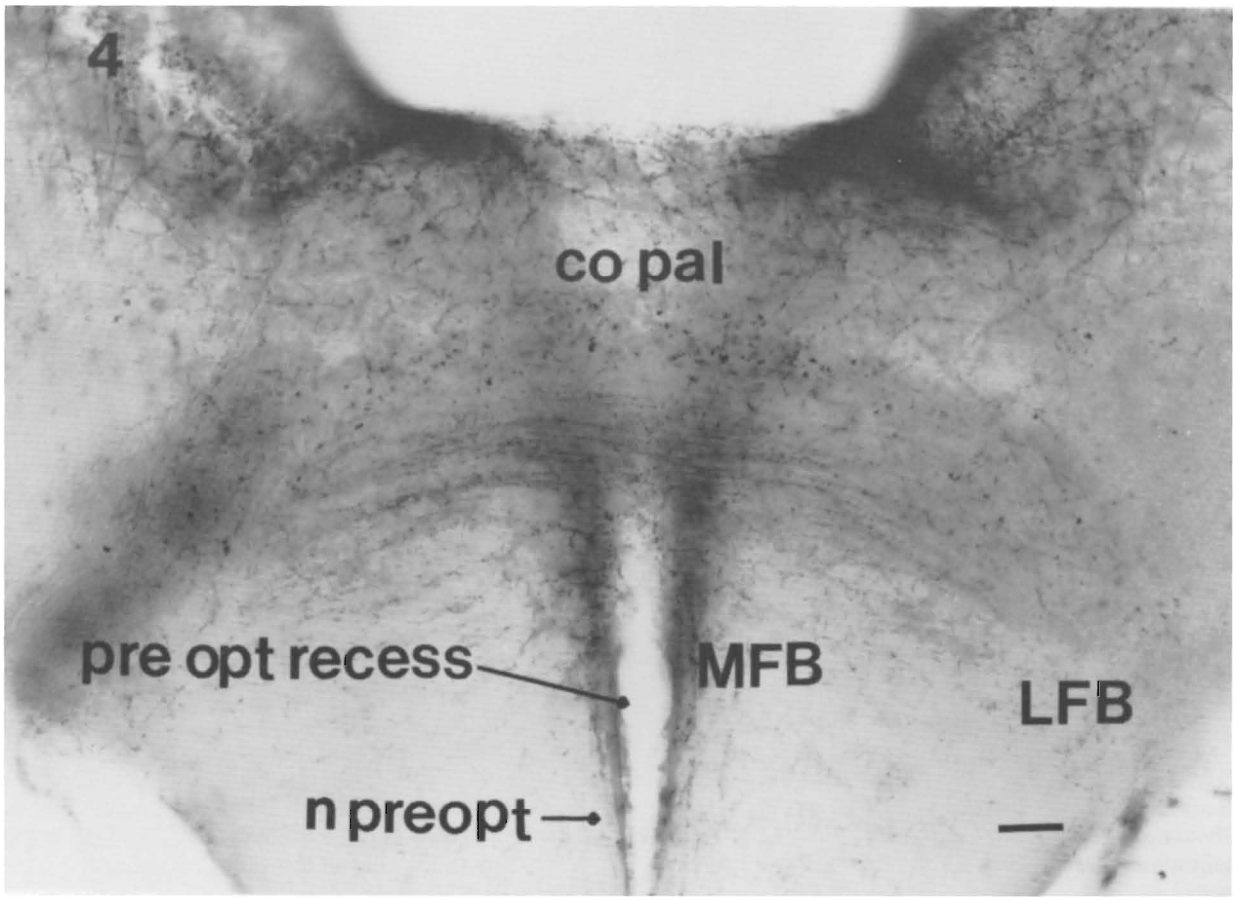

Figure 4. Photomicrograph of HA-IR fibers in the MFB, LFB and arcut. ant. at level of Figure 3. Scale bar = 500 microns (20×).

and Mulder (1984) but heavy labelling of the rat amygdala was reported by Watanabe et al (1984). The variations in labelling of the amygdala indicate that there may be some inter-species variation in the distribution of HA-IR fibers in this structure. The septal nuclei of the rat contain HA-IR fibers and Airaksinen and Panula (1990) reported labelling of the medial and lateral septal nuclei of *Xenopus*. We have found that the lateral, but not the medial septal nuclei, contain HA-IR fibers. The superior olivary complex has not been reported to contain HA-IR fibers as we have found in *Rana*.

HA-IR fibers were present in the vestibular nuclei, optic tectum, cerebellum and oculomotor nucleus, all structures involved in controlling eye movements and posture. These findings support the impressions of others that the HA system plays an important role in the vestibular-ocular-reflex (VOR) arc (Housley et al., 1988; Takeda et al., 1987). It is possible that HA may play a major role in the visual reflex arcs of more primitive species. This possibility is suggested by evidence in the cockroach (Pirvola et al., 1988) where HA is found in large amounts in the retina, optic lobes, and antennal lobes and *Carcinus* (Arnould, 1987) where HA is found in the eyestalk and other regions of the brain.

The distribution of HA-IR fibers appears to be conserved across the species. The differences that are seen are comparatively minor and indicate that the HA system has undergone few changes in its transition from the amphibian to the mammalian state. The great similarities in innervation pattern suggest that similar functions are retained; regulation of endocrine function, arousal, and other autonomic functions.

ACKNOWLEDGMENTS

We are indebted to Dr. P. Panula for his generous donation of the antibody used in this research and advice in preparing this tissue. We would also like to thank Mr. Butch Welch for his assistance with the photography and artwork. During this research Dr. Briner was supported by NIH training grant NSO-7058

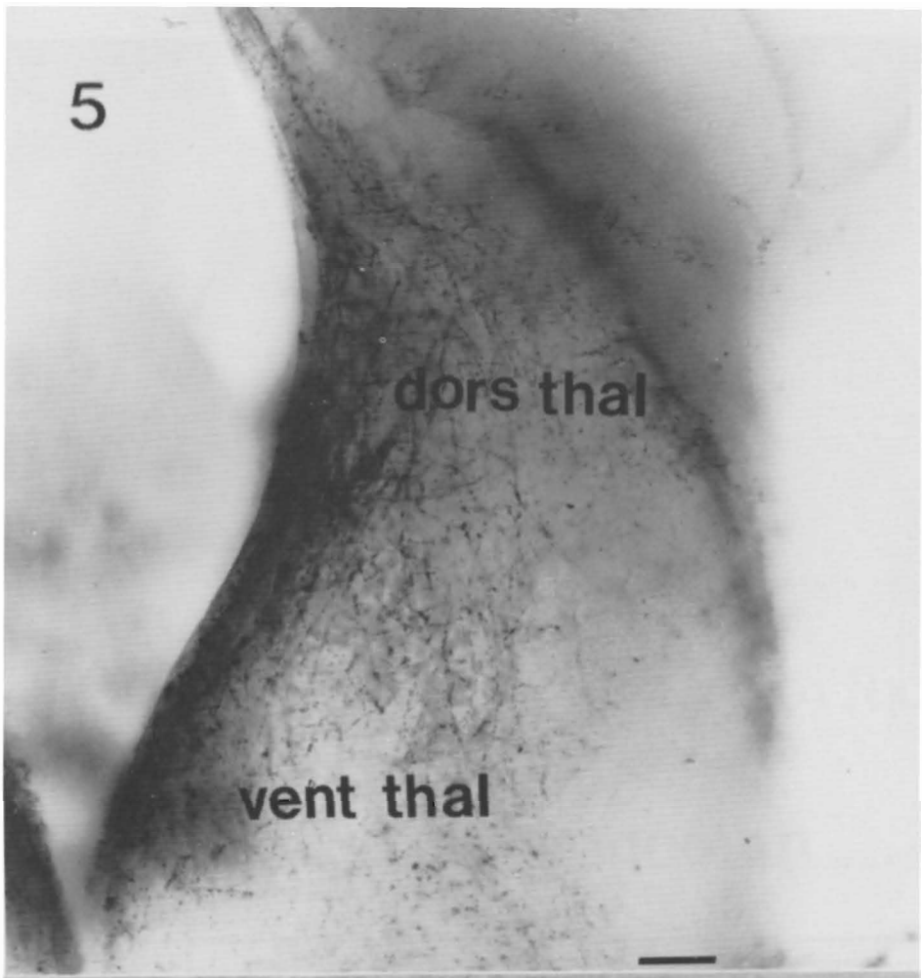

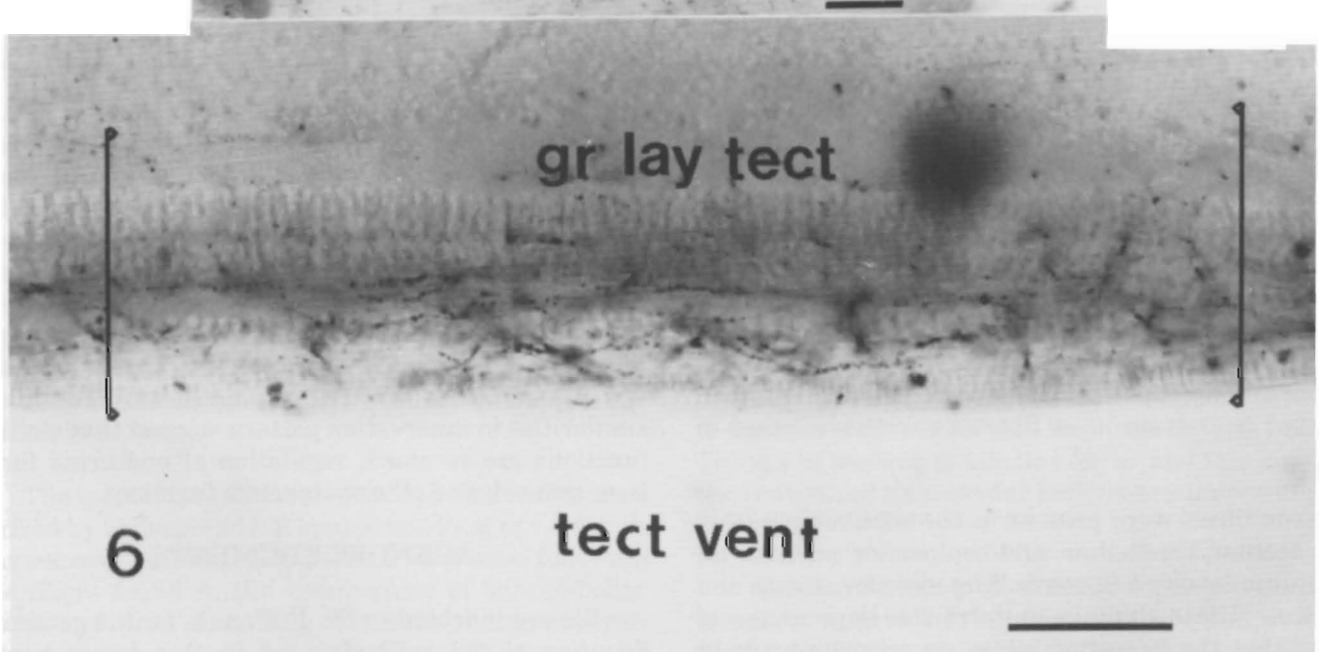

Figures 5–6. **Fig. 5**. Photomicrograph of HA-IR fibers in the mid-thalamic region. Level of brain between Figures 4 and 5. Scale bar = 500 microns (20×). **Fig. 6**. Photomicrograph of inner layers of the optic tectum at about the level of Figure 7. Note distribution of HA-IR fibers is limited to the gray layers and central white layer. Scale bar = 500 microns (40×).

GLOSSARY OF ABBREVIATIONS USED IN FIGURES

amygdala ..... amygdala
Aq Syl ..... Aqueduct of Sylvius
arc fib ..... arcuate fibers
arcut ant ..... commissura anterior pars arcuata inferior
aur lobe ..... auricular lobe of cerebellum
cbl mtr tr ..... cerebellar motor tract
co ans ..... commissura ansulata
co pal ..... commissura pallii/hippocampi
co trans ..... commissura transversa
com sub cbl fib ..... commissural subcerebellar fibers
com sup tel ..... commissura superior telencephali
dors n VIII ..... dorsal nucleus VIII (cochlear)
dors thal ..... dorsal thalamus
F. Monroe ..... Foramen of Monroe
fib hip ext ..... fibrae hippocampalis externae
fib lyr ..... fibrous layer of cerebellum
fis sept pal ..... fissura septopallialis
gr lay tect ..... gray layers of stratum griseum periventriculare
gran lyr ..... granular layer of cerebellum
hip ..... hippocampus
hypothal ..... hypothalamus
lat lem ..... lateral lemniscus
lat opt tr ..... tractus opticus lateralis
lat sep ..... lateral septal nucleus
lat vent ..... lateral ventricle
LFB. ..... lateral forebrain bundle
LGN. ..... lateral geniculate nucleus
lobi inf hyp ..... lobi inferiores hypothalami
med sep n ..... medial septal nucleus
MFB. ..... medial forebrain bundle
MLF. ..... medial longitudinal fasiculis
mol lyr ..... molecular layer of cerebellum
n ant dors thal ..... anterior dorsal nucleus of thalamus
n com hip ..... bed nucleus of pallial or hippocampal commissure
n dors diff ..... nucleus dorsalis diffusus
n entped post ..... nucleus entopeduncularis posterior
n hab ..... habenular nucleus
n III ..... nucleus III
n inteped ..... nucleus interpeduncularis
n juxtaped ..... nucleus juxtapeduncularis
n mot VII ..... motor nucleus VII
n mtr V ..... motor nucleus V
n preopt ..... preoptic nucleus
pal lat ..... pallium laterale
pars supra ..... pars supra superior septal fibers
post com ..... posterior commissure
pre opt recess ..... preoptic recess
Prknj lyr ..... Purkinje cell layer of cerebellum
rad co pal ..... radiations of commissura pallii/hippocampi
sp tect tr ..... spinal tectal tract
spin & bulb cbl tr ..... spinal and bulbar cerebellar tract
spin cblr tr ..... spinal cerebellar tract
str alb cent ..... stratum album centrale
str alb cent tect ..... stratum album centrale tecti
str alb suf tect ..... stratum album superficiale tecti
str gr cent ..... stratum griseum centrale
str opt ..... stratum opticum tecti
sub hab ..... area subhabenula
sul lim ..... sulcus limitans
sul med ..... medial sulcus
sup olive ..... superior olive
tect vent ..... tectal ventricle
torus semicircularis ..... torus semicircularis
tr olf cort ..... tractus olfacto-corticalis septi
tr olf hyp med ..... tractus olfacto-thalamicus et hypothalamicus medialis
tr olf & hyp lat ..... tractus olfacto-thalamicus et hypothalamicus lateralis
tr opt med ..... medial optic tract
tr opt ..... optic tract
tr str thal & hypothal ..... tractus strio-thalamicus et hypothalamicus
tr thal str ..... tractus thalamo-striatalis
tub cin ..... tuber cinerium
vent n VIII ..... ventral nucleus VIII (vestibular)
vent thal ..... ventral thalamus

to the Kresge Hearing Research Group of the South (via Drs. C. Berlin and P. Guth) and NIH grant NS22051 (now grant DC00303).

LITERATURE CITED

Airaksinen, M., and P. Panula. 1990. Comparative neuroanatomy of the Histaminergic system in the brain of the frog *Xenopus laevis*. *Journal of Comparative Neurology* 292: 412–423.

Aitken, A., Sandeman, and D. Sandeman. 1987. Preparation of immunoperoxidase-labelled wholemounts of invertebrate brains. *Journal of Neuroscience Methods* 21: 1–7.

Arbones, L., J. García-Verdugo, F. Picatoste, and A. García. 1988 Presence and distribution of histaminergic components in rat and bovine retina. *Neurochemistry International* 13: 97–104.

Ariens Kappers, C., C. Huber, and E. Crosby. 1936. *The comparative anatomy of the nervous system of vertebrates, including man.* New York, MacMillan.

Arnould, J.-M. 1987. Biosynthèse et métabolisme de l'histamine dans le système nerveux central de *Carcinus maenas*. *Archives Internationale de Physiologie et de Biochimie* 95: 43–55.

Brodin, L., T. Hokfelt, S. Grillner, and P. Panula. 1990. Distribution of histaminergic neurons in the brain of the lamprey *Lampetra fluviatilis* as revealed by histamine-immunohistochemistry. *Journal of Comparative Neurology* 292: 435–442.

Brownstein, M., J. Saavedra, J. Axelrod, G. Zeman, and D. Carpenter. 1974. Coexistence of several puta-

tive neurotransmitters in single identified neurons in aplysia. *Proceedings of the National Academy of Science* 71: 4662–4665.

Claiborne, B., and A. Selverston. 1984. Histamine as a neurotransmitter in the somatogastric nervous system of the spiny lobster. *Journal of Neuroscience* 4: 708–721.

Grace, A., and R. Llinas. 1985. Morphologic artifacts induced in intracellularly stained neurons by dehydration: circumvention using rapid dimethyl sulfoxide clearing. *Neuroscience* 16: 461–475.

Haas, H. 1985. Histamine. *In* Rogowski, M. and J. Barker, J. (eds), *Neurotransmitter actions in the vertebrate nervous system*, pp. 321–337. New York, Plenum Press.

Housley, G., C. Norris, and P. Guth. 1988. Histamine and related substances influence neurotransmission in the semicircular canal. *Hearing Research* 35: 87–98.

Kemali, M., and V. Braitenberg. 1969. Atlas of the frog's brain. New York, Springer-Verlag.

Panula, P. 1986. Neurochemistry, Modern methods and applications. New York, Plenum Press.

_____, Happola, O., Airaksinen, M., Auvinen, A., and Virkamaki, A. 1988. Carbodiimide as a tissue fixative in histamine immunocytochemistry and its application in developmental neurobiology. *Journal of Histochemistry and Cytochemistry* 36: 259–269.

_____, H.-Y. Yang, and E. Costa. 1984. Histamine containing neurons in the rat hypothalamus. *Proceedings of the National Academy of Science* 81: 2572–2576.

Pirvola, U., L. Tuomisto, A. Yamatodani, and P. Panula. 1988. Distribution of histamine in the cockroach brain and visual system: An immunocytochemical and biochemical study. *Journal of Comparative Neurology* 276: 514–526.

Pollard, H., and J.-C. Schwartz. 1987. Histamine pathways and their functions. *Trends in Neuroscience* 10: 86–89.

Reiner, P., K. Semba, T. Watanabe, and H. Wada. 1987. En bloc immunocytochemistry reveals extensive distribution of histidine decarboxylase-immunoreactive neurons on the ventral surface of the rat hypothalamus. *Neuroscience Letters* 77: 137–142.

Steinbusch, H. and A. Mulder. 1984. Immunohistochemical localization of histamine in neurons and mast cells in the rat brain. *In* Bjorklund, A., T. Hokfelt, and M. Kuhar (eds.), *Handbook of chemical neuroanatomy. Vol. 3: Classical transmitters and transmitter receptors in the CNS, Part II.* New York, Elsevier: 126–140

Takeda, N., M. Morita, T. Kubo, A. Yamatodani, T. Watanabe, M. Tohyama, H. Wada, and T. Matsunaga, T. 1987. Histaminergic projection from the posterior hypothalamus to the medial vestibular nucleus of rats and its relation to motion sickness. *In* Graham, M. and J. Kemink (eds.), *The vestibular system: Neurophysiologic and clinical research.* New York, Raven Press: 571–580.

Taylor, K., and S. Snyder. 1972. Histamine methyltransferase: Inhibition and potentiation by antihistamines. *Molecular Pharmacology* 8: 300–310.

Turner, J., and G. Cottrel. 1977. Properties of an identified neuron containing histamine. *Nature* 267: 447–448.

Watanabe, T., T. Taguchi, S. Shiosaka, J. Tanaka, H. Kubota, Y. Terano, M. Tohyama, and H. Wada. 1984. Distribution of the histaminergic neuron system in the central nervous system of rats: A fluorescent immunohistochemical analysis with histidine decarboxylase as a marker. *Brain Research* 295: 13–25.

Weinreich, D. 1977. Histamine containing neurons in aplysia. *In* Osborne, C. (ed.): *Biochemistry of characterized neurons.* Oxford, Pergamon: 153–175