University of Nebraska - Lincoln
DigitalCommons@University of Nebraska - Lincoln

Other Publications in Zoonotics and Wildlife Disease

Wildlife Disease and Zoonotics

1-1-2004

Transmission of transmissible mink encephalopathy to raccoons (*Procyon lotor*) by intracerebral inoculation

Amir N. Hamir
U.S. Department of Agriculture

Janice M. Miller
U.S. Department of Agriculture

Katherine I. O'Rourke
U.S. Department of Agriculture, katherine.orourke@ars.usda.gov

Jason C. Bartz
Creighton University

Mick J. Stack
Veterinary Laboratories Agency

See next page for additional authors

Follow this and additional works at: http://digitalcommons.unl.edu/zoonoticspub

Part of the Veterinary Infectious Diseases Commons

Hamir, Amir N.; Miller, Janice M.; O'Rourke, Katherine I.; Bartz, Jason C.; Stack, Mick J.; and Chaplin, Melanie J., "Transmission of transmissible mink encephalopathy to raccoons (*Procyon lotor*) by intracerebral inoculation" (2004). *Other Publications in Zoonotics and Wildlife Disease.* Paper 137.
http://digitalcommons.unl.edu/zoonoticspub/137

This Article is brought to you for free and open access by the Wildlife Disease and Zoonotics at DigitalCommons@University of Nebraska - Lincoln. It has been accepted for inclusion in Other Publications in Zoonotics and Wildlife Disease by an authorized administrator of DigitalCommons@University of Nebraska - Lincoln.

Authors
Amir N. Hamir, Janice M. Miller, Katherine I. O'Rourke, Jason C. Bartz, Mick J. Stack, and Melanie J. Chaplin

This article is available at DigitalCommons@University of Nebraska - Lincoln: http://digitalcommons.unl.edu/zoonoticspub/137

J Vet Diagn Invest 16:57–63 (2004)

Transmission of transmissible mink encephalopathy to raccoons (*Procyon lotor*) by intracerebral inoculation

Amir N. Hamir,[1] Janice M. Miller, Katherine I. O'Rourke, Jason C. Bartz, Mick J. Stack, Melanie J. Chaplin

Abstract. To determine the transmissibility of transmissible mink encephalopathy (TME) agent to raccoons and to provide information about clinical course, lesions, and suitability of currently used diagnostic procedures for detection of transmissible spongiform encephalopathies (TSEs) in raccoons, 4 raccoon kits were inoculated intracerebrally with a brain suspension from mink experimentally infected with TME. One uninoculated raccoon kit served as a control. All 4 animals in the TME-inoculated group showed clinical signs of neurologic disorder and were euthanized between 21 and 23 weeks postinoculation (PI). Necropsy examinations revealed no gross lesions. Spongiform encephalopathy was observed by light microscopy, and the presence of protease-resistant prion protein (PrP^{res}) was detected by immunohistochemistry and Western blot techniques. Scrapie-associated fibrils were observed by negative-stain electron microscopy in the brains of 3 of the 4 inoculated raccoons. These findings confirm that TME is experimentally transmissible to raccoons and that diagnostic techniques currently used for TSE in livestock detect prion protein in raccoon tissue. According to previously published data, the incubation period of sheep scrapie in raccoons is 2 years, whereas chronic wasting disease (CWD) had not shown transmission after 3 years of observation. Because incubation periods for the 3 US TSEs (scrapie, TME, and CWD) in raccoons appear to be markedly different, it may be possible to use raccoons for differentiating unknown TSE agents. Retrospective genotyping of raccoons using frozen spleens showed that the raccoon PrP gene is identical to the mink gene at codons 179 and 224. Further studies, such as the incubation periods of bovine spongiform encephalopathy and other isolates of scrapie, CWD, and TME in raccoons, are needed before the model can be further characterized for differentiation of TSE agents.

Transmissible mink encephalopathy (TME) is a progressive, fatal disease of ranch mink, which has been experimentally transmitted to cattle,[23] sheep and goats,[12] monkeys,[11,20] hamsters,[20] mink,[2] American sable (pine marten) and beech marten,[17] skunks, ferrets, and raccoons.[10] Although natural cases of transmissible spongiform encephalopathies (TSEs) have not been documented in raccoons, the ease with which TME can be experimentally transmitted to this species, via both oral and parenteral routes,[10] suggests that the disease may occur naturally in raccoons if TME-infected tissues are included in the animals' diet.[5,10]

Raccoons (*Procyon lotor*) are omnivores, and their diet may include carrion. Therefore, they could get exposed to carcasses of animals with TSEs.[5,10] Although naturally occurring TSEs have not been described in raccoons, experimental transmissions of TME and sheep scrapie have been documented.[10,14]

Primary objectives of this study were to determine whether the TME agent could be transmitted to raccoon kits by intracerebral inoculation[14] and to provide information about the incubation period and clinicopathological findings. This information was considered a necessary prerequisite before investigation of the raccoon as a biological model for differentiation of TSE agents.[14]

Materials and methods

Five 8-wk-old raccoon kits vaccinated against canine distemper were purchased from a breeder, assigned to TME-inoculated ($n = 4$) and uninoculated control ($n = 1$) groups, and housed in a biosafety level-2 containment facility at the National Animal Disease Center, Ames, Iowa. The raccoons were fed dry dog food[a] twice a day, and clean water was available ad libitum.

The inoculum was from the Stetsonville, Wisconsin outbreak of TME in 1985, which had been biologically cloned in mink 3 times by limiting end-point titration.[3] The mink brain tissue was ground in a mechanical grinder, and the final concentration of 10% (wt/vol) was made with 0.9% sterile saline solution.

The experimental raccoons were inoculated intracerebrally with 0.1 ml of TME brain inoculum as described previously.[14] In brief, the raccoon kits were sedated with ketamine and xylazine mixture, a midline

From the National Animal Disease Center, ARS, USDA, 2300 Dayton Avenue, PO Box 70, Ames, IA 50010 (Hamir, Miller), Animal Disease Research Unit, ARS, Pullman, WA 99164 (O'Rourke), Department of Medical Microbiology and Immunology, Creighton University, 2500 California Plaza, Omaha, NE 68178 (Bartz), and Veterinary Laboratories Agency, Woodham Lane, New Haw, Weybridge, Surrey KT15 3NB, UK (Stack, Chaplin). [1] Corresponding author.

This article is a U.S. government work, and is not subject to copyright in the United States.

Table 1. Raccoon kits experimentally inoculated with the TME agent.*

Animal no.	Sex	Intracerebral inoculation	Clinical signs	Euthanized	Survival time (wk)	Spongiform encephalopathy	IHC	WB	SAF
R1-2	F	TME	+	+	22	+	+	+	NT
R3-4	F	TME	+	+	23	+	+	+	+
R5-6	F	TME	+	+	21	+	+	+	+
R7-8	F	TME	+	+	21	+	+	+	+
R9-10	F	none	−	+	28	−	−	−	−

* IHC = immunohistochemistry for protease-resistant prion protein; NT = not tested; WB = Western blot[c]; SAF = scrapie-associated fibrils; M = male; F = female; NT = not tested; CWD = chronic wasting disease; TME = transmissible mink encephalopathy. + indicates the presence of clinical signs, lesions, or antigens. − indicates the absence of clinical signs, lesions, or antigens.

incision was made in the skin at the junction of the parietal and frontal bones, and a 2-mm hole was drilled through the calvarium. The inoculum was injected into the midbrain using a 22-gauge, 3.5 cm long needle while withdrawing the needle from the brain. The skin incision was closed with a single suture. One kit (control) was not inoculated (Table 1).

Animals were euthanized with pentobarbital, and a complete necropsy was conducted on each of the carcasses. Brain and spinal cord together with representative samples of heart, diaphragm, tongue, masseter muscle, lung, liver, gall bladder, kidney, pancreas, skin, spleen, eye, mesenteric lymph node, stomach, intestines, trachea, thyroids, esophagus, thoracic aorta, adrenal glands, salivary glands, urinary bladder, uterus, and ovaries or prostate were immersion fixed in 10% neutral buffered formalin. The brain (except for a small portion of frontal cortex that was frozen) was fixed in formalin for not less than 3 wk and was cut into serial coronal sections of 2–4 mm width, and all sections were processed for routine histopathology. A small piece of proximal cervical spinal cord was frozen, and the remainder of the cord was fixed in buffered formalin. Four samples each of cervical, thoracic, and lumbosacral areas of the fixed cord were selected for histopathology. The processed tissues were embedded in paraffin wax, sectioned at 5 μm, and stained with hematoxylin and eosin (HE). Six selected tissue sections (cerebrum, cerebellum, brain stem, and cervical, thoracic, and lumbosacral spinal cord) were stained by an immunohistochemical (IHC) method[21] for detection of protease-resistant prion protein (PrP^{res}) with an automated processor.[b] A cocktail of 2 monoclonal primary antibodies was used. These antibodies would recognize PrP sequences conserved in most mammalian species in which natural TSEs have been reported.[22] For immunodetection of PrP^{res}, a Western blot method[c] was used on frozen brain (cerebrum) as described previously.[24] Negative-stain electron microscopy was used to detect scrapie-associated fibrils (SAF) in fresh brain tissue (cerebrum).[25]

Frozen spleens of the experimental and control raccoons from this study and from 4 additional raccoons were used for characterization of the raccoon PrP gene polymorphisms. Deoxyribonucleic acid (DNA) was extracted from frozen spleen using a commercial kit[d] following the manufacturer's instructions. Amplification was performed with primer pairs based on ovine, cervid, mustelid, and canine PrP sequences. The canine primers yielded products suitable for cloning. Genomic DNA spanning codons 23–243 of the open-reading frame was amplified using forward primer 5′-CTG CAA GAA GCG GCC GAA GCC-3′ and reverse primer 5′-CAC GGG CGG CGG GGA GAA GAG CAT-3′, using 30 cycles of denaturation, annealing, and extension at 95 C (30 sec), 62 C (30 sec), and 72 C (59 sec). Polymerase chain reaction products were cloned into vector pCR4-TOPO using a commercial kit[e] as specified by the manufacturer. Clones with inserts of approximately 650 bp were selected for sequencing. Plasmid DNA was sequenced on the ABI Prism 377 DNA Sequencer with Big Dye Terminator chemistry[f] using T3 and T7 primers.

Results

Between 21 and 23 weeks after the intracerebral inoculations (postinoculation [PI]), all 4 inoculated animals showed clinical neurologic signs (Table 1). All were found to be lethargic, did not respond to external stimuli like normal raccoons, could not climb up to their sleeping quarters, and were generally unaware of their surroundings. Because of humane considerations, all 4 were euthanized (2 at 21 weeks, 1 at 22 weeks, and 1 at 23 weeks PI, Table 1). The uninoculated control raccoon was euthanized on week 28 after initiation of the experiment.

All 4 raccoons were in good nutritional state, and gross lesions were not present in any of the carcasses at necropsy. Microscopic lesions of spongiform encephalopathy were present in the gray matter of brain and spinal cord sections from all clinically affected raccoons. The severity of lesions was variable between individual animals and within the various neuroanatomic sites. Spongiform change was most prominent

in the cerebral cortex and consisted of severe extensive vacuolation in neuropil (Fig. 1). Vacuoles were round to oval and varied in size (up to 80 μm in diameter). There was mild to moderate gliosis in regions affected by spongiform change. Similar, but less severe, lesions were present in most nuclei of the brain stem and in gray matter of the spinal cord. Vacuolation of neuronal perikarya, although present in isolated neurons, was not frequently seen in the cerebral cortex but was more common in brain stem and spinal cord sections (Fig. 2). Neuronal degeneration was not a prominent feature in areas with spongiform change. Choroid plexus of 2 of the 4 inoculated raccoons revealed a few isolated blood vessels with concentric areas of mineralization (psammoma bodies). The uninoculated control raccoon did not have spongiform lesions in central nervous system (CNS) tissues.

Protease-resistant prion protein was detected by IHC in the brains and spinal cords of all 4 clinical raccoons. The anatomical distribution was widespread, appearing throughout the brain and spinal cord (Figs. 3, 4). Most of the reactivity was concentrated within neuronal cytoplasm. Staining within glial cells was uncommon, and there was no perineuronal or perivascular staining. Protease-resistant prion protein was not present in tissue sections from the control raccoon (No. R9-10; Table 1).

Protease-resistant prion protein was detected by Western immunoblotting in brain material from all 4 clinical raccoons (Table 1). A clear profile of the 3 polypeptide bands (diglycosylated, monoglycosylated, and unglycosylated) was observed in these animals (Fig. 5).

Scrapie-associated fibrils were detected in brain tissue extracts from 3 inoculated raccoons (insufficient brain material was available from 1 inoculated raccoon) but not from the control animal (Table 1; Fig. 6).

The raccoon PrP gene open-reading frame between codons 23 and 243 (GenBank AY208166) differed from the previously reported mink PrP gene[4] at 25 sites. Only 2 of these changes result in amino acid substitutions, relatively charge-neutral substitution of Asn for Ser at codons 46 and 107.

Discussion

Transmissible mink encephalopathy belongs to a group of fatal neurodegenerative diseases, the TSE. It is a rare food-borne disease of ranch mink first documented in Wisconsin in 1947.[10] The origin of TME is not known but is speculated to have originated from sheep scrapie or from an unknown TSE in cattle.[19,20]

A previously reported TME transmission study in raccoons had used adult raccoons[9], and disease was produced by means of intracerebral and oral inoculations in approximately 6 and 10 months, respectively. For the intracerebral route of inoculation, the researchers had used 0.3 ml of a 10% brain solution. In the present study, similar incubation times (21–23 weeks PI, Table 1) were achieved by inoculation of young, recently weaned kits with 0.1 ml of 10% brain inoculum.

Microscopic spongiform lesions in the CNS tissues were severe and diffuse in all 4 inoculated raccoons (Table 2). These changes were most severe in the cerebral cortex and were characterized by diffuse vacuolation of neuropil and moderate gliosis without appreciable neuronal vacuolation or degeneration. These observations are similar to those described in raccoons experimentally infected with TME[10] or sheep scrapie.[14]

Vacuolation of neuronal perikarya with some gliosis was observed in the brain stem and spinal cord regions of PrP^{res}-positive raccoons. Neuronal degeneration, however, was not prominent. Presence of psammoma bodies in choroid plexus of 2 of the 4 inoculated raccoons was considered an incidental finding in raccoons.[13]

Brains of the inoculated raccoons were positive for PrP^{res} by IHC and by the Western blot techniques. Also, SAF were observed in the brains of 3 of the 4 inoculated raccoons (Table 1). These findings confirm that raccoons are susceptible to TME by experimental intracerebral inoculation and will succumb to the infection within 6 months PI.

The IHC localization of PrP^{res} accumulation in brains of TME-inoculated raccoons was most prominent in the neuronal cytoplasm. A similar pattern of PrP^{res} distribution has previously been reported in experimental studies of scrapie transmission to raccoons and cattle.[7,8,14] It is interesting to note that the monoclonal antibodies used for IHC in this study detect PrP^{res} in raccoons with experimental TME because the same procedure does not detect PrP^{res} in mink with TME (Miller, personal observation). Previously, it was reported that several monoclonal and polyclonal antibodies to PrP^{res} failed to show immunoreactivity with tissues from mink with TME, the only positive response being detected with an antibody produced by inoculation of hamsters with mouse PrP.[18]

It could be argued that the PrP^{res} antigen seen in tissue sections was residual TME material from the inoculum. However, if this were true, then the PrP^{res} would most likely have been observed as locally extensive areas of PrP^{res} in the midbrain and cerebrum (at the site of inoculation). Instead, there was diffuse distribution of PrP^{res} throughout the brain and also in the spinal cords of inoculated raccoons. In experimental studies with sheep scrapie, it has been shown that intracerebrally inoculated material is not present in quantity large enough to be detected by currently

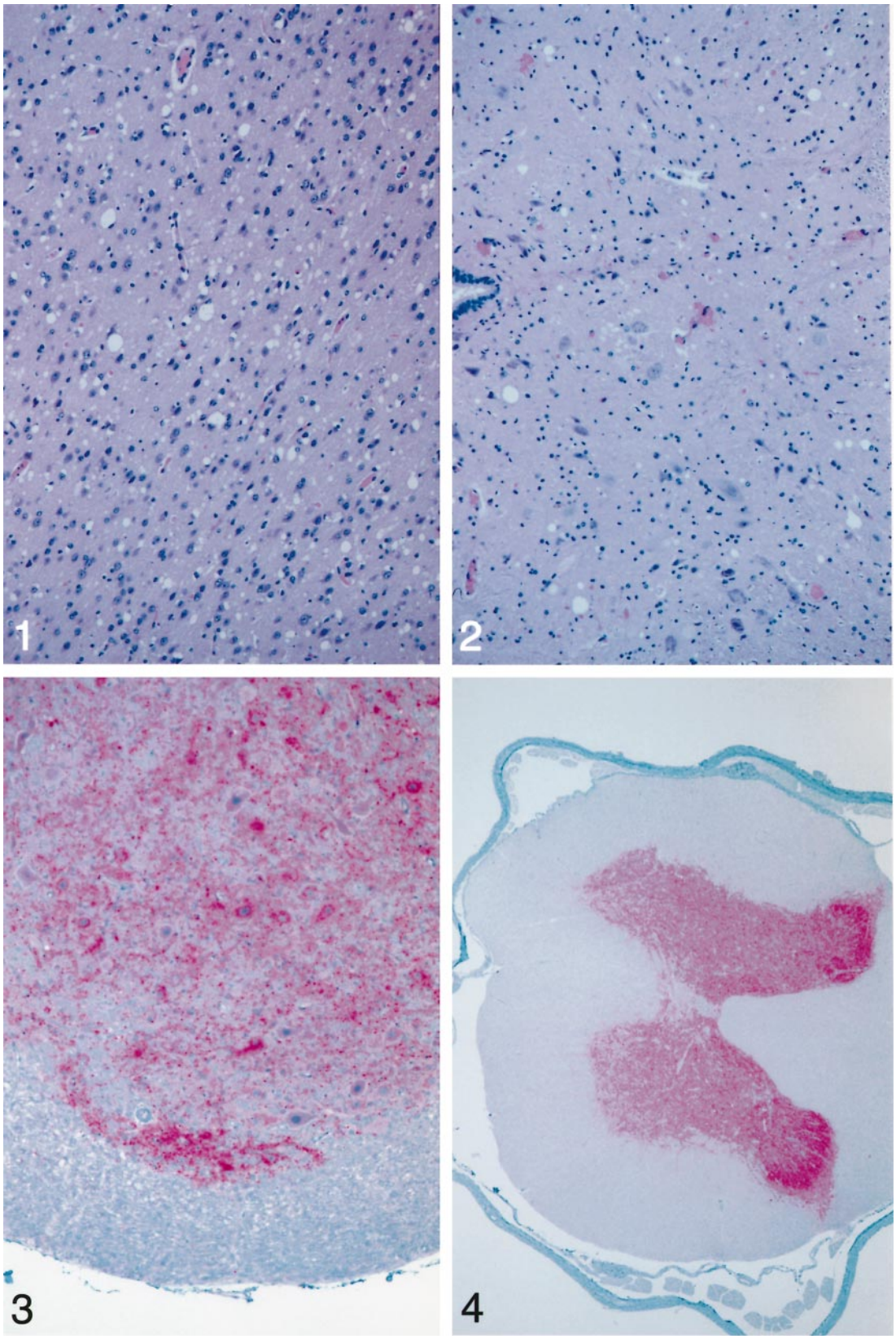

Figure 1. Brain; cerebral cortex of raccoon No. R5-6. There is severe diffuse vacuolation of the neuropil. HE. 200×.

Figure 2. Brain; medulla oblongata of raccoon No. R5-6 with moderate diffuse vacuolation of the neuropil. HE. 200×.

Figure 3. Brain; brain stem of raccoon No. R7-8. Multiple foci of PrP^{res} staining (red) are present within neuronal perikarya. Stained for PrP^{res} by IHC. 325×.

Figure 4. Thoracic spinal cord of raccoon No. R5-6. The PrP^{res} staining (red) is confined to the gray matter. Stained for PrP^{res} by IHC. 32×.

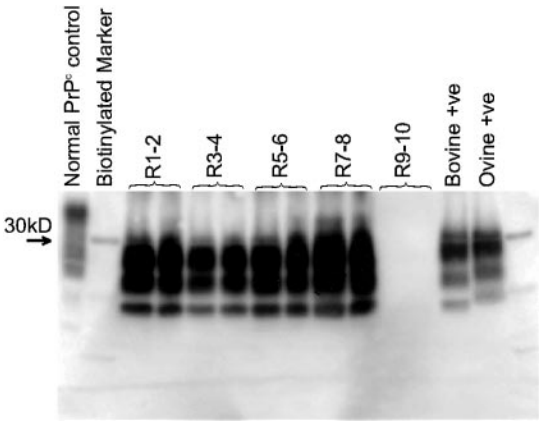

Figure 5. Western immunoblot showing distinct profile of PrP^{res} (molecular weight 27–30 kD) in the 4 positive raccoons. A normal, non–PK treated PrP^{c} control (molecular weight 33–35 kD) is in the first lane. Molecular weight marker positions are indicated on the right hand side of the image. Bovine + and ovine + refer to samples positive for bovine spongiform encephalopathy and scrapie, respectively.

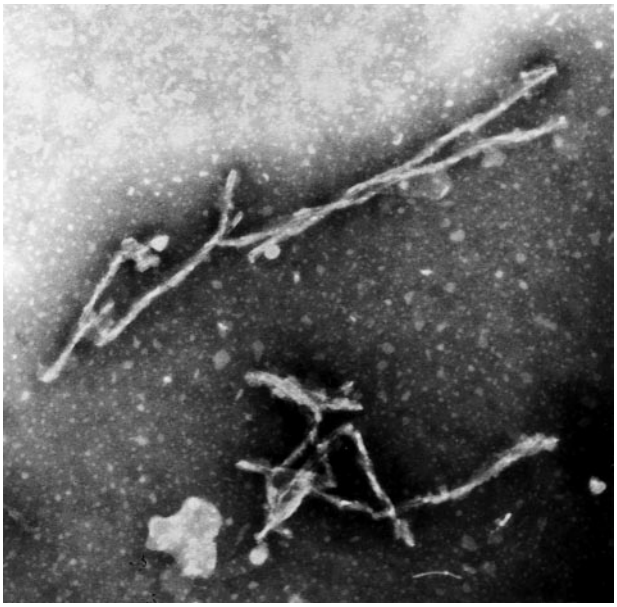

Figure 6. Negatively stained scrapie-associated fibrils (SAF) observed in brain tissue extract (caudal medulla) from raccoon No. R7-8. 78,000×.

available diagnostic methods using IHC, Western blot, and SAF after the first few days PI.[15,16]

Because characterization of the raccoon PrP gene and information concerning PrP polymorphisms were needed before the model could be recommended for differentiation of TSE agents, the study showed that the raccoon PrP gene open-reading frame between codons 23 and 243 differed from the previously reported mink PrP gene at 25 sites.[4] Only 2 of these changes result in amino acid substitutions at residues 46 and 107, resulting in the relatively charge-neutral substitution of Asn for Ser. Therefore, the raccoon gene is identical to the mink gene at codons 179 and 224. Amino acid substitutions at these sites in ferret may influence the relatively long incubation time in that species after experimental exposure to TME.[4] However, homology at these residues is not sufficient to result in the very short incubation times observed in this study. The ovine and cervid PRNP genes are also homologous to the mink and raccoon gene at residues 179 and 224 but differ at 10–15 other residues. Additional in vitro and in vivo transmission studies using TSE inocula from infected animals of varying PRNP genes may provide further evidence of sites critical for efficient interspecies transmission.

Although the intracerebral transmission route used in the present investigation does not mimic the natural route of infection, which in the wild would be via ingestion of infectious material, the study does confirm that raccoons are susceptible to TME. In previous experimental studies conducted at the authors' laboratory,[14] scrapie-inoculated raccoon kits developed TSE at approximately 2 years PI, whereas none of several chronic wasting disease (CWD)–inoculated kits had developed clinical disease within 3.5 years PI. This finding suggests that the raccoon could be used as a laboratory model to differentiate these 3 animal TSEs (scrapie, TME, and CWD) after an interspecies transmission event. At present, the only available biological method for TSE strain differentiation uses a mouse

Table 2. Severity of spongiform encephalopathy in various areas of CNS of 4 raccoons experimentally inoculated intracerebrally with TME agent.*

Raccoon no.	Cerebral cortex	Thalamus/ hypothalamus	Hippocampus	Brain stem	Cerebellum	Spinal cord		
						Cervical	Thoracic	Lumbar
R1-2	++	+	+	++	−	+	+	+
R3-4	+++	+++	+	++	−	+	+	+
R5-6	+++	++	++	++	−	+	+	+
R7-8	+++	++	+	++	−	+	+	++
R9-10	−	−	−	−	−	−	−	−

* CNS = central nervous system; TME = transmissible mink encephalopathy. − indicates absence of lesions; + presence of mild lesions; ++ presence of moderate lesions; +++ presence of severe lesions.

model. This method is based on the length of incubation period and neuropathological lesion profile in 3–5 strains of specially bred mice.[6] The mouse model requires an average incubation of 800 days (over 2 years), and at this time can only be done at a few TSE laboratories in Europe. In addition to these disadvantages, the mouse model requires large numbers of mice, is expensive, and also, TME cannot be transmitted to mice.[19,26] Therefore, a raccoon model could prove to be a relatively inexpensive and probably a faster method for differentiation of the 3 recognized TSEs in the United States. This would be particularly useful if an unknown TSE were identified, such as occurred in 2000 in milking sheep imported from Belgium to Vermont.[1] Further studies are, however, necessary before the raccoon can be recommended as a biological model for TSE strain differentiation. In this context, experimental intracerebral inoculation of bovine spongiform encephalopathy (BSE) would need to be evaluated in raccoons. Because the BSE agent appears to be more promiscuous than other TSE agents (i.e., easily transmitted to other species such as sheep, wild ungulates, cats, and primates), it may have a shorter incubation period than TME in raccoons. Furthermore, inoculation of other isolates of scrapie, CWD, and TME into raccoons would indicate whether raccoons might be a suitable model for differentiation of agents or strains within the host species.

Acknowledgements

We thank Dr. Jean Laufer for clinical assistance with the raccoons. Expert technical assistance was provided by Martha Church, Dennis Orcutt, Jean Donald, and Jennifer Slovak at NADC, Ames, Iowa, Linda Davis and Donna Barnicle at Veterinary Laboratory Agency, Weybridge, UK, and Amy Lyda and Linda Hamburg at ADRU, Pullman, WA. This study was carried out under the guidelines of the institutional ACUC committee at NADC. Mention of trade names or commercial products in this article is solely for the purpose of providing specific information and does not imply recommendation or endorsement by the U.S. Department of Agriculture.

Sources and manufacturers

a. Premium formula, PMI Nutrition Inc., Brentwood, MO.
b. Ventana Medical Systems, Tucson, AZ.
c. Prionics-Check, Zurich, Switzerland.
d. Q-BioGene, Carlsbad, CA.
e. Invitrogen, Life Technologies, Carlsbad, CA.
f. Amplicon Express, Pullman, WA.

References

1. Balter M: 2000, Hunt for mad cow in sheep reassuring. Science 289:849.
2. Barlow RM, Rennie JC: 1970, Transmission experiments with a scrapie-like encephalopathy of mink. J Comp Pathol 80:75–79.
3. Bartz JC, Bessen RA, McKenzie D, et al.: 2000, Adaptation and selection of prion protein strain conformations following interspecies transmission of transmissible mink encephalopathy. J Virol 74:5542–5547.
4. Bartz JC, McKenzie DI, Bessen RA, et al.: 1994, Transmissible mink encephalopathy species barrier effect between ferret and mink: PrP gene and protein analysis. J Gen Virol 75:2947–2953.
5. Brown P: 2001, Afterthoughts about bovine spongiform encephalopathy and variant Creutzfeldt-Jakob disease. Emerg Infect Dis 7:598–600.
6. Bruce ME, Will RG, Ironside JW, et al.: 1997, Transmission to mice indicate that 'new variant' CJD is caused by the BSE agent. Nature 389:498–501.
7. Cutlip RC, Miller JM, Lehmkuhl HD: 1997, Second passage of a US scrapie agent in cattle. J Comp Pathol 117:271–275.
8. Cutlip RC, Miller JM, Race RE, et al.: 1994, Intracerebral transmission of scrapie to cattle. J Infect Dis 169:814–820.
9. Eckroade RJ: 1972, Neuropathology and experimental transmission to other species of transmissible mink encephalopathy. PhD Thesis, University of Wisconsin, Madison, WI.
10. Eckroade RJ, Zu Rhein GM, Hanson RP: 1973, Transmissible mink encephalopathy in carnivores: clinical, light and electron microscopic studies in raccoons, skunks and ferrets. J Wildl Dis 9:229–240.
11. Eckroade RJ, Zu Rhein GM, Marsh RF, et al.: 1970, Transmissible mink encephalopathy: experimental transmission to the squirrel monkey. Science 169:1088–1090.
12. Hadlow WJ, Race RE, Kennedy RC: 1987, Experimental infection of sheep and goats with transmissible mink encephalopathy virus. Can J Vet Res 51:135–144.
13. Hamir AN, Hanlon C, Rupprecht CE: 2001, Prevalence of mineralized blood vessels (psammoma bodies) in meninges and choroid plexuses of raccoons (*Procyon lotor*) from Parramore Island, Virginia. J Vet Diagn Invest 13:76–79.
14. Hamir AN, Miller JM, Cutlip RC, et al.: 2003, Experimental inoculation of scrapie and chronic wasting disease agents to raccoons (*Procyon lotor*). Vet Rec 153:121–123.
15. Hamir AN, Miller JM, Schmerr MJ, et al.: 2001, Diagnosis of preclinical and subclinical scrapie in a naturally infected sheep flock utilizing currently available postmortem diagnostic techniques. J Vet Diagn Invest 13:152–154.
16. Hamir AN, Miller JM, Stack MJ, et al.: 2002, Intracerebral inoculation of genetically susceptible sheep with scrapie agent: failure to detect abnormal prion protein and scrapie associated fibrils six weeks post inoculation. Can J Vet Res 66:289–294.
17. Hurtung J, Johannsen U, Zimmermann H: 1975, Infektiose enzephalopathie beim nerz 3. Mitt.: ergebnisse weiterer praxiserhebungen und ubertragungsversuche. Monats Vet 30:23–27.
18. Kascsak RJ, Fersko R, Pulgiano D, et al.: 1997, Immunodiagnosis of prion disease. Immunol Invest 26:259–268.
19. Marsh RF, Bessen RA, Lehmann S, Hartsough GR: 1991, Epidemiological and experimental studies on a new incident of transmissible mink encephalopathy. J Gen Virol 72:589–594.
20. Marsh RF, Burger D, Eckroade R, et al.: 1969, A preliminary report on the experimental host range of the transmissible mink encephalopathy agent. J Infect Dis 120:713–719.
21. Miller JM, Jenny AL, Taylor WD, et al.: 1994, Detection of prion protein in formalin-fixed brain by hydrated autoclaving immunohistochemistry for diagnosis of scrapie in sheep. J Vet Diagn Invest 6:366–368.
22. O'Rourke KI, Baszler TV, Besser TE, et al.: 2000, Preclinical diagnosis of scrapie by immunohistochemistry of third eyelid lymphoid tissue. J Clin Microbiol 38:3254–3259.
23. Robinson MM, Hadlow WJ, Knowles DP, et al.: 1995, Experimental infection of cattle with the agents of transmissible mink encephalopathy and scrapie. J Comp Pathol 113:241–251.
24. Schaller O, Fatzer R, Stack MJ, et al.: 1999, Validation of a

Western immunoblotting procedure for bovine PrP^{Sc} detection and its use as a rapid surveillance method for the diagnosis of bovine spongiform encephalopathy (BSE). Acta Neuropathol 98:437–443.

25. Stack MJ, Keyes P, Scott AC: 1996, The diagnosis of bovine spongiform encephalopathy and scrapie by the detection of fibrils and the abnormal protein isoform. *In:* Methods in molecular medicine—prion diseases, ed. Baker HF, Ridley RM, pp. 85–104. Humana Press, Totowa, NJ.
26. Taylor DM, Dickinson AG, Fraser H, et al.: 1986, Evidence that transmissible mink encephalopathy agent is biologically inactive in mice. Neuropathol Appl Neurobiol 12:207–215.