University of Nebraska - Lincoln
DigitalCommons@University of Nebraska - Lincoln

Other Publications in Zoonotics and Wildlife Disease

Wildlife Disease and Zoonotics

1-1-2006

Comparison of two automated immunohistochemical procedures for the diagnosis of scrapie in domestic sheep and chronic wasting disease in North American white-tailed deer (*Odocoileus virginianus*) and mule deer (*Odocoileus hemionus*)

T. V. Baszler
Washington State University

M. Kiupel
Michigan State University

E. S. Williams
University of Wyoming

B. V. Thomsen
U.S. Department of Agriculture

T. Gidlewski
U.S. Department of Agriculture

Baszler, T. V.; Kiupel, M.; Williams, E. S.; Thomsen, B. V.; Gidlewski, T.; Montgomery, D. L.; O'Rourke, Katherine I.; and Hall, S. M., "Comparison of two automated immunohistochemical procedures for the diagnosis of scrapie in domestic sheep and chronic wasting disease in North American white-tailed deer (*Odocoileus virginianus*) and mule deer (*Odocoileus hemionus*)" (2006). *Other Publications in Zoonotics and Wildlife Disease.* Paper 139.
http://digitalcommons.unl.edu/zoonoticspub/139

This Article is brought to you for free and open access by the Wildlife Disease and Zoonotics at DigitalCommons@University of Nebraska - Lincoln. It has been accepted for inclusion in Other Publications in Zoonotics and Wildlife Disease by an authorized administrator of DigitalCommons@University of Nebraska - Lincoln.

See next page for additional authors

Follow this and additional works at: http://digitalcommons.unl.edu/zoonoticspub

Part of the Veterinary Infectious Diseases Commons

Authors
T. V. Baszler, M. Kiupel, E. S. Williams, B. V. Thomsen, T. Gidlewski, D. L. Montgomery, Katherine I. O'Rourke, and S. M. Hall

This article is available at DigitalCommons@University of Nebraska - Lincoln: http://digitalcommons.unl.edu/zoonoticspub/139

J Vet Diagn Invest 18:147–155 (2006)

Comparison of two automated immunohistochemical procedures for the diagnosis of scrapie in domestic sheep and chronic wasting disease in North American white-tailed deer (*Odocoileus virginianus*) and mule deer (*Odocoileus hemionus*)

T. V. Baszler,[1] M. Kiupel, E. S. Williams, B. V. Thomsen, T. Gidlewski, D. L. Montgomery, K. I. O'Rourke, S. M. Hall

Abstract. Two commercially available automated immunohistochemistry platforms, Ventana NexES and DakoCytomation Autostainer Universal Staining System, were compared for diagnosing sheep scrapie and cervid chronic wasting disease. Both automated platforms used the same antiprion protein monoclonal primary antibodies, but different platform-specific linker and amplification reagents and procedures. Duplicate sections of brainstem (at the level of the obex) and lymphoid tissue (retropharyngeal lymph node or tonsil) from the same tissue block were immunostained for the comparison. Examination of 1,020 tissues from 796 sheep revealed 100% concordance of results between the Ventana NexES and DakoCytomation platforms for diagnosing sheep scrapie from lymphoid tissue (103/103 positive; 405/405 negative) and brainstem (120/120 positive; 392/392 negative). Similarly, examination of 1,008 tissues from 504 white-tailed deer revealed 100% concordance between the Ventana NexES and DakoCytomation platforms for diagnosing chronic wasting disease from lymphoid tissue (104/104 positive; 400/400 negative) and brainstem (104/104 positive; 400/400 negative). Examination of 1,152 tissues from 482 mule deer revealed a concordance of 98.6% in lymphoid tissue and 99.9% in brainstem between the Ventana NexES and DakoCytomation platforms for diagnosing chronic wasting disease. The results indicate equivalence or near equivalence between the DakoCytomation and Ventana NexES autostainer platforms for identification of the disease-associated prion protein (PrP^d)-positive and PrP^d-negative brain and lymphoid tissues in sheep, white-tailed deer, and mule deer.

Key words: Scrapie; chronic wasting disease; prion; immunohistochemistry.

Introduction

Sheep scrapie and cervid chronic wasting disease (CWD) are prion diseases of animals, transmissible spongiform encephalopathies (TSEs), characterized by spongiform lesions in the brain and the accumulation of an abnormal isoform of host-encoded prion protein (PrP).[9,20] The accurate diagnosis of TSEs relies on a combination of clinical signs of disease, microscopic examination of the brain, and demonstration of the insoluble, protease-resistant, disease-associated form of host prion protein (PrP^d). Demonstrating the accumulation of PrP^d in affected animals has become routine for confirmatory diagnosis and surveillance of animal TSEs, mainly because disease can exist in the absence of either clinical signs of disease or spongiform lesions,[2,5] and detecting PrP^d in lymphoid tissues can provide accurate antemortem diagnosis of scrapie and CWD during preclinical disease.[2,10,13,19] Methods for PrP^d detection include immunohistochemical (IHC) analysis, immunoblotting, and enzyme-linked immunosorbent assay (ELISA).[1,3,7] In most diagnostic laboratory settings, IHC analysis has advantages over immunoblotting or ELISA because: 1) sampling methods are routine for histologic examination (formalin-fixed tissue), 2) histologic lesions can be spatially correlated with PrP^d accumulation,[9,16] 3) the distribution pattern of PrP^d can be identified (disease phenotype),[4,15,17] 4) depending on specific procedures, IHC analysis may be more sensitive than immunoblotting,[6] and

From the Washington Animal Disease Diagnostic Laboratory and Department of Veterinary Microbiology and Pathology, College of Veterinary Medicine, Washington State University, Pullman, WA (Baszler); and the Department of Veterinary Pathobiology and Diagnostic Investigation, College of Veterinary Medicine, Michigan State University, East Lansing, MI (Kiupel); Department of Veterinary Sciences, College of Agriculture, University of Wyoming, Laramie, WY (Williams); Texas Veterinary Medical Diagnostic Laboratory, Amarillo, TX (Montgomery); National Veterinary Services Laboratories, US Department of Agriculture, Animal and Plant Health Inspection Service, Ames, IA (Gidlewski, Hall, Thomsen); and Agricultural Research Service, US Department of Agriculture, Animal Disease Research Unit, Pullman, WA (O'Rourke). Current address (Montgomery): Department of Veterinary Sciences, College of Agriculture, University of Wyoming, Laramie, WY. E. S. Williams is deceased.

[1]Corresponding Author: Tim Baszler, Washington Animal Disease Diagnostic Laboratory, Washington State University, PO Box 2037 College Station, Pullman, WA 99165-2037l; e-mail: baszlert@vetmed.wsu.edu

This article is a U.S. government work, and is not subject to copyright in the United States.

5) automated IHC equipment and procedures are readily available, fast, and simple.

Several manual and automated immunohistochemical methods have been successfully applied to detect PrP^d for the diagnosis of sheep scrapie and cervid CWD. Most techniques include steps to differentiate PrP^d from normal prion protein in host cells (PrP^C),[4] epitope unmasking (usually by use of heat-induced antigen retrieval),[8,15] and use of antibodies identifying conserved PrP epitopes.[10,11,14] Scrapie testing and CWD IHC analysis carried out by the Veterinary Services of the United States Department of Agriculture (USDA), and Animal and Plant Health Inspection Service (APHIS) or its contract laboratories is largely performed by use of the Ventana NexES[a] autostainer with proprietary immunostaining reagents. Results of a recent survey by the American Association of Veterinary Laboratory Diagnosticians indicated that many diagnostic laboratories have proprietary automated immunostainers other than the Ventana NexES; the DakoCytomation Autostainer Universal Staining System[b] was the most common of those.[12] Because different IHC reagents and procedures can affect the outcome of immunoreactivity, equivalency testing was carried out, using the same previously validated anti-PrP monoclonal antibodies, between the Ventana NexES platform and the DakoCytomation Autostainer Universal Staining System for diagnosing sheep scrapie and cervid CWD. Testing of brain and lymphoid tissues from 1,300 sheep and white-tailed deer revealed near 100% concordance between the 2 automated immunostaining platforms. Equivalency between the platforms was slightly less in 500 mule deer tested for CWD.

Materials and methods

Animal tissues

Scrapie. Sheep of the study originated from privately owned flocks located in 30 states representing all major geographic regions of the United States. The sheep were identified for the National Scrapie Eradication Program because they were index scrapie cases (based on presence of clinical neurologic disease and pathologic changes), positive flock depopulations, trace-backs from positive flocks, or slaughter surveillance. Sheep age ranged from 1 to 9 years. Breed identifications included Suffolk, Hampshire, cross-breed, white face, black face, and mottled face. A total of 1,020 brain or lymphoid tissues were obtained from 796 sheep (Table 1). Lymphoid tissues collected and examined (508 samples) included either tonsil or retropharyngeal lymph node. Brain samples collected and examined for the purposes of the study (512 samples) included the brainstem at the level of the obex (containing the dorsal motor nucleus of the vagus nerve). The lymphoid and brain sample sets contained good- and poor-quality (autolyzed or frozen then thawed) tissue specimens. Ventana NexES[a] immunostaining was performed at the National Veterinary Services Laboratories in Ames, IA and USDA, Animal Disease Research Unit in Pullman, WA. DakoCytomation[b] immunostaining was performed at the Washington Animal Disease Diagnostic Laboratory at Washington State University.

Table 1. Number of animals and tissues tested for scrapie or chronic wasting disease (CWD) by immunohistochemistry using the Ventana NexES Autostainer System and the DakoCytomation Autostainer Universal Staining System.

	Sheep	White-tailed deer	Mule deer
No. of animals tested	796	504	482
Lymphoid tissue	508	504	670
Brain	512	504	482
Total tissues tested	1020	1008	1152

Chronic wasting disease. Tissues for CWD testing were obtained from captive and free-ranging cervids (white-tailed deer, and mule deer). Samples from free-ranging cervids were obtained during hunter-kill CWD surveillance programs in Wisconsin, Michigan, Nebraska, Wyoming, and Colorado. Samples from captive cervids were obtained from privately owned cervid farms as part of CWD surveillance programs. A total of 2,160 brain or lymphoid tissues were obtained from 986 cervids. Lymphoid tissues collected and examined (1,174 samples) included either tonsil or retropharyngeal lymph node. Brain collected and examined for the purposes of the study (986 samples) included the brainstem at the level of the obex (containing the dorsal motor nucleus of the vagus nerve). The lymphoid and brain sample sets contained good- and poor-quality (autolyzed or frozen then thawed) tissue specimens. Ventana NexES[a] immunostaining was performed at the National Veterinary Services Laboratories in Ames, IA and the USDA Animal Disease Research Unit in Pullman, WA. DakoCytomation[b] immunostaining for white-tailed deer and mule deer was performed at the Department of Veterinary Pathobiology and Diagnostic Investigation at Michigan State University, and at the Department of Veterinary Sciences, University of Wyoming respectively.

Immunohistochemical methods

DakoCytomation autostainer universal staining system. Pretreatment prior to IHC analyis for PrP^d was performed using heat-induced antigen retrieval and formic acid as described.[10,15] Prior to paraffin embedding, lymphoid tissue was placed en bloc in 96% formic acid for 60 minutes, rinsed in distilled water, and returned to neutral-buffered 10% formalin. Sections were deparaffinized in xylene and graded ethanols, incubated 5 minutes with 96% formic acid, and rinsed in Tris-buffered saline (TBS; 0.05 M Tris-HCl, 0.15 M NaCl, pH 7.6) to neutralize acidity. Heat-induced antigen retrieval consisted of heating sections to 121°C for 20 minutes at 15 to 20 pounds per square inch in modified citrate buffer (Target Retrieval Solution, pH 6.1[b]) using either a standard tabletop autoclave or commercially available decloaking device.[c]

After antigen retrieval, all incubations were performed at room temperature. Blocking steps included incubation for 15 minutes with 3% H_2O_2 in methanol to block endogenous peroxidase, and in Serum-free Protein Block[b] for 5 minutes. Critical immunostaining steps associated with the autostainer included incubation of sections with anti-PrP primary antibody, biotinylated linker antibody, detection reagent, and chromogen, interceded by washes with IHC buffer (TBS containing 0.2% Tween 20[b]). Anti-PrP primary antibodies consisted of F89.160.1.5[d] (F89), a monoclonal antibody to ruminant PrP targeting a conserved epitope at residues 142–145 and validated for diagnosis of scrapie,[10,11] and F99.97.6.1[d] (F99), a monoclonal antibody to ruminant PrP targeting a conserved epitope at residues 200–225 and validated for diagnosis of scrapie and CWD.[10,14] For scrapie assays (because of rare variation in the F89 epitope in some sheep breeds[10]), a cocktail containing 3.4 μg each of F89 and F99/ml was incubated on tissue sections for 10 minutes; F99 alone at concentration of 3.4 μg/ml for a 10-minute incubation was used for CWD assays. Biotinylated goat antimouse/rabbit IgG linker reagent,[b] horse radish perioxidase-conjugated strepavidin-biotin complex detection reagent (LSAB-HRP Tertiary Reagent[b]), and 3-amino-9-ethyl-carbazole (AEC) chromogen[b] were incubated on sections for 10 minutes each. After AEC incubation, sections were rinsed with deionized water and counterstained manually with Mayer's hematoxylin[b]; then coverslips were mounted by use of aqueous mounting medium, and slides were examined by light microscopy.

Positive-control tissue, consisting of brain or lymph node from a known scrapie-positive sheep or CWD-positive deer, was included in each run to confirm immunoreactivity of the appropriate pattern and intensity in lymphoid follicle germinal centers and in the neuropil of the brain.[11,15] Negative antibody control, consisting of either Universal negative mouse serum[b] (DakoCytomation) or an irrelevant isotype-matched primary antibody (anti-*Neospora caninum* mAb Nc-5B6-25, 3.4 μg/ml[d]) reacted with each test slide to ensure the lack of non-specific binding by linker or signal amplification reagents to tissue sections. Results for test slides were classified as positive or negative for PrP^d. Slides classified as PrP^d positive had immunoreactivity in a pattern consistent with that of positive-control slides and of that in previous publications.[10,11,17,18] Slides classified as PrP^d negative did not have specific immunoreactivity. Only optimal sections were classified; if a sectioning artifact such as detached sections was seen, the sections were recut and tested again.

Ventana NexES. Pretreatment antigen retrieval, antiprion primary antibodies, and positive and negative controls for Ventana NexES IHC were identical to the aforementioned procedures used for the DakoCytomation Autostainer.

For automated immunostaining on the Ventana NexES platform, all incubations were performed at 37°C using the AEC Detection System[a] according to manufacturer's recommendations. Critical immunostaining steps associated with the autostainer included incubation of sections with inhibitor (to block nonspecific binding), anti-PrP primary antibody, biotinylated linker antibody, detection reagent, chromogen, counterstain, and bluing reagent, interceded by washes with IHC buffer. Anti-PrP primary antibodies, F99 for CWD and F89 plus F99 for scrapie, were the same as those used for the Dako autostainer, but antibody concentration was 5 μg/ml. Primary antibodies were diluted in proprietary antibody diluent,[a] incubation time was 32 minutes, and incubation temperature was 37°C. Biotinylated linker reagent (consisting of biotinylated goat antimouse IgG,[a] detection reagent (consisting of horse radish perioxidase-labeled strepavidin-biotin complex[a]), Enhancer reagent,[a] and AEC chromogen[a] were each incubated on sections for 8 minutes. Sections were counterstained with Gill's hematoxylin[a] and bluing reagent,[a] then coverslips were mounted with aqueous mounting medium. Results for test slides were classified as positive or negative for PrP,[a] as described previously for slides stained by the DakoCytomation platform. Positive slides had immunoreactivity in a pattern consistent with that of positive-control slides and previous publications.[14,15] Only optimal sections were classified; if sectioning artifact such as de-attached sections was seen, the sections were recut and tested again.

Immunohistochemical comparative analysis. Scrapie and CWD IHC testing of all samples was initially completed using the Ventana NexES, the standard protocol used at the National Veterinary Services Laboratories (NVSL) by 3 of the authors (BVT, TG, SMH). A random subset of negative and positive samples (glass slides or paraffin blocks) of brain and lymphoid tissue from sheep, white-tailed deer, and mule deer (Table 1) were sent to authors at participating diagnostic laboratories (Michigan State University [MK], Washington State University [TVB], and University of Wyoming [ESW] for subsequent equivalency testing using the DakoCytomation Autostainer Universal Staining System[b]). The participating laboratories were blinded to the disease status of the tissue specimens and used identical immunostaining procedures (as described previously) for scrapie and CWD testing with the DakoCytomation Autostainer Universal Staining System.[b]

Results of scrapie and CWD testing using the DakoCytomation Autostainer Universal Staining System,[b] were forwarded to the authors at USDA-NVSL in Ames, IA (BVT, TG, SMH) or USDA-ARS-ARU in Pullman, WA (KIO) for comparison of test results with those of the Ventana NexES.[a] Discordant results were retested using a "sandwich" technique to verify or resolve differences. The sandwich technique consists of immunostaining 3 consecutive serial sections from the paraffin blocks of the specimens of interest. The first and third sections were immunostained using Ventana NexES, and the second (sandwich) section was immunostained using the DakoCytomation Autostainer. The sandwich technique was necessary to avoid false discordant results due to sectioning artifact between initial testing with the Ventana NexES and subsequent testing with the DakoCytomation Autostainer, which occurred months later and after paraffin blocks were sealed, requiring "refacing" of the paraffin blocks. Indeed, it is possible that sectioning through a small immunoreactive focus in the obex or lymph node of a weakly positive

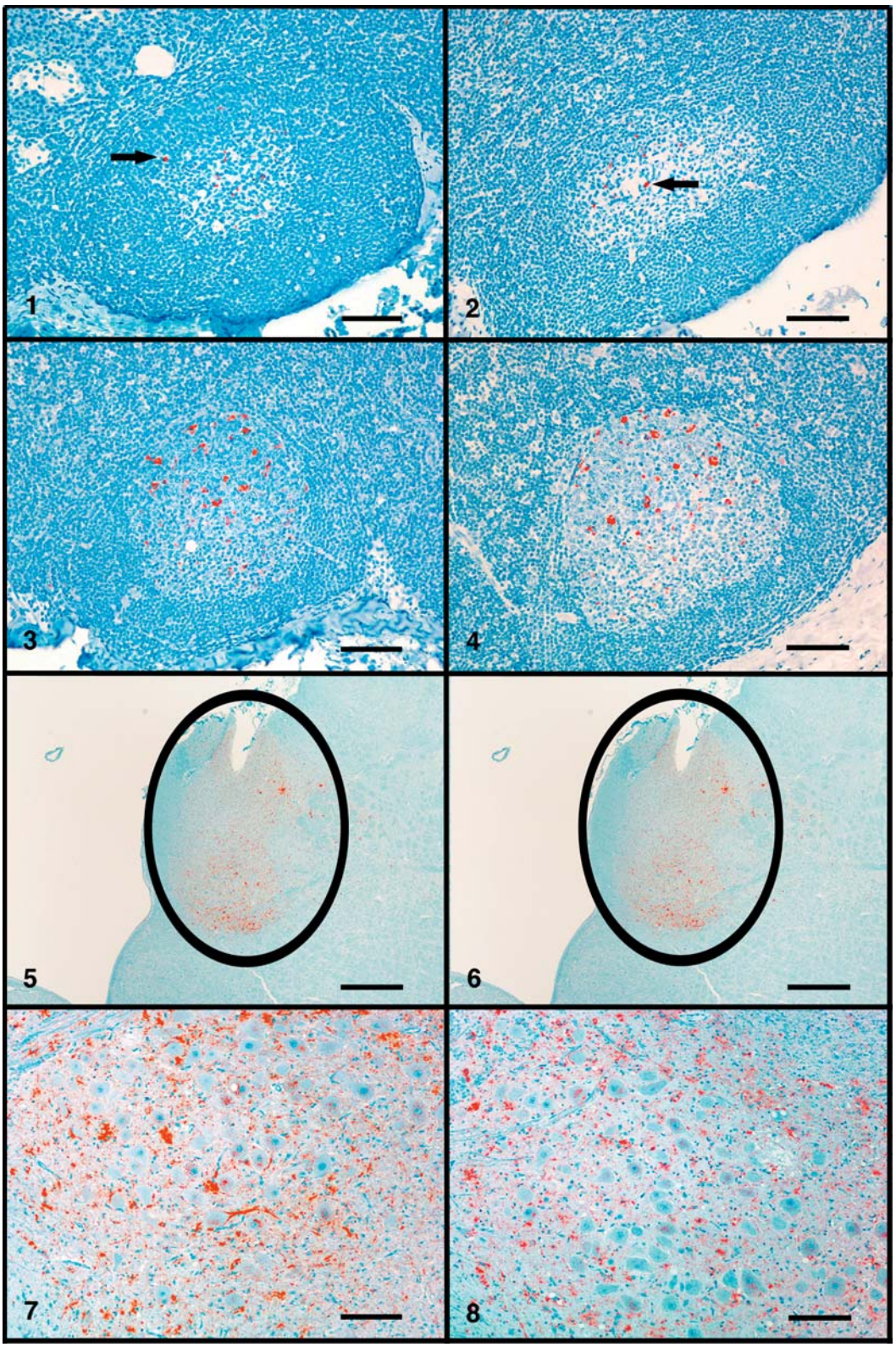

Figure 1. Retropharyngeal lymph node; sheep No. 1. Minimal multifocal granular immunoreactivity with anti-prion monoclonal antibody (MAb) cocktail in cells of the germinal center (arrow). Ventana NexES IHC system. 3-Amino-9-ethyl-carbazole (AEC) chromogen (red). Gill's hematoxylin counterstain. Bar = 90 μm.

Figure 2. Retropharyngeal lymph node; sheep No. 1. Minimal multifocal granular immunoreactivity with anti-prion MAb cocktail in cells of the same serially sectioned germinal center as that in Figure 1 (arrow). DakoCytomation IHC system. AEC

sample could be interpreted as positive results on initial testing and negative results on later testing. After initial testing and retesting of discordant samples, comparisons of results were tabulated as percentage concordance or percentage discordance between the immunostaining platforms for all species tested.

A random subset of 104 CWD-positive lymph nodes and 84 CWD-positive brains from white-tailed deer were numerically classified to estimate semi-quantitative immunostaining differences between the Ventana and DakoCytomation platforms. The examiner (TG) was blinded to the status of each slide. Because the number of total follicles per section varied much between individual animals examined, lymph nodes were classified semi-quantitatively as: 1) minimal immunoreactivity in only a few follicles; 2) obvious immunoreactivity, but only in a few follicles; 3) obvious immunoreactivity in a moderate number of follicles; 4) obvious and sometimes intense immunoreactivity in many follicles; and 5) intense immunoreactivity in nearly all follicles. Brainstems were classified as described,[15] namely: 1) partial immunoreactivity in the dorsal motor nucleus of the vagus nerve; 2) total immunoreactivity of the dorsal motor nucleus of the vagus nerve; 3) immunoreactivity extending from the dorsal motor nucleus of the vagus nerve into the immediately adjacent neuropil; 4) moderate immunoreactivity throughout entire brainstem section; and 5) intense immunoreactivity throughout entire brainstem section.

Table 2. Comparison of scrapie and CWD immunohistochemistry results using the Ventana NexES Autostainer System and the DakoCytomation Autostainer Universal Staining System.

Animal	Tissue (status)	Ventana NexES	DakoCytomation
Sheep	Lymphoid (positive)*	103	103
	Lymphoid (negative)†	405	405
	Brain (positive)‡	120	120
	Brain (negative)§	392	392
White-tailed deer	Lymphoid (positive)*	104	104
	Lymphoid (negative)†	400	400
	Brain (positive)‡	104	104
	Brain (negative)§	400	400
Mule deer	Lymphoid (positive)*	171	167
	Lymphoid (negative)†	499	503
	Brain (positive)‡	102	101
	Brain (negative)§	380	381

* Lymphoid positive: PrPSc immunoreactivity in at least 1 germinal center.

† Lymphoid negative: no PrPSc immunoreactivity in any germinal center (at least 10 present in sample).

‡ Brain positive: PrPSc immunoreactivity at least in dorsal motor nucleus of the vagus nerve.

§ Brain negative: no PrPSc immunoreactivity (dorsal motor nucleus of vagus nerve present in sample).

Results

Sheep scrapie

A total of 1,020 tissues from 796 sheep were examined by use of prion IHC analysis with the Ventana NexES and DakoCytomation immunostaining platforms (Table 1). Of the 508 lymphoid tissues examined (tonsil or retropharyngeal lymph node), 103 were IHC positive and 405 were IHC negative by both the Ventana NexES and DakoCytomation platforms (Table 2). Of the 512 brainstems (obex) examined, 120 were IHC positive and 392 were IHC negative by both the Ventana NexES and DakoCytomation platforms (Table 2). Initial examination identified 5 discordant samples (4 brainstem and 1 lymph node), which on re-testing using the aforementioned serial section sandwich technique, indicated concordant results between the 2 platforms. All samples initially discordant were tissues that had weak, focal immunoreactivity on initial testing using the Ventana NexES platform and were IHC negative

←

chromogen (red). Mayer's hematoxylin counterstain. Bar = 90 μm.

Figure 3. Retropharyngeal lymph node; sheep No. 2. Moderate asymmetric granular immunoreactivity with anti-prion MAb cocktail in cells of the germinal center. Ventana NexES IHC system. AEC chromogen (red). Gills's hematoxylin counterstain. Bar = 90 μm.

Figure 4. Retropharyngeal lymph node; sheep No. 2. Moderate asymmetric granular immunoreactivity with antiprion MAb cocktail in cells of the same serially sectioned germinal center as that in Figure 3. DakoCytomation IHC system. AEC chromogen (red). Mayer's hematoxylin counterstain. Bar = 90 μm.

Figure 5. Brainstem (obex); sheep No. 3. Immunoreactivity with anti prion MAb cocktail in the dorsal motor nucleus of the vagus nerve (oval). Ventana NexES IHC system. AEC chromogen (red). Gill's hematoxylin counterstain. Bar = 800 μm.

Figure 6. Brainstem (obex); sheep No. 3. Immunoreactivity with antiprion MAb cocktail in a serial section of the same dorsal motor nucleus of the vagus nerve as that in Figure 5 (oval). DakoCytomation IHC system. AEC chromogen (red). Mayer's hematoxylin counterstain. Bar = 800 μm.

Figure 7. Brainstem (obex); sheep No. 3. Higher magnification of Figure 5. Ventana NexES IHC system. AEC chromogen (red). Gill's hematoxylin counterstain. Bar = 160 μm.

Figure 8. Brainstem (obex); sheep No. 3. Higher magnification of Figure 6. DakoCytomation IHC system. AEC chromogen (red). Mayer's hematoxylin counterstain. Bar = 160 μm.

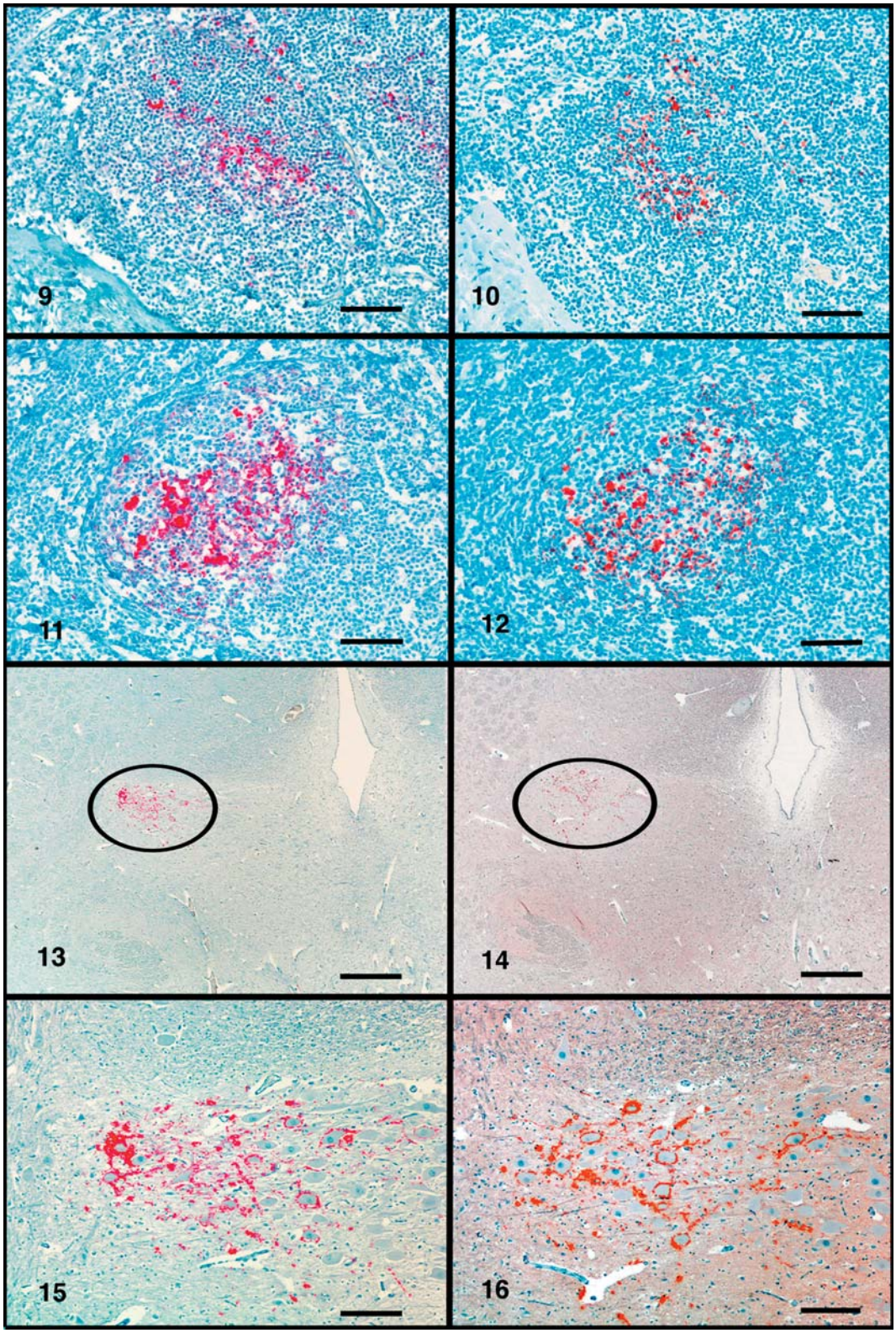

Figure 9. Retropharyngeal lymph node; white-tailed deer No. 1. Moderate multifocal granular immunoreactivity with antiprion MAb in cells of the germinal center. Ventana NexES IHC system. AEC chromogen (red). Gill's hematoxylin counterstain. Bar = 110 μm.

Figure 10. Retropharyngeal lymph node; white-tailed deer No. 1. Moderate multifocal granular immunoreactivity with antiprion MAb in cells of the same serially sectioned germinal center as that in Figure 9. DakoCytomation IHC system. AEC chromogen (red).

using the DakoCytomation platform, which was performed at a later date after the paraffin blocks were resealed. On re-testing using serial sections, the tissues were IHC negative by use of both platforms. Thus, there was 100% concordance between the Ventana NexES and DakoCytomation immunostaining platforms in identifying PrP^d-positive or PrP^d-negative brain and lymphoid tissues in sheep.

Overall, the quality of prion immunoreactivity was equivalent between the Ventana NexES and DakoCytomation immunostaining platforms (Figs. 1–8). In lymphoid tissue, immunoreactivity was granular and multifocal in germinal centers, a pattern consistent with PrP^{Sc} accumulation in lymphoid tissue (Figs. 1–4).[10,17] Use of both platforms identified weakly positive germinal centers, although the signal intensity was slightly stronger for the Ventana NexES platform (Figs. 1, 2). In brain tissue, the signal-to-noise ratio was slightly higher in the Ventana NexES, compared with the DakoCytomation platform (Figs. 5–8). However, use of both platforms yielded an immunoreactivity pattern typical of PrP^d in sheep with scrapie (i.e., plaques, cellular processes, perineuronal rims, and perivascular accumulations,[11,18] and both platforms identified sheep early in disease, with PrP^d immunoreactivity restricted to focal regions of the dorsal motor nucleus of the vagus nerve (Figs. 5, 6).

Chronic wasting disease in white-tailed deer

A total of 1,008 tissues from 504 white-tailed deer were examined by use of prion IHC analysis with the Ventana NexES and DakoCytomation immunostaining platforms (Table 1). Of the 504 lymphoid tissues examined (tonsil or retropharyngeal lymph node), 104 were IHC positive and 400 were IHC negative by both platforms (Table 2). Of the 504 brainstems (obex) examined, 104 were IHC positive and 400 were IHC negative by both platforms (Table 2). Thus, there was 100% concordance between the Ventana NexES and DakoCytomation immunostaining platforms in identifying PrP^d-positive or PrP^d-negative brain and lymphoid tissues in white-tailed deer.

There were no obvious semiquantitative differences in immunoreactivity between the Ventana NexES and DakoCytomation platforms using the aforementioned 1–5 numerical grading system to classify a random subset of 104 CWD-positive lymph nodes and 84 CWD- positive brainstems. Numbers of lymph node specimens classified within each numerical grade were: grade 1 = 13, grade 2 = 28, grade 3 = 34, grade 4 = 29, and grade 5 = 0. Numbers of brainstem samples classified within each numerical grade were: grade 1 = 18, grade 2 = 22, grade 3 = 25, grade 4 = 15, and grade 5 = 4. The majority of brainstems (86%; 72/84) were classified identically between the 2 immunostaining platforms. Similarly, most lymph nodes (90%; 94/104) were classified identically between the 2 immunostaining platforms. The lymph nodes and brainstems classified differently for intensity of immunoreactivity varied by only 1 numerical category (i.e., 4 vs. 5 or 1 vs. 2). Neither platform had consistently higher scoring than the other.

Overall, the quality of prion immunoreactivity was equivalent between the 2 immunostaining platforms (Figs. 9–16). In lymphoid tissue, immunoreactivity was granular and multifocal in germinal centers, a pattern consistent with PrP^d accumulation in lymphoid tissue (Figs. 9–12).[14] Both platforms identified weakly positive germinal centers, although the signal intensity was slightly stronger for the Ventana platform (Figs. 9, 10). In brain tissue, the signal-to-noise ratio was slightly higher for the Ventana, compared with the DakoCytomation platform (Figs. 13–16). However, use of both platforms yielded an immunoreactivity pattern typical of PrP^d in

←

Mayer's hematoxylin counterstain. Bar = 110 μm.

Figure 11. Retropharyngeal lymph node; white-tailed deer No. 2. Moderate asymmetric granular immunoreactivity with antiprion MAb in cells of the germinal center. Ventana NexES IHC system. AEC chromogen (red). Gill's hematoxylin counterstain. Bar = 90 μm.

Figure 12. Retropharyngeal lymph node; white-tailed deer No. 2. Moderate asymmetric granular immunoreactivity with antiprion MAb in cells of the same serially sectioned germinal center as that in Figure 11. DakoCytomation IHC system. AEC chromogen (red). Mayer's hematoxylin counterstain. Bar = 90 μm.

Figure 13. Brainstem (obex); white-tailed deer No. 3. Immunoreactivity with antiprion MAb cocktail in the dorsolateral region of the dorsal motor nucleus of the vagus nerve (oval). Ventana NexES IHC system. AEC chromogen (red). Gill's hematoxylin counterstain. Bar = 600 μm.

Figure 14. Brainstem (obex); white-tailed deer No. 3. Immunoreactivity with antiprion MAb cocktail in a serial section of the same dorsal motor nucleus of the vagus nerve as that in Figure 13 (oval). DakoCytomation IHC system. AEC chromogen (red). Mayer's hematoxylin counterstain. Bar = 600 μm.

Figure 15. Brainstem (obex); white-tailed deer No. 3. Higher magnification of Figure 13. Ventana NexES IHC system. AEC chromogen (red). Gill's hematoxylin counterstain. Bar = 190 μm.

Figure 16. Brainstem (obex); white-tailed deer No. 3. Higher magnification of Figure 14. DakoCytomation IHC system. AEC chromogen (red). Mayer's hematoxylin counterstain. Bar = 190 μm.

deer with CWD (i.e., plaques, cellular processes, perineuronal rims, and perivascular accumulations (Figs. 15, 16),[11,18] and use of both platforms identified deer early in disease, with PrP^d immunoreactivity restricted to the dorsal motor nucleus of the vagus nerve (Figs. 13, 14).

There was slightly more nonspecific background reactivity in the deer tissues tested for CWD than in the sheep tissues tested for scrapie. Some deer tissues stained by use of the Ventana NexES platform had fine diffuse reactivity of the neuropil and intracytoplasmic reactivity of lymphocytes in lymph nodes. Some deer tissues stained by use of the DakoCytomation platform had intraneuronal reactivity in the brain, and in lymph nodes, accentuation of germinal centers with orange brown reactivity was apparent. However, the increased background visualized in some deer tissues did not affect classification of tissues as CWD positive or CWD negative.

Chronic wasting disease in mule deer

A total of 1,152 tissues from 482 mule deer were examined by use of prion IHC analysis with the Ventana NexES and DakoCytomation immunostaining platforms (Table 1). Similar to tissues from white-tailed deer tested for CWD, the quality of prion immunoreactivity was equivalent between the 2 immunostaining platforms (data not shown). Of the 670 lymphoid tissues examined (tonsil or retropharyngeal lymph node), 171 were IHC positive and 499 were IHC negative by use of the Ventana NexES platform, and 167 were IHC positive and 503 were IHC negative by use of the DakoCytomation platform (Table 2), calculating to a 98.8% overall concordance ([662/670] $\times$ 100). Of the 482 brainstems (obex), examined, 102 were IHC positive and 380 were IHC negative by use of the Ventana NexES platform, and 101 were IHC positive and 381 were IHC negative by use of the DakoCytomation platform (Table 2), calculating to a 99.6% overall concordance ([480/482] $\times$ 100). For all of the discordant samples, the DakoCytomation results were repeatable in the individual testing laboratory of one of the authors (ESW). However, due to logistical problems retrieving archived tissue blocks, the discordant results were not retested by both the DakoCytomation and Ventana NexES systems using the aforementioned sandwich technique. All discordant samples were PrP^d positive using the Ventana NexES platform and were PrP^d negative using the DakoCytomation Universal platform. Thus, in total, there was slightly less concordance between the Ventana NexES and DakoCytomation immunostaining platforms in identifying PrP^d-positive or PrP^d-negative brain and lymphoid tissues in mule deer.

Discussion

Comparative testing of 2 automated immunostaining platforms, Ventana NexES[a] Autostainer System and DakoCytomation Autostainer Universal Staining System,[b] revealed 100% concordance in correctly classifying scrapie-positive and scrapie-negative sheep, and CWD-positive and CWD-negative white-tailed deer. Concordance was slightly <100% for mule deer with CWD. Use of both immunostaining systems produced sections that were easily interpreted and readily classified as PrP^d positive or PrP^d negative. The comparative testing was done in 5 laboratories, state and federal, carried out by different technical personnel, and interpreted by different pathologists at the respective institutions. The results illustrate the reliability of either immunostaining platform to detect scrapie and CWD, and endorse the official use of both platforms in laboratories approved for TSE testing.

The reason for the minimal discordance between the Ventana NexES and DakoCytomation immunostaining platforms (1.2% for lymphoid tissue and 0.4% for brainstem) when classifying tissues as PrP^d positive or PrP^d negative from mule deer with suspected CWD was not clearly evident from the study. It is possible the Ventana NexES immunostaining platform was more sensitive with this subset of tissue, perhaps due to the higher primary antibody concentration used in the assay (5 μg/ml), compared with that of the DakoCytomation platform (3.4 μg/ml). However, the authors cannot differentiate with certainty whether the Ventana NexES was more sensitive or less specific than the DakoCytomation platform (all the discordant samples were positive using the Ventana NexES platform and were negative using the DakoCytomation platform). Since the discordant mule deer samples could not be retested using the "sandwich" technique (because archived blocks could not be retrieved), it is possible that a small focus of immunoreactivity that was identified using the Ventana NexES platform on initial screening was no longer present in the block when sections were made for testing by the DakoCytomation platform. It is possible there was no discordance at all between the 2 systems in diagnosing CWD in the mule deer samples tested. Finally, since all samples were formalin fixed, it was not possible to further verify the status of the samples in question by using other detection methods such as Western blotting or ELISA.

The slight qualitative differences in prion immunoreactivity between the Ventana NexES[a] and DakoCytomation[b] autostainers could be a matter of personal preference or due to methodologic differ-

ences. For example, the proprietary AEC chromogen and hematoxylin counterstain of the Ventana NexES platform produced a slightly magenta-red signal against an aqua-blue counterstain, compared with the red-brown AEC and darker blue hematoxylin of the DakoCytomation platform. Also, the apparent increased signal strength in the Ventana NexES platform could have been due to the higher concentration and incubation time of the primary antiprion monoclonal antibodies (5 μg/ml for 32 minutes at 37°C), compared with those of the DakoCytomation platform (3.4 μg/ml for 10 minutes at ambient temperature). Regardless of these technical differences, the end result, prion immunoreactivity, did not significantly vary sufficiently to incorrectly classify a given tissue regarding TSE status. Furthermore, the equal performance of the DakoCytomation and Ventana NexES platforms in semi-quantitative grading classification, even for samples with minimal PrP^d immunoreactivity, strengthens the conclusion that both systems perform similarly.

Acknowledgements

The authors wish to acknowledge the excellent technical assistance provided by technical staff at Michigan State University Diagnostic Center for Population and Animal Health, University of Wyoming Department of Veterinary Science, and USDA/APHIS/NVSL, Pam Robertson at the Washington Animal Disease Diagnostic Laboratory, and Tom Truscott at USDA/ARS/ADRU Pullman, WA.

Sources and manufacturers

a. Ventana Medical Systems, Tucson, AZ.
b. DakyCytomation Inc., Carpinteria, CA.
c. BioCare Medical, Walnut Creek, CA.
d. VMRD Inc., Pullman, WA.

References

1. Bennion BJ, Daggett V: 2002, Protein conformation and diagnostic tests: the prion protein. Clin Chem 48:2105–2114.
2. Bradley R: 1997, Animal prion diseases. *In:* Prion diseases, ed. Collinge J, Palmer MS, pp. 89–129. Oxford University Press, Oxford, UK.
3. Farquhar CF, Somerville RA, Ritchie LA: 1989, Post-mortem immunodiagnosis of scrapie and bovine spongiform encephalopathy. J Virol Methods 24:215–221.
4. Foster JD, Wilson M, Hunter N: 1996, Immunolocalisation of prion protein (PrP) in the brains of sheep with scrapie. Vet Rec 139:512–515.
5. Fraser H: 1976, The pathology of natural and experimental scrapie. *In:* Slow virus diseases of animals and man, ed. Kimberlin RH, pp. 276–305. North-Holland, Amsterdam, The Netherlands.
6. Herrmann LM, Baszler TV, Knowles DP, Cheevers WP: 2002, PrP(Sc) is not detected in peripheral blood leukocytes of scrapie-infected sheep: determining the limit of sensitivity by immunohistochemistry. Clin Diagn Lab Immunol 9:499–502.
7. Ingrosso L, Vetrugno V, Cardone F, Pocchiari M: 2002, Molecular diagnostics of transmissible spongiform encephalopathies. Trends Mol Med 8:273–280.
8. Miller J, Jenny A, Taylor W, et al.: 1994, Detection of prion protein in formalin-fixed brain by hydrated autoclaving immunohistochemistry for the diagnosis of scrapie in sheep. J Vet Diag Invest 6:366–368.
9. O'Rourke KI: 2001, Ovine scrapie. New tools for control of an old disease. Vet Clin North Am Food Anim Pract 17:283–300, vi.
10. O'Rourke KI, Baszler TV, Besser TE, et al.: 2000, Preclinical diagnosis of scrapie by immunohistochemistry of third eyelid lymphoid tissue. J Clin Microbiol 38:3254–3259.
11. O'Rourke KI, Baszler TV, Miller JM, et al.: 1998, Monoclonal antibody F89/160.1.5 defines a conserved epitope on the ruminant prion protein. J Clin Microbiol 36:1750–1755.
12. Ramos-Vara JA, Kiupel M, Miller MA: 2005, Immunohistochemical testing in veterinary diagnostic laboratories: results of a survey of 47 laboratories. J Histotechnol 28:19–23.
13. Schreuder BE, van Keulen LJ, Vromans ME, et al.: 1998, Tonsillar biopsy and PrPSc detection in the preclinical diagnosis of scrapie. Vet Rec 142:564–568.
14. Spraker TR, O'Rourke KI, Balachandran A, et al.: 2002, Validation of monoclonal antibody F99/97.6.1 for immunohistochemical staining of brain and tonsil in mule deer (*Odocoileus hemionus*) with chronic wasting disease. J Vet Diagn Invest 14:3–7.
15. Spraker TR, Zink RR, Cummings BA, et al.: 2002, Distribution of protease-resistant prion protein and spongiform encephalopathy in free-ranging mule deer (*Odocoileus hemionus*) with chronic wasting disease. Vet Pathol 39:546–556.
16. Spraker TR, Zink RR, Cummings BA, et al.: 2002, Comparison of histological lesions and immunohistochemical staining of proteinase-resistant prion protein in a naturally occurring spongiform encephalopathy of free-ranging mule deer (*Odocoileus hemionus*) with those of chronic wasting disease of captive mule deer. Vet Pathol 39:110–119.
17. van Keulen LJ, Schreuder BE, Meloen RH, et al.: 1995, Immunohistochemical detection and localization of prion protein in brain tissue of sheep with natural scrapie. Vet Pathol 32:299–308.
18. van Keulen LJ, Schreuder BE, Meloen RH, et al.: 1996, Immunohistochemical detection of prion protein in lymphoid tissues of sheep with natural scrapie. J Clin Microbiol 34:1228–1231.
19. Wild MA, Spraker TR, Sigurdson CJ, et al.: 2002, Preclinical diagnosis of chronic wasting disease in captive mule deer (*Odocoileus hemionus*) and white-tailed deer (*Odocoileus virginianus*) using tonsillar biopsy. J Gen Virol 83:2629–2634.
20. Williams ES, Miller MW: 2002, Chronic wasting disease in deer and elk in North America. Rev Sci Tech 21:305–316.