University of Nebraska - Lincoln
DigitalCommons@University of Nebraska - Lincoln

Faculty Publications from the Harold W. Manter Laboratory of Parasitology

Parasitology, Harold W. Manter Laboratory of

2-1-2004

Erroneous Reports of the Neotropical *Echinococcus oligarthrus* as a Cause of Echinococcosis in India [Critical Comment]

Antonio D'Alessandro
Tulane University, adaless@tulane.edu

Robert L. Rausch
University of Washington, rausch@uw.edu

Follow this and additional works at: http://digitalcommons.unl.edu/parasitologyfacpubs

Part of the Parasitology Commons

D'Alessandro, Antonio and Rausch, Robert L., "Erroneous Reports of the Neotropical *Echinococcus oligarthrus* as a Cause of Echinococcosis in India [Critical Comment]" (2004). *Faculty Publications from the Harold W. Manter Laboratory of Parasitology.* Paper 336.
http://digitalcommons.unl.edu/parasitologyfacpubs/336

This Article is brought to you for free and open access by the Parasitology, Harold W. Manter Laboratory of at DigitalCommons@University of Nebraska - Lincoln. It has been accepted for inclusion in Faculty Publications from the Harold W. Manter Laboratory of Parasitology by an authorized administrator of DigitalCommons@University of Nebraska - Lincoln.

CRITICAL COMMENT . . .

J. Parasitol., 90(1), 2004, pp. 202–203
© American Society of Parasitologists 2004

Erroneous Reports of the Neotropical *Echinococcus oligarthrus* as a Cause of Echinococcosis in India

A. D'Alessandro and R. L. Rausch*, Department of Tropical Medicine, Tulane University, 1440 Canal Street, New Orleans, Louisiana 70112; *Department of Comparative Medicine, Box 357190, University of Washington, Seattle, Washington 98195. *email: adaless@tulane.edu*

ABSTRACT: Two cases of submandibular echinococcosis have been reported in adult residents of India (Kini et al., 1997; Sahni et al., 2000). It was stated in both publications that the cestode was *E. oligarthrus,* "a rare variety of *E. granulosus*", based on morphogical characteristics. It was also mentioned that 3 cases of *E. granulosus* with similar submandibular metacestode had been previously diagnosed in India. The metacestode is readily distinguishable from that of *E. oligarthrus*. The final hosts of *E. oligarthrus* are several neotropical species of wild cats and metacestode occurs in hystricognath, all of them absent in India. The larval stage of all 4 species of Echinococcus can be differentiated on the basis of the form and dimensions of rostellar hooks of protoescoleces. With the information provided in the two papers we concluded that the 2 cases of echinococcosis described in India were due to *E. granulosus*.

Cestodes of the 2 genera of Taeniidae, *Taenia* Linnaeus, 1758 and *Echinococcus* Rudolphi, 1801, are similar in their strobilar stages. Their metacestodes, however, exhibit considerable diversity in organization of component structures and in mechanisms of asexual reproduction. Species of both genera exhibit some degree of nonsignificant morphological variation, which does not obscure diagnostic taxonomic characters. The 4 species recognized in the genus *Echinococcus* are readily distinguished phenotypically in both stages.

In recent articles, *Echinococcus oligarthrus* (Diesing, 1863) has been reported to have been the cause of 2 cases of submandibular echinococcosis in adult residents of India (Kini et al., 1997; Sahni et al., 2000). In both articles, this cestode was stated to be "a rare variety of *Echinococcus granulosus.*" To support this conclusion, morphological characters believed to distinguish the metacestodes of the 2 species were listed. The authors also remarked that 3 similar cases involving submandibular metacestodes of *E. granulosus* had been previously diagnosed in India. We propose that the latter is the only cyst-forming species of *Echinococcus* in the northern hemisphere and that its metacestode is readily distinguishable from that of *E. oligarthrus*.

Echinococcus granulosus occurs worldwide in livestock-raising countries including India. Several synanthropic strains of this cestode have been distinguished by means of molecular genetic analyses; of these, 3 have been recorded in India (McManus, 2002). Where synanthropic cycles exist, the domestic dog serves as final host, and the metacestode occurs in domestic ungulates. A modification of the synanthropic cycle exists in the Arctic and Subarctic, where as hosts the dog and the domesticated reindeer replace the wolf and wild reindeer. The metacestode of *E. granulosus* consists typically of a fluid-filled, concentrically enlarging cyst. Brood capsules, closely apposed in a single layer, arise from the germinal tissue lining the external laminated membrane. Each brood capsule contains numerous protoscoleces. An anomalous form of the metacestode, multicystic and sterile, occurs rarely in the liver of sheep and other bovids. It is still frequently confused with the metacestode of *E. multilocularis* Leuckart, 1863.

Echinococcus oligarthrus is a host-specific cestode of wild cats (Felidae), occurring in numerous neotropical species (D'Alessandro et al., 1981). Until recently, it had not been recorded north of Panama, but an infected bobcat, *Lynx rufus* (Schreber), was found in northern Mexico by Salinas-López et al. (1996). The metacestode occurs typically in hystricognath rodents, of which agoutis, *Dasyprocta* spp., are the most commonly infected; it has been recorded also in spiny rats, *Proechimys* spp. (D'Alessandro et al., 1981). The metacestode is a relatively small cyst in which the brood capsules several deep form a layer over the

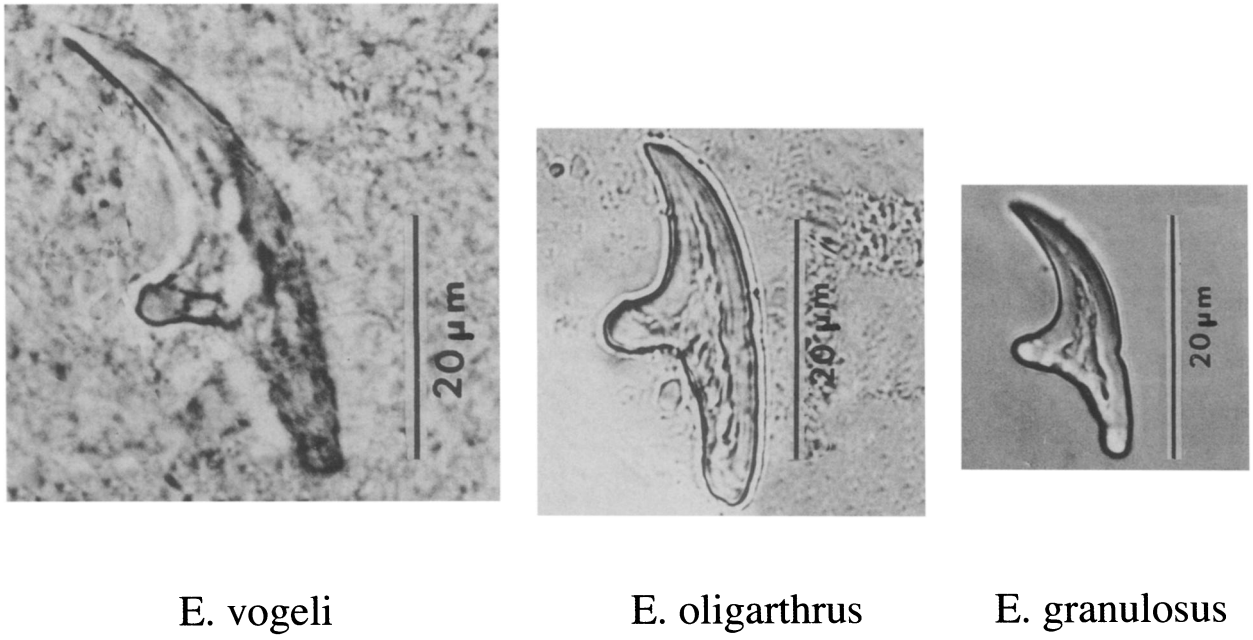

FIGURE 1. Large rostellar hooks from protoscoleces of *Echinococcus vogeli*, *E. oligarthrus*, and *E. granulosus*.

germinal tissue. Only 3 human cases of echinococcosis caused by this cestode have been reported, all in South America.

Echinococcus multilocularis has a vast geographic range in Eurasia, where the species evidently originated. Its occurrence in North America appears to have been a consequence of dispersal from the Arctic during the postglacial period. The cestode has not been recorded in India, but 2 cases of alveolar hydatid disease have been reported from Kashmir. The metacestode seems to develop invariably in the liver of natural intermediate hosts, usually rodents (Arvicolidae), as well as in primates. The metacestode in rodents consists of a mass of very small, interconnected vesicles produced by exogenous proliferation of germinal tissue. Proliferation in the human liver gives rise to cancer-like lesions of large size, within which protoscoleces are rarely produced.

Echinococcus vogeli Rausch et Bernstein, 1972 occurs in northern South America and in Panama, where a human case was first recorded. It appears to be host specific in the bush dog, *Speothos venaticus* (Lund). The metacestode occurs typically in a large hystricognath rodent, the paca *Agouti paca* (Linnaeus), that the bush dogs, by hunting in packs, are able to kill. The metacestode is usually found in the liver of pacas, in which it produces rather pleomorphic cysts containing trabeculae and scattered brood capsules of relatively large size. In higher primates, including man, the metacestode proliferates in the liver by means of a unique process, after which extensive spread into the peritoneal cavity and other organs usually occurs (Rausch and D'Alessandro, 1999).

The metacestodes of the 2 neotropical species in infected persons cannot be distinguished morphologically when protoscoleces are lacking. Contrary to opinions expressed about the cases in India, characteristics such as thickness of the laminated membrane do not serve to distinguish between the metacestodes of *E. granulosus* and *E. oligarthrus*. Metacestodes of all 4 species of *Echinococcus* can be differentiated on the basis of the form and dimensions of rostellar hooks of protoscoleces (Fig. 1). Protoscoleces are rarely produced in cases of alveolar echinococcosis, but the lesions are distinctive.

In the following comparisons, dimensions of rostellar hooks from protoscoleces are given in micrometers. In metacestodes of *E. oligarthrus*, large hooks range from 29.1 to 37.9 (mean 31.8) in length (642 hooks measured), whereas those from metacestodes of *E. vogeli* range from 38.2 to 45.6 (mean 41.8) (447 measured) (Rausch et al., 1978). Forms and dimensions of both large and small hooks differentiate the metacestodes of those species, as do rates of their development (see Fig. 1). Large hooks of *E. granulosus* from metacestodes from swine in Germany ranged from 27.0 to 31.5 (mean 28.6); for those from humans the range was 19.7–25.0 (mean 22.5) (Vogel, 1957). The same lengths (20–30) were given for a metacestode designated *E. oligarthrus* from 1 of the human cases in India and for those of *E. granulosus* by Sahni et al. (2000), and the hooks illustrated by them were typical of the latter species. Details of hooks from the second case in India were not clear, but their lengths also were given as 20–30 (Kini et al., 1997). We conclude that the 2 cases of echinococcosis described in India were caused by *E. granulosus*.

LITERATURE CITED

D'Alessandro, A., R. L. Rausch, G. A. Morales, S. Collet, and D. Angel. 1981. *Echinococcus* infections in Colombian mammals. American Journal of Tropical Medicine and Hygiene **30:** 1263–1276.

Kini, U., S. Shariff, and V. Nirmala. 1997. Aspiration cytology of *Echinococcus oligarthrus*. A case report. Acta Cytologica **41:** 544–548.

McManus, D. P. 2002. The molecular epidemiology of *Echinococcus granulosus* and cystic hydatid disease. Transactions of the Royal Society of Tropical Medicine and Hygiene **96**(suppl. 1): 151–157.

Rausch, R. L., and A. D'Alessandro. 1999. Histogenesis in the metacestode of *Echinococcus vogeli* and mechanism of pathogenesis in polycystic hydatid disease. Journal of Parasitology **85:** 410–418.

———, V. R. Rausch, and A. D'Alessandro. 1978. Discrimination of the larval stages of *Echinococcus oligarthrus* (Diesing, 1863) and *E. vogeli* Rausch and Bernstein, 1972 (Cestoda: Taeniidae). American Journal of Tropical Medicine and Hygiene **27:** 1195–1202.

Sahni, J. K., M. Jain, Y. Bajaj, V. Kumar, and A. Jain. 2000. Submandibular hydatid cyst caused by *Echinococcus oligarthrus*. Journal of Laryngology and Otology **114:** 473–476.

Salinas-López, N. F., F. Jiménez-Guzmán, and A. Cruz-Reyes. 1996. Presence of *Echinococcus oligarthrus* (Diesing, 1863) Lühe, 1910 in *Lynx rufus texensis* Allen, 1895 from San Fernando, Tamaulipas State, in north-east Mexico. International Journal for Parasitology **26:** 793–796.

Vogel, H. 1957. Uber den *Echinococcus multilocularis* Süddeutschlands. Das Bandwurmstadium von Stämmen menschlicher und tierischer Herkunft. Zeitschrift für Tropenmedizin und Parasitologie **8:** 404–456.