University of Nebraska - Lincoln
DigitalCommons@University of Nebraska - Lincoln

Faculty Publications from the Harold W. Manter Laboratory of Parasitology

Parasitology, Harold W. Manter Laboratory of

8-1-2005

Spread of an Exotic Fish-Gill Trematode: A Far-Reaching and Complex Problem

Andrew J. Mitchell
United States Department of Agricultural, dmitchell@spa.ars.usda.gov

Robin M. Overstreet
Gulf Coast Research Laboratory, robin.overstreet@usm.edu

Andrew E. Goodwin
University of Arkansas at Pine Bluff

Thomas M. Brandt
United States Fish and Wildlife Service

Follow this and additional works at: http://digitalcommons.unl.edu/parasitologyfacpubs

Part of the Parasitology Commons

Mitchell, Andrew J.; Overstreet, Robin M.; Goodwin, Andrew E.; and Brandt, Thomas M., "Spread of an Exotic Fish-Gill Trematode: A Far-Reaching and Complex Problem" (2005). *Faculty Publications from the Harold W. Manter Laboratory of Parasitology.* Paper 441.
http://digitalcommons.unl.edu/parasitologyfacpubs/441

This Article is brought to you for free and open access by the Parasitology, Harold W. Manter Laboratory of at DigitalCommons@University of Nebraska - Lincoln. It has been accepted for inclusion in Faculty Publications from the Harold W. Manter Laboratory of Parasitology by an authorized administrator of DigitalCommons@University of Nebraska - Lincoln.

Spread of an exotic fish-gill trematode: A far-reaching and complex problem

ABSTRACT

Centrocestus formosanus, the gill trematode, has caused serious losses among fish raised by tropical fish producers since the early 1980s and is believed to be harmful to wild fish populations, including the federally listed endangered fountain darter (*Etheostoma fonticola*), in the Comal River near San Marcos, Texas. The parasite appears to infect in many fishes from Hawaii, Florida, Texas, and Utah. The gill trematode has a complex life cycle involving definitive hosts (aquatic birds and occasionally some mammals) and intermediate hosts (aquatic snails and several fish species). In the United States, the green heron (*Butorides virescens*) and the great egret (*Ardea alba*) serve as definitive hosts. The first intermediate host, the red-rim melania (*Melanoides tuberculatus*), an exotic snail, has been found in 15 southern and western states. This snail exhibits resistance to desiccation, molluscicides, and disinfectants and has been documented to out-compete established mollusks. Both the gill trematode and its exotic snail host continue to spread in the United States.

Andrew J. Mitchell
Robin M. Overstreet
Andrew E. Goodwin
Thomas M. Brandt

Mitchell is a fisheries biologist and researcher at the Harry K. Dupree Stuttgart National Aquaculture Research Center, U. S. Department of Agriculture, Agricultural Research Service, Stuttgart, Arkansas. He can be contacted at dmitchell@spa.ars.usda.gov. Overstreet is a professor at The University of Southern Mississippi, Gulf Coast Research Laboratory, Ocean Springs, Mississippi. Goodwin is a professor at the Aquaculture/Fisheries Center, University of Arkansas at Pine Bluff. Brandt is director of the U. S. Fish and Wildlife Service, National Fish Hatchery and Technology Center, San Marcos, Texas.

Introduction

An exotic trematode, often referred to as the "gill trematode," affects the health of both wild and cultured fish species. The trematode is identified tentatively as *Centrocestus formosanus* and for more than 20 years has been a subject of interest and concern among fisheries scientists and fish producers. This trematode evokes broad interest because it is carried by federally-protected aquatic birds and the invasive exotic snail *Melanoides tuberculatus* and infects many fish hosts, including several endangered species. This article contains information on the history, identification, biology, pathology, spread, and unusual aspects of an exotic trematode now infecting fish in the United States. The information recorded here comes from biological observations and research efforts.

History of the gill trematode in the United States

In 1956, Walter Martin and some colleagues found larval stages of a trematode identified as *C. formosanus* emerging from the aquatic snail *Stenomelania newcombi* that was collected from ditches in Kaneohe, Oahu, Hawaii (Martin 1958). After finding the trematode in the snail, Martin (1958) reported the western mosquitofish (*Gambusia affinis*), green swordtail (*Xiphophorus hellerii*), black-crowned night-heron (*Nycticorax nycticorax*), and an unidentified rat as natural hosts for other stages of the same parasite. Several other species, including the goldfish (*Carassius auratus*) and cat (*Felix domesticus*), were experimentally infected. For the next 27 years, there was no additional report of this or a similar parasite from any region of the presently recognized United States.

Heavy losses among cichlids, tetras, and tropical cyprinids were first reported by Florida tropical fish producers in the early 1980s (Blazer and Gratzek 1985; Vogelbein and Overstreet 1988). These losses were attributed to an unidentified trematode infecting the gills of the fish. Wolfgang Vogelbein, Richard Heard, and one of the authors (RMO) completed initial life cycle studies on the trematode in 1985 at the Gulf Coast Research Laboratory (GCRL) using the cercaria (the larval stage of a trematode that invades intermediate hosts) from an aquatic snail, the red-rim melania (*M. tuberculatus*), found on ornamental fish farms in Central Florida (Vogelbein and Overstreet 1988). These studies were replicated in 1992 (and at later dates) using similar or identical cercaria in *M. tuberculatus* from wild populations in Texas. Independently, James Sullivan (Centers for Disease Control, Atlanta, Georgia) found identically infected *M. tuberculatus* from a lake in Pasco County, Florida, in December 1985 and later. In 1990, K. E. Knott found an unidentified cercaria from the red-rim melania in the San Antonio River near the San Antonio Zoo, Bexar County, Texas, and at Landa Park, New Braunfels, Comal County, Texas (Alberto Santos and Harold D. Murray, Trinity University, unpublished studies). Knot and Murray (1991) reported the responsible agent as the "mystery fluke." This trematode, sent to one of the authors (RMO) in January 1992, was determined to be the same trematode previously studied and observed. The metacercaria, a juvenile form of the trematode, was

also found in five fish species (Mexican blind/cave tetra *Astyanax fasciatus*, common carp *Cyprinus carpio*, blue tilapia *Oreochromis aureus* , redbelly tilapia *Tilapia zillii*, and green swordtail) from the San Antonio River. Although the destructive gill trematode was not identified, it was noted that the parasites found in Florida and Texas represented an introduction of a single species that was similar to *C. formosanus* found in other parts of the world.

The destructive nature of the trematode was recognized by Blazer and Gratzek (1985) and Vogelbein and Overstreet (1988) who described the damage to the gills that resulted from the trematode infection. Juvenile tropical fish losses associated with this trematode were estimated at $3.5 million (USD) annually (Francis-Floyd et al. 1997). The problem was serious enough that in the mid-1990s research efforts were directed to find means to control the snails that serve as vectors for the trematode. In 1997, a study was published to support an application by the Florida's Department of Agriculture and Consumer Services, Division of Pesticides for an EPA Special Local Needs (SLN) registration for the chemical Bayluscide® to control snails (Francis-Floyd et al. 1997). The trematode is still a serious problem within the tropical fish industry, but snail control efforts have made the problem manageable.

On 19 July 1996, 11 specimens of fountain darter (*Etheostoma fonticola)*, federally listed as an endangered species, were collected from the Comal River, Comal County, Texas, inspected, and then released (Figure 1). One of the specimens had inflamed gills, but it was not examined microscopically. On 2 October 1996, 85% of 70 specimens of the darter collected from the Comal River were observed with inflamed and protruding gills (Figure 2). The next day, three of these fish were examined by David Huffman of Texas State University at San Marcos, and the abnormal gills were found to be associated with encysted metacercariae. Most encysted individuals had

Figure 1. The fountain darter (*Etheostoma fonticola*), a federally-listed endangered species.

GLENN LONGLEY, TEXAS STATE UNIVERSITY, SAN MARCOS

Figure 2. Fountain darters infected (top) and not infected with *Centrocestus formosanus*. Proliferation of branchial tissue in infected fish may cause the opercular flaps to remain flared.

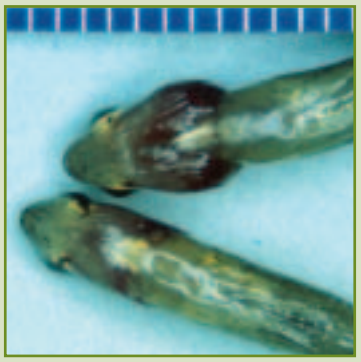

Figure 3. Complex life-cycle of the gill trematode *Centrocestus formosanus* involving a definitive bird (or mammal) host (A), the first intermediate snail host (B), and an intermediate fish host (C). (a) Metacercaria from fish eaten by bird, (b) metacercaria released from cyst in intestinal tract of definitive host, where it attaches to gut epithelium and matures into an adult worm within in a few days producing eggs that are shed into the host's lumen and then defecated into the water; (c) released trematode egg is eaten by snail and then hatches, releasing the miracidium; (d) germinal cells from miracidium develop, ultimately producing a redia; (e) redia asexually produces large numbers of the cercaria that are shed into water; (f) cercaria passively engulfed by fish or actively penetrate it; the tailless cercaria locates near a cartilage support in the gill filament; (g) cercaria develops into an encysted metacercaria and becomes encapsulated by a moderate to extensive cartilaginous response; large numbers can harm gills and fish host; (h) metacercaria exhibiting cartilaginous encapsulation.

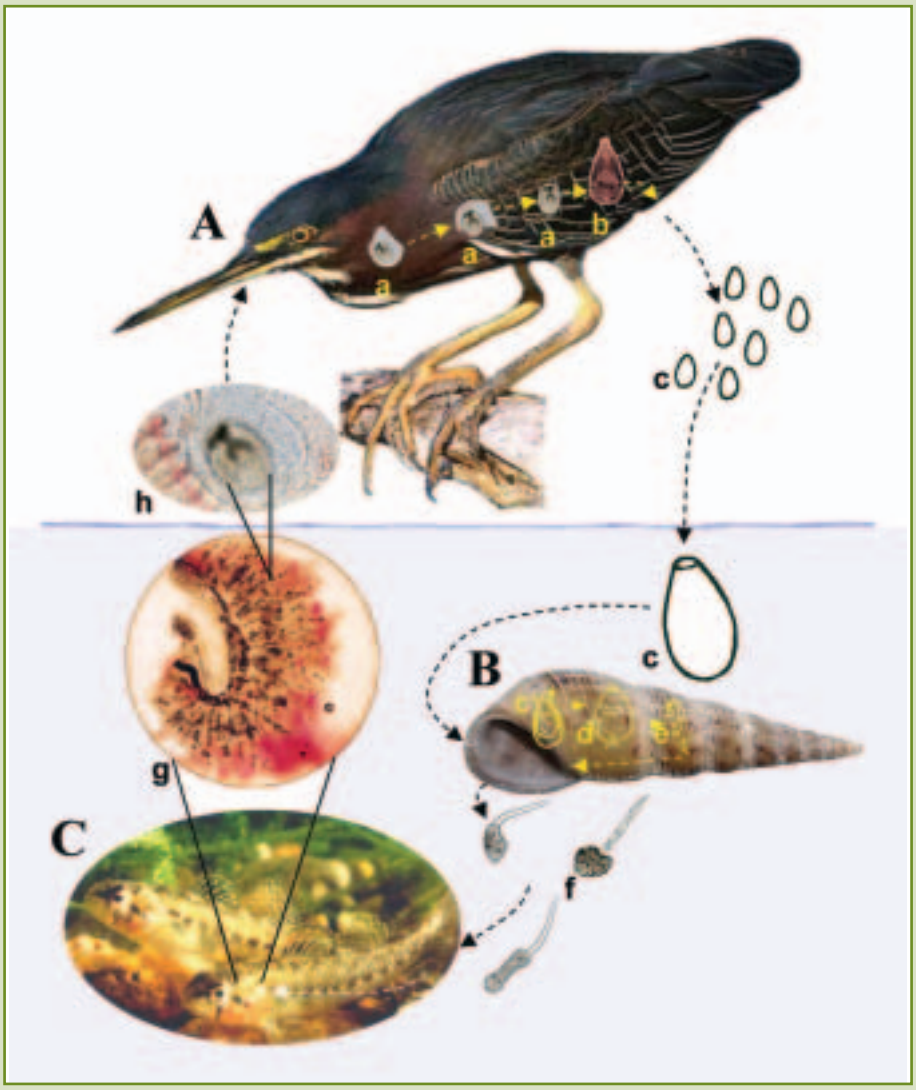

CERCARIAE WITH HEART-SHAPED BODY BY CHRIS WILSON, UTAH DIVISION OF WILDLIFE RESOURCES, LOGAN
FOUNTAIN DARTERS BY GLENN LONGLEY, TEXAS STATE UNIVERSITY, SAN MARCOS
GREEN HERON BY TOM VEZO WILDLIFE PHOTOGRAPHY, WWW.TOMVEZO.COM

undergone necrosis, but still exhibited recognizable eye-spots.

Over the next 2 months, fishes of 10 different species, including the fountain darter, were collected from the Comal and San Marcos (Hays County, Texas) rivers and sent to three fish disease diagnostic laboratories (Fish Health Center, Pinetop, Arizona; Fish Technology Center, Bozeman, Montana; and Harry K. Dupree—Stuttgart National Aquaculture Research Center [HKD-SNARC], Stuttgart, AR). The majority of the fish from the Comal River were found to be infected with cysts of the same trematode. The fountain darter and greenthroat darter (*Etheostoma lepidum)* contained the most severe infections. The Texas shiner (*Notropis amabilis)*, Mexican tetra (*Astyanax mexicanus)*, and yellow bullhead (*Ameiurus natalis)* also exhibited heavy infections. In the two darters, most of the encysted trematodes appeared necrotic. The host reaction of the darters apparently affected the trematode but also detrimentally affected the gills (host response will be discussed later). In 1996, no cyst was found in the gills of fish from the San Marcos River.

From April 1997 until May 1998, more than 350 specimens of the fountain darter from the Comal and San Marcos rivers were sent to HKD-SNARC to determine the significance of the trematode infection on health and survival of this darter. Only 4 of 145 of these fish collected from the San Marcos River had the cysts in their gills, and the mean intensity for the 4 fish was 0.25 cysts per gill arch. All 209 fish examined from the Comal River exhibited infections, with 48 fish averaging more than 50 cysts per gill arch and 17 having more than 100 per arch (one with 191 per arch). In light of the evident gill damage, we consider it surprising that any of these 21 to 35 mm TL individuals with more than 100 per arch could survive. We noticed flared opercular flaps associated with heavy infections (average of 50 or more per arch) on the Comal River fountain darters (Figure 2). Both river systems harbored large populations of the exotic red-rim melania.

Information on the trematode found in the fountain darters was presented by one of the authors (AJM) at the Third International Symposium on Aquatic Animal Health in 1998 in Baltimore, Maryland. A parasitologist (Rokkam Madhavi) from India attending the symposium observed the presentation on the Comal River trematode and suggested that the parasite was *C. formosanus*, a trematode native to Asia but now found in a number of countries. After further consultation with one of the authors (RMO), it was clear that this appeared to be an appropriate tentative identification for the trematode (Mitchell et al. 2000). However, the identification of U.S. material still remains questionable because of slight morphological differences and recent molecular data. The study by Dzikowski et al. (2004) using species-specific polymerase chain reaction assays against material identifiable as *Centrocestus* sp. from Israel and the United States, indicated two distinct species of *Centrocestus*. Additional DNA sequences are needed to better understand the taxonomy of this genus.

After metacercariae of the gill trematode were evaluated from the Comal and San Marcos rivers, they were documented at three west Texas springs (San Felipe Creek, Val Verde County; San Solomon Springs, Reeves County; and Phantom Lake Springs, Jeff Davis County) where they infected five state or federally listed fishes (endangered): Devils River minnow (*Dionda diaboli)*, proserpine shiner (*Cyprinella proserpina)*, Rio Grande darter (*Etheostoma grahami)*, Comanche Springs pupfish (*Cyprinodon elegans)*, and Pecos gambusia (*Gambusia nobilis*; McDermott 2000). Mitchell et al. (2002) reported that four major aquaculture species (channel catfish *Ictalurus punctatus*, golden shiner *Notemigonus crysoleucas*, fathead minnow *Pimephales promelas*, and sunshine bass female *Morone chrysops* × male *M. saxatilis*) could be experimentally infected with cercariae (similar to cercariae of *C. formosanus*) from red-rim melania taken from the Comal River. In 2004, 50.0% (5 of 10) of the fountain darters examined from the San Marcos River were positive (1 to 3 cysts per fish) for trematode cysts; this value compared with a 2.8% (4 of 145) prevalence for infection in darters collected from the San Marcos River in 1997 and 1998.

There are a few reports and observations of fish infected with this or a similar trematode that are not from Florida, Texas, or Hawaii. Olsen and Pierce (1997) reported a similar trematode infecting steelhead trout in cages in the Willamette River, Oregon, but there is at least one meristic difference between described material of *C. formosanus* and their specimens. The red-rim melania has been found in geothermal waters in Oregon but not in the Willamette River or its tributaries (T. Anderson, University of Colorado, unpublished data). During 2002, tropical fish from Georgia exhibiting the gill trematode were submitted to HKD-SNARC; but, considering that the red-rim melania has not been reported from Georgia, we think the parasite might have been imported within the fish from another state. In the spring of 2003, the parasite was observed in western Utah in speckled dace (*Rhinichthys osculus)* and *Gambusia* sp. at Gandy Warm Springs, Millard County, and Goshen Warm Springs, Utah County, respectively (Chris Wilson, Utah Division of Wildlife Resources, personal communication). Both springs contain red-rim melania populations. This observation is sufficient to add Utah to the list of states with the gill trematode.

Hosts of the gill trematode

Centrocestus formosanus has a complex life cycle that involves three life stages (Figure 3). The metac-

ercarial stage infects the gills of many fish species and occasionally the intestinal wall and muscles of frogs *Rana* spp. (Salgado-Maldonado et al. 1995). In the United States, known fish hosts include members of the centrarchid, characid, cichlid, cyprinid, cyprinodontid, gobid, ictalurid, kuhliida, mugilids, percid, percichthyid, and poecilid families. The adult stage occurs in the GI tract of specific piscivorous birds and mammals. Many piscivorous birds may host the parasite, but to date, we have confirmed only the green heron (*Butorides virescens)* and the great egret (*Ardea alba)* as hosts in the continental United States. Fish-eating mammals, including members of the Carnivora and Rodentia orders, might also serve as final hosts (Martin 1958; Premvati and Pande 1974; Vogelbein, Heard and Overstreet, USM, unpublished studies). The early larval stages asexually develop in the red-rim melania, the first intermediate host. That snail, also called the Malaysian burrowing snail, Malaysian trumpet snail, and cornucopia snail, belongs in the family Thiaridae (Dudgeon 1989). It, along with two other members of the same family not found in the continental United States, host the trematode worldwide. The snail host usually serves as the target for controlling trematode infections; therefore, a more in-depth discussion of this host is warranted.

Figure 4. *Melanoides tuberculatus,* showing spire-shaped shells with shell heights of 5 to 40 mm. This snail, the red-rim melania, is the only known first intermediate host of *Centrocestus formosanus* in the Americas.

The red-rim melania has an elongate conical shell with rounded whorls and fleshy protuberances on the mantle's edge, and its shell can reach a height of more than 70 mm (Figure 4; Murray 1975; Burch 1982). Experimentally, the snail can survive temperatures above 17.0°C and below 32.5°C (Mitchell and Brandt 2005). It occurs primarily in freshwater but can survive salinities up to 30 ppt (Roessler et al. 1977; Smith 1989). Even though native to Asia, it presently inhabits tropical and subtropical locations throughout the world (Abbott 1973; Dudgeon 1986; Amaya-Huerta and Almeyda-Artigas 1994). Based on information where the red-rim melania has been found in the United States (T. Anderson, University of Colorado unpublished data), it appears that the snail is restricted to year-round warm waters. *Melanoides tuberculatus* was first documented in the continental United States in Texas in 1964 (Murray 1964). At least 15 states, including the most southern states and several western ones with geothermal waters, had or now have confirmed wild stocks of the red-rim melania (T. Anderson, University of Colorado unpublished data).

Because the red-rim melania has an operculum, it exhibits resistance to desiccation, molluscicides, and disinfectants (Dudgeon 1982; Francis-Floyd 1991). The snail can live up to 8 days in a dry pan and 3 of 10 individuals survived full strength household bleach for 60 min (Dudgeon 1982; Mitchell and Brandt unpublished data). The snail out-competes some established mollusks, partly because of its ability to reproduce parthenogenically and to brood young internally (Jacobson 1975; Perera et al. 1990). Lastly, the red-rim melania harbors other trematodes including two human pathogens, the human liver fluke *(Opisthorchis sinensis)* and the oriental lung fluke *(Paragonimus westermani)*, as well as an eye fluke (*Philopthalmus gralli)* of birds (Abbott 1952; Dundee and Paine 1977; Nollen and Murray 1978). The two human trematodes have not yet been found in red-rim melania in the United States.

Pathology of the gill trematode

Few trematodes cause harm to their fish hosts, and few fish mount host responses that affect the trematodes. Migration of cercariae through host tissues may produce minimal mechanical damage and hemorrhaging (Hoffman 1999) and may also modify host behavior in a manner that improves the chance for the fish being eaten by a definitive vertebrate host (e.g., Overstreet and Curran 2004). Occasionally, heavy trematode infections in fish result in serious tissue displacement, secondary bacterial infection, and death (Mitchell et al. 1982; Overstreet and Curran 2004).

Centrocestus formosanus, unlike most trematodes, produces serious alterations in the gills of many freshwater fishes (Mitchell et al. 2000, 2002). Within 1 h after infection, the cercaria lodges next to the gill filament cartilage (Blazer and Gratzek 1985). The parasite induces an unusual inflammatory response characterized by a proliferation of host fibroblasts that apparently differentiate into chondroblasts and then chondrocytes that form a cartilaginous encapsulation around the parasite (Blazer and Gratzek 1985; Vogelbein and Overstreet 1988) (Figure 5). The encapsulations may continue to thicken, ultimately destroying the normal gill architecture, reducing the surface area of the respiratory epithelium. Gill function may be further compromised by an influx of other inflammatory cells, including macrophages, eosinophils, heterophils, and lymphocytes (Blazer and Gratzek 1985). The encapsulation may incorporate more than one cyst (Figure 6). In the two species of *Etheostoma* in the Comal River, the trematode dies within the cyst, but the host response still destroys much functional gill tissue, probably resulting in the death of heavily-infected individuals. Response to this parasite is in contrast to well-adapted host-parasite relationships, where damage to the host is not life

threatening. Perhaps one reason some groups of fishes, both native and introduced, are so susceptible to mortality results from their being naive to the introduced parasite.

Control of the gill trematode

The control of *C. formosanus* in the United States is complex because of the involvement of three life stages, some of which include exotic and endangered species. Managing the parasite will be difficult because the avian hosts are highly mobile, human intervention has and is spreading infected fish and snails, and many different fish species are susceptible. The most practical approach will be to develop methods to treat and prevent the further spread of this very prolific and hardy exotic snail. Research has shown that red-rim melania with shell heights of 2 to 40 mm can be killed by a 3 min exposure to 50°C (temperature of most residential and commercial hot water systems; Mitchell and Brandt 2005). Therefore, items such as dipnets, boots, and seines that contact waters containing red-rim melania should be dipped in this hot water bath for at least 5 min before being used in any waters without the snail. No other effective method of disinfection is presently reported; however, a low concentration of Roccal-D Plus® (10 ppm), a quaternary ammonium product, for 24 h appears promising in killing all red-rim melania tested (Mitchell and Brandt unpublished studies). In ornamental fish ponds, a treatment of Bayluscide at 1.1 kg/ha of pond bottom is effective for controlling nuisance snail populations including *M. tuberculatus* (Francis-Floyd et al. 1997). Fish should not be stocked for at least 10 days after application. Bayluscide has U.S. Environmental Protection Agency Special Local Needs labels for use in Florida and Arkansas only, and has been legal under single season Section 18 Emergency Exemptions in other southeastern states.

The red-rim melania can be purchased in many pet shops throughout the country and over the Internet. Care must be taken not to allow it to become established in melania-free warm waters. The snail can also be transferred on vegetation from one site to another (snail hatchlings, 2 to 3 mm shell height, readily attach to aquatic vegetation); therefore, we do not advise anyone to transport vegetation from water inhabited by red-rim melania to those not inhabited by the snail. Limiting the spread of the carrier snail will limit the spread of the gill trematode.

Figure 5. Proliferated cartilage surrounding metacercarial cyst of *Centrocestus formosanus.*

Figure 6. Gill filaments of an experimentally infected hybrid striped bass containing multiple metacercariae of *Centrocestus formosanus* encapsulated by proliferated cartilage tissue.



References

Abbott, R. T. 1952. A study of an intermediate snail host (*Thiara granifera*) of the oriental lung fluke (*Paragonimus*). Proceedings of the United States National Museum 102:71-116.

_____ . 1973. Spread of *Melanoides tuberculata*. The Nautilus 87:29.

Amaya-Huerta, D., and **R. J. Almeyda-Artigas.** 1994. Confirmation of *Centrocestus formosanus* (Nishigori, 1924) Price, 1932 (Trematoda: Heterophyidae) in Mexico. Research and Reviews in Parasitology 54:99-103.

Blazer, V. S., and **J. B. Gratzek.** 1985. Cartilage proliferation in response to metacercarial infections of fish gills. Journal of Comparative Pathology 95:273-280.

Burch, J. B. 1982. North American freshwater snails. V. Keys to the freshwater gastropods of North America. Society for Experimental and Descriptive Malacology, Niwot, Colorado.

Dudgeon, D. 1982. Aspects of the desiccation tolerance of four species of benthic mollusca from Plover Cove Reservoir, Hong Kong. The Veliger 24:267-271.

_____. 1986. The life cycle, population dynamics and productivity of *Melanoides tuberculata* (Muller, 1774) (Gastropoda: Prosobranchia: Thiaridae) in Hong Kong. Journal of Zoology 208:37-53.

_____. 1989. Ecological strategies of Hong Kong Thiaridae (Gastropoda: Prosobranchia). Malacological Review 22:39-53.

Dundee, D. S., and **A. Paine.** 1977. Ecology of the snail, *Melanoides tuberculata* (Muller) intermediate host of the human liver fluke (*Opisthorchis sinensis*) in New Orleans, Louisiana. The Nautilus 91:17-20.

Dzikowski, R., M. G. Levy, M. F. Poore, J. R. Flowers, and **I. Paperna.** 2004. Use of rDNA polymorphism for identification of heterophyidae infecting freshwater fishes. Diseases of Aquatic Organisms 59:35-41.

Francis-Floyd, R. 1991. Use of Bayer 73 to control snails in ornamental fish ponds. Pages 467-490 *in* Aquaculture Report Series. Florida Department of Agriculture and Consumer Services, Tallahassee.

Francis-Floyd, R., J. Gildea, P. Reed, and **R. Klinger.** 1997. Use of Bayuluscide (Bayer 73) for snail control in fish ponds. Journal of Aquatic Animal Health 9:41-48.

Hoffman, G. L. 1999. Parasites of North American freshwater fishes, 2nd ed., Comstock Publishing Associates, Cornell University Press, Ithaca, New York.

Knot, K. E., and **H. D. Murray.** 1991. Mystery fluke in *Melanoides tuberculata* (Gastropoda: Thiaridae) in the San Antonio Zoo, San Antonio, Texas. Combined Annual Meetings, Western Society of Malacologists and American Malacological Union,

Proceedings and Abstracts from the Joint Annual Meeting. Berkeley, California

Jacobson, M. K. 1975. The freshwater prosobranch, *Tarebia ganifera*, in Oriente, Cuba. The Nautilus 89:106.

Martin, W. E. 1958. The life histories of some Hawaiian heterophyid trematodes. Journal of Parasitology 44:305-323.

McDermott, K. S. 2000. Distribution and infection relationships of an undescribed digenetic trematode, its exotic intermediate host, and endangered fishes in springs of West Texas. Thesis, Southwest Texas State University, San Marcos.

Mitchell, A. J., and T. M. Brandt. 2005. Temperature tolerance of red-rimmed melania, an exotic aquatic snail established in the United States. Transactions of the American Fisheries Society 134:126-131.

Mitchell, A. J., C. E. Smith and **G. L. Hoffman.** 1982. Pathogenicity and histopathology of an unusually intense infection of white grubs (*Posthodiplostomum m. minimum*) in the fathead minnow (*Pimephales promelas*). Journal of Wildlife Diseases 18:51-57.

Mitchell, A. J., M. J. Salmon, D. G. Huffman, A. E. Goodwin, and **T.M. Brandt.** 2000. Prevalence and pathogenicity of a heterophyid trematode infecting the gills of an endangered fish, the fountain darter, in two central Texas spring-fed rivers. Journal of Aquatic Animal Health 12:283-289.

Mitchell, A. J., A. E. Goodwin, M. J. Salmon and **T. M. Brandt.** 2002. Experimental infection of an exotic heterophyid trematode, *Centrocestus formosanus*, in four aquaculture fishes. North American Journal of Aquaculture 64:55-59.

Murray, H. D. 1964. *Tarebia granifera* and *Melanoides tuberculata* in Texas. Abstract. Annual Reports American Malacological Union 1964:15-16.

_____. 1975. *Melanoides tuberculata* (Muller), Las Moras Creek, Bracketville, Texas. Bulletin of the American Malacological Union 1975:43.

Nollen, P. M., and **H. D. Murray.** 1978. *Philophthalmus gralli:* identification, growth characteristics, and treatment of an oriental eyefluke of birds introduced into the continental United States. Journal of Parasitology 64:178-180.

Olsen, R. E., and **J. R. Pierce.** 1997. A trematode metacercaria causing gill cartilage proliferation in steelhead trout from Oregon. Journal of Wildlife Diseases 33:886-890.

Overstreet, R. M., and **S. S. Curran.** 2004. Defeating diplostomoid dangers in USA catfish aquaculture. Folia Parasitologica 51:153-165.

Perera, G., M., Yong, J. R. Ferrer, C. Arrinda, and **O. Amador.** 1990. Effectiveness of three biological control agents against intermediate hosts of snail-mediated parasites in Cuba. Malacological Review 23:47-52.

Premvati, G., and **V. Pande.** 1974. On *Centrocestus formosanus* (Nishigori, 1924) Price, 1932 and its experimental infection in white leghorn chicks. Japanese Journal of Parasitology 23(3):79-84.

Roessler, M. A., C. L. Beardsley, and D. C. Tabb. 1977. New records of the introduced snail, *Melanoides tuberculata* (Mollusca: Thiaridae) in South Florida. Florida Scientist 40:87-94.

Salgado-Maldonado, G., M. I. Rodriguez-Vargas and J. J. Campos-Perez. 1995. Metacercariae of *Centrocestus formosanus* (Nishigori, 1924) (Trematoda) in freshwater fishes in Mexico and their transmission by the thiarid snail *Melanoides tuberculata*. Studies on Neotropical Fauna and Environment 30(4):245-250.

Smith, B. J. 1989. Traveling snails. Journal of Medical and Applied Malacology 1:195-204.

Vogelbein, W. K., and **R. M. Overstreet.** 1988. Life-history and pathology of a heterophyid trematode infecting Florida-reared ornamental fishes. International Association for Aquatic Animal Medicine Proceedings 19:138.