University of Nebraska - Lincoln
DigitalCommons@University of Nebraska - Lincoln

Publications from USDA-ARS / UNL Faculty

USDA Agricultural Research Service --Lincoln, Nebraska

1-1-2004

Escherichia coli O157:H7 in the gallbladders of experimentally infected calves

William C. Stoffregen
Pre-Harvest Food Safety Research Unit

Joachim F. L. Pohlenz
School of Veterinary Medicine, Hannover, Germany

Evelyn A. Dean-Nystrom
Pre-Harvest Food Safety and Enteric Diseases Research Unit, evelyn.nystrom@ars.usda.gov

Follow this and additional works at: http://digitalcommons.unl.edu/usdaarsfacpub

Part of the Agricultural Science Commons

Stoffregen, William C.; Pohlenz, Joachim F. L.; and Dean-Nystrom, Evelyn A., "*Escherichia coli* O157:H7 in the gallbladders of experimentally infected calves" (2004). *Publications from USDA-ARS / UNL Faculty.* Paper 938.
http://digitalcommons.unl.edu/usdaarsfacpub/938

This Article is brought to you for free and open access by the USDA Agricultural Research Service --Lincoln, Nebraska at DigitalCommons@University of Nebraska - Lincoln. It has been accepted for inclusion in Publications from USDA-ARS / UNL Faculty by an authorized administrator of DigitalCommons@University of Nebraska - Lincoln.

Journal of Veterinary Diagnostic Investigation
http://vdi.sagepub.com/

Escherichia coli O157:H7 in the Gallbladders of Experimentally Infected Calves

William C. Stoffregen, Joachim F. L. Pohlenz and Evelyn A. Dean-Nystrom

J VET Diagn Invest 2004 16: 79
DOI: 10.1177/104063870401600114

The online version of this article can be found at:
http://vdi.sagepub.com/content/16/1/79

Published by:
SAGE
http://www.sagepublications.com

On behalf of:

Official Publication of the American Association of Veterinary Laboratory Diagnosticians, Inc.

Additional services and information for *Journal of Veterinary Diagnostic Investigation* can be found at:

Email Alerts: http://vdi.sagepub.com/cgi/alerts

Subscriptions: http://vdi.sagepub.com/subscriptions

Reprints: http://www.sagepub.com/journalsReprints.nav

Permissions: http://www.sagepub.com/journalsPermissions.nav

Citations: http://vdi.sagepub.com/content/16/1/79.refs.html

>> Version of Record - Jan 1, 2004

What is This?

Downloaded from vdi.sagepub.com at UNIV OF NEBRASKA LINCOLN on August 2, 2012

J Vet Diagn Invest 16:79–83 (2004)

Escherichia coli O157:H7 in the gallbladders of experimentally infected calves

William C. Stoffregen, Joachim F. L. Pohlenz, Evelyn A. Dean-Nystrom[1]

Abstract. Fifteen weaned calves (age 89–141 days) were treated with dexamethasone (0.25 mg/kg, IV) for 3 days before, the day of, and the day after inoculation with 10 colony-forming units of either *Escherichia coli* O157:H7 (strain 86-24, which produces Shiga toxin 2 and intimin; $n = 13$) or nonpathogenic *E. coli* (strain 123, which does not produce Shiga toxin or intimin; $n = 2$). All calves were necropsied 4 days after inoculation. Histologic lesions of attaching and effacing bacteria were observed in the large intestine (12/13) and in the gallbladder mucosa (5/13) of calves inoculated with *E. coli* 86-24. Cholecystitis was present in 12 of 13 calves that received *E. coli* 86-24. Inoculum bacteria were recovered from the distal colons or feces (13/13) and gallbladders (3/4) of calves inoculated with 86-24.

Enterohemorrhagic *Escherichia coli* (EHEC), a subset of Shiga toxin–producing *E. coli* (STEC), are associated with a wide range of clinical manifestations, including asymptomatic carriage, nonhemorrhagic diarrhea, hemorrhagic colitis, hemolytic–uremic syndrome, and thromboembolic thrombocytopenic purpura in humans.[15] Shiga toxin–producing *E. coli* O157:H7 is the most frequently reported serotype associated with human EHEC disease.[13,14] Human EHEC infections can often be traced to the ingestion of improperly cooked, O157:H7–contaminated beef products, or produce or water contaminated with bovine manure. Cat-

From the Pre-Harvest Food Safety Research Unit (Stoffregen, Pohlenz, Dean-Nystrom) and the Bacterial Diseases of Livestock Research Unit (Stoffregen), National Animal Disease Center, U.S. Department of Agriculture, Agricultural Research Service, P.O. Box 70, Ames, IA 50010, and the School of Veterinary Medicine, D-30559 Hannover, Germany (Pohlenz). [1] Corresponding author.

This article is a U.S. government work, and is not subject to copyright in the United States.

Table 1. Results from 15 calves experimentally treated with dexamethasone, inoculated with *E. coli* O157:H7 strain 86-24 or control strain 123, and necropsied at 4 d postinoculation.

E. coli inoculum (strain)	Calf No.	Cholecystitis	A/E lesions*		Inoculum bacteria in distal colon/feces†
			Gallbladder	Large intestine	
86-24‡	1	+	+	+	yes/yes
	2	+	−	+	yes/yes
	3	+	−	+	yes/yes
	4	+	−	+	no/yes
	5	+	−	+	yes/yes
	6	+	+	+	yes/yes
	7	+	−	−	no/yes
	8	+	−	+	yes/yes
	9	+	+	+	yes/yes
	10	+	−	+	yes/yes
	11	+	+	+	yes/yes
	12	−	−	+	yes/yes
	13	+	+	+	yes/yes
123§	C1	−	−	−	no/no
	C2	−	−	−	no/no

* Attaching and effacing lesions.
† yes = $\geq 10^4$ colony-forming units per gram of tissue or feces.
‡ O157:H7 strain.
§ Control strain.

tle have been shown to carry EHEC strains in their gastrointestinal tracts for varying periods of time.[1,4,9] Although cattle are generally regarded as asymptomatic carriers of human EHEC, STEC O157:H7 and other STEC can cause nonhemorrhagic or mucohemorrhagic diarrhea in experimentally inoculated calves.[3,4,6,16] Dysentery has also been reported in calves naturally infected with non-O157 STEC.[10] Many STEC, including STEC O157:H7, produce intimin, an outer-membrane protein that facilitates the intimate attachment of the EHEC bacterium to the host cell membrane. Loss of microvilli and effacement of host cell cytoplasm follows attachment. These characteristic lesions of bacterial attachment and cytoplasmic effacement (A/E) are associated with both natural and experimental STEC infections.[4,5,6,7,10,12,16]

Initial attempts to establish a reproducible weaned calf STEC O157:H7 infection model were hampered by large variations in the susceptibility of cattle to experimental STEC infections.[3,5] It was hypothesized that high-dose corticosteroid administration would simulate the physiologic response of cattle during the preslaughter period and increase their susceptibility to STEC infection. Administration of corticosteroids in high doses mimics the effects of physiologic stress, and corticosteroids have been widely used in the experimental reproduction of numerous viral, protozoal, and bacterial diseases in various species of animals. Stress due to feed and water restriction, assemblage of large groups, and transportation during the preslaughter period has been proposed as a factor in the high incidence of shedding of STEC bacteria by slaughter cattle.[9] The addition of high-dose corticosteroid treatment during the peri-inoculation period enhanced the susceptibility of weaned calves[8] and resulted in the observations reported in this study.

Fifteen weaned calves, ranging in age from 89 to 141 days and fecal culture–negative for STEC O157:H7, were used in this study. The calves were of the following breeds: Jersey ($n = 6$), Hereford ($n = 5$), and Holstein Friesian × Black Angus cross ($n = 4$). All calves were housed in an environmentally controlled facility in individual pens for at least 2 weeks before inoculation and for the duration of the study and fed a standard beef grower–finisher ration with hay cubes.

All calves were treated with dexamethasone (0.25 mg/kg) by IV administration for 5 consecutive days: 3 days before inoculation, on the day of inoculation, and on the day after inoculation. Beginning 3 days before the first dexamethasone treatment and for the duration of the experiment, peripheral venous blood samples were collected daily for complete and differential blood counts. Feed was withheld from all animals for 2 days before inoculation. Calves were inoculated, through an oral-rumen tube, with 200 ml trypticase soybroth (TSB) containing 10^{10} colony-forming units of either *E. coli* O157:H7 (strain 86-24, which produces Shiga toxin 2 and intimin[6]; $n = 13$) or a nonpathogenic *E. coli* control strain (strain 123,[4] which does not produce Shiga toxin or intimin; $n = 2$). Fecal samples for bacterial counts were collected

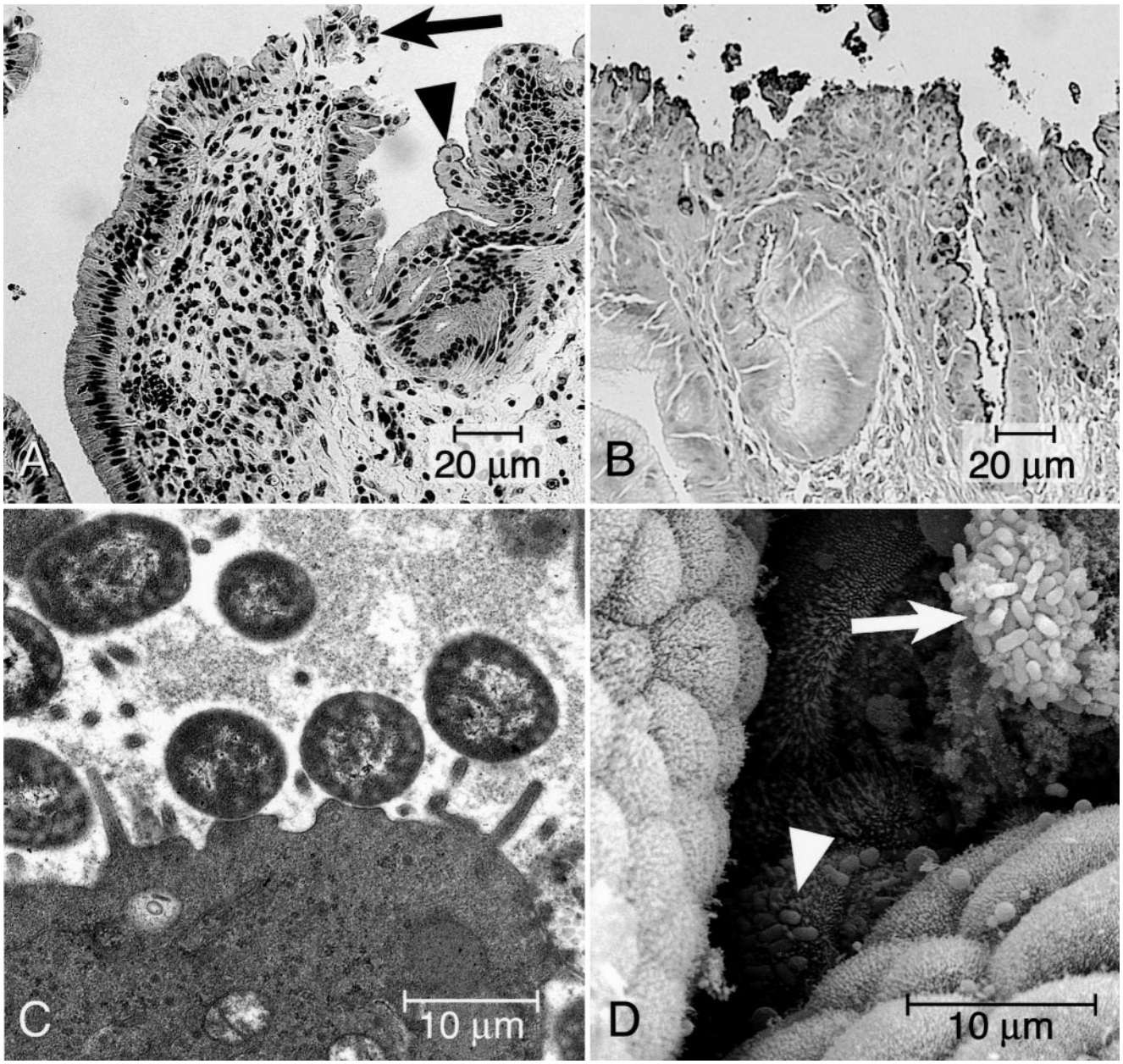

Figure 1. Photomicrographs and electron micrographs of A/E lesions in gallbladder from a dexamethasone-treated weaned calf necropsied 4 days after inoculation with EHEC strain 86-24. **A**, hematoxylin and eosin–stained section showing cholecystitis with a focal area of necrosis and erosion of gallbladder epithelial cells (arrow), partial effacement of the epithelial cytoplasm, and attached bacteria (arrowhead). **B**, anti–O157:H7 immunoperoxidase–stained section showing microcolonies (dark patches) containing O157:H7–positive bacteria on the mucosal surface, in the crypts, and on detached cells in lumen. **C**, transmission electron micrograph showing bacteria intimately attached to cytoplasmic, cup-shaped pedestals on gallbladder epithelial cells and effacement of microvilli. **D**, scanning electron micrograph showing microcolonies of bacteria (arrow) and intimate association of bacteria with apical cell membranes (arrowhead). Microvilli appear uniform and normal in areas without bacteria (e.g., on the left and lower right portions of the photograph). Figure 1 is reproduced from Dean-Nystrom and Stoffregen[8] with permission from the World Buiatrics Congress.

from the rectum daily, from the day of inoculation until necropsy. Rectal temperatures and clinical observations, including fecal characteristics, were noted daily on all calves. All calves were euthanized 4 days after inoculation, and complete necropsies were performed. Samples of distal colon and feces were collected using aseptic techniques and processed for bacterial counts as previously described.[4,6] Samples of gallbladder for bacterial counts were also collected from 4 of the calves inoculated with strain 86-24. Tis-

sues including liver, gallbladder, ileum, ileocecal valve, cecum, ascending colon, spiral colon, and distal colon were fixed in 10% neutral buffered formalin and processed by routine methods. Five-micrometer-thick tissue sections were stained with hematoxylin and eosin for histological examination and stained by an avidin–biotin–horseradish peroxidase immunochemical technique for *E. coli* O157:H7 as previously described.[4,6] Sections of gallbladder were fixed in 1% glutaraldehyde for 4 hours and processed by routine methods for transmission and scanning electron microscopy.

All calves exhibited leukograms consistent with physiologic stress/corticosteroid administration beginning 1 day after the first dexamethasone administration and persisting for the duration of the study. The stress leukograms were characterized by leukocytosis, neutrophilia without left shift, lymphopenia, eosinopenia, and occasionally monocytosis. No calves experienced diarrhea or any significant change in fecal consistency, and no blood was observed in any fecal samples collected after inoculation.

Results are summarized in Table 1. The only significant gross lesion observed was edema of the gallbladder serosa, which was seen in 12/13 calves inoculated with strain 86-24. Histologically, A/E lesions were observed in various segments of the large intestine in 12/13 calves inoculated with strain 86-24. These lesions were characterized by numerous punctate bacteria, identified as *E. coli* O157:H7 by immunohistochemistry, attached to segmental areas of surface and crypt epithelial cells. Effacement of apical cytoplasm was also prominent. Some areas contained segmental erosions of the mucosa, which were accompanied by infiltrates of neutrophils. Similar A/E lesions were seen in the gallbladder mucosa in 5/13 calves inoculated with strain 86-24 (Fig. 1). Cholecystitis was also present in 12/13 calves inoculated with strain 86-24. The cholecystitis was characterized by transmural edema, multifocal infiltrates of lymphocytes, plasma cells, and neutrophils in the submucosa and lamina propria, and occasional segmental erosion of the mucosa with neutrophils in the lamina propria adjacent to the erosive area. Edema has not been noted, and A/E lesions have not been seen, in any of the gallbladders of O157:H7–infected calves not treated with dexamethasone (unpublished data). No gross or histopathologic lesions were seen in either of the 2 calves that received the nonpathogenic control strain 123. Inoculum bacteria were recovered from the feces or distal colon (13/13 calves) and gallbladder (3/4 calves) of calves inoculated with stain 86-24 but not from the distal colon or feces (gallbladder of controls was not cultured) of 2 calves inoculated with strain 123.

This is the first report of the localization of STEC bacteria and A/E lesions in the gallbladder of cattle. This finding identifies the gallbladder as a possible niche for STEC in cattle, as it is for other enteric pathogens, notably *Salmonella*.[11] The gallbladder may be a site of and a source of gastrointestinal STEC, which can contaminate beef products. This observation warrants further investigation into the gallbladder as a site of infection in naturally and experimentally infected animals and the possibility of the gallbladder as a site of persistent infection in cattle. Reports of cholelithiasis following STEC O157:H7–associated hemolytic uremic syndrome in humans[2] indicate that the gallbladder may also be involved in human STEC infections.

Acknowledgements. We thank M. H. Inbody and B. K. Wheeler for technical assistance. A preliminary account of this work was presented at the XXII World Buiatrics Congress, Hannover, Germany, August 18–23, 2002. Mention of trade names or commercial products in this article is solely for the purpose of providing specific information and does not imply recommendation or endorsement by the U.S. Department of Agriculture.

References

1. Besser TE, Richards BL, Rice DH, Hancock DD: 2001, *Escherichia coli* O157:H7 infection of calves: infectious dose and direct contact transmission. Epidemiol Infect 127:555–560.
2. Brandt JR, Joseph MW, Fouser LS, et al.: 1998, Cholelithiasis following *Escherichia coli* O157:H7-associated hemolytic uremic syndrome. Pediatr Nephrol 12:222–225.
3. Cray WC Jr, Moon HW: 1995, Experimental infection of calves and adult cattle with *Escherichia coli* O157:H7. Appl Environ Microbiol 61:1586–1590.
4. Dean-Nystrom EA, Bosworth BT, Cray WC Jr, Moon HW: 1997, Pathogenicity of *Escherichia coli* O157:H7 in the intestines of neonatal calves. Infect Immun 65:1842–1848.
5. Dean-Nystrom EA, Bosworth BT, Moon HW: 1999, Pathogenesis of *Escherichia coli* O157:H7 in weaned calves. Adv Exp Med Biol 473:173–177.
6. Dean-Nystrom EA, Bosworth BT, Moon HW, O'Brien AD: 1998, *Escherichia coli* O157:H7 requires intimin for enteropathogenicity in calves. Infect Immun 66:4560–4563.
7. Dean-Nystrom EA, Bosworth BT, O'Brien AD, et al.: 1999, Bovine infection with *Escherichia coli* O157:H7. *In: E. coli O157* in farm animals, ed. Stewart CS, Flint HJ, pp. 51–58. CAB International, Wallingford, UK.
8. Dean-Nystrom EA, Stoffregen WC: 2002, Role of EHEC in cattle and humans. *In:* Recent developments and perspectives in bovine medicine: keynote lectures of the XXII World Buiatrics Congress, ed. Kaske M, Scholz H, Höltershinken M, pp. 68–74. Klinik für Rinderkrankheiten, Tierärztliche Hochschule Hannover, Hannover, Germany.

9. Elder RO, Keen JE, Siragusa GR, et al.: 2000, Correlation of enterohemorrhagic *Escherichia coli* O157 prevalence in feces, hides, and carcasses of beef cattle during processing. Proc Natl Acad Sci USA 97:2999–3003.
10. Gunning RF, Wales AD, Pearson GR, et al.: 2001, Attaching and effacing lesions in the intestines of two calves associated with natural infection with *Escherichia coli* O26:H11. Vet Rec 148:780–782.
11. Kampelmacher EH, Guinee PAM, Hafstra K, van Keulen A: 1961, Studies on Salmonella in slaughter houses. Zentbl Vetmed 8:1025–1042.
12. Mainil JG, Duchesnes CJ, Whipp SC, et al.: 1987, Shiga-like toxin production and attaching effacing activity of *Escherichia coli* associated with calf diarrhea. Am J Vet Res 48:743–748.
13. Nataro JP, Kaper JB: 1998, Diarrheagenic *Escherichia coli.* Clin Microbiol Rev 11:142–201.
14. Paton JC, Paton AW: 1998, Pathogenesis and diagnosis of Shiga toxin-producing *Escherichia coli* infections. Microbiol Rev 11: 450–479.
15. Su C, Brandt LJ: 1995, *Escherichia coli* O157:H7 infection in humans. Ann Intern Med 123:698–714.
16. Wray C, McLaren I, Pearson GR: 1989, Occurrence of ‘attaching and effacing’ lesions in the small intestine of calves experimentally infected with bovine isolates of verotoxigenic *Escherichia coli.* Vet Rec 125:365–368.