

University of Nebraska - Lincoln

DigitalCommons@University of Nebraska - Lincoln

USDA National Wildlife Research Center - Staff
Publications

U.S. Department of Agriculture: Animal and Plant
Health Inspection Service

2013

Use of a GnRH vaccine, GonaCon™, for prevention and treatment of adrenocortical disease (ACD) in domestic ferrets

Lowell A. Miller

USDA/APHIS/Wildlife Services' National Wildlife Research Center, Fort Collins, CO, lowell.a.miller@aphis.usda.gov

Kathleen A. Fagerstone

USDA-APHIS National Wildlife Research Center, Fort Collins, kathleen.a.fagerstone@aphis.usda.gov

Robert A. Wagner

University of Pittsburgh

Mark Finkler


Roanoke Animal Hospital

Follow this and additional works at: http://digitalcommons.unl.edu/icwdm_usdanwrc

Miller, Lowell A.; Fagerstone, Kathleen A.; Wagner, Robert A.; and Finkler, Mark, "Use of a GnRH vaccine, GonaCon™, for prevention and treatment of adrenocortical disease (ACD) in domestic ferrets" (2013). *USDA National Wildlife Research Center - Staff Publications*. 1235.

http://digitalcommons.unl.edu/icwdm_usdanwrc/1235

This Article is brought to you for free and open access by the U.S. Department of Agriculture: Animal and Plant Health Inspection Service at DigitalCommons@University of Nebraska - Lincoln. It has been accepted for inclusion in USDA National Wildlife Research Center - Staff Publications by an authorized administrator of DigitalCommons@University of Nebraska - Lincoln.



Use of a GnRH vaccine, GonaCon™, for prevention and treatment of adrenocortical disease (ACD) in domestic ferrets



Lowell A. Miller^a, Kathleen A. Fagerstone^{a,*}, Robert A. Wagner^b, Mark Finkler^c

^a US Department of Agriculture/Animal and Plant Health Inspection Service/Wildlife Services, National Wildlife Research Center, 4101 LaPorte Avenue, Fort Collins, CO 80521, USA

^b University of Pittsburgh, Division of Lab Animal Medicine, Pittsburgh, PA 15261, USA

^c Roanoke Animal Hospital, 2814 Franklin Road, SW, Roanoke, VA 24014, USA

ARTICLE INFO

Article history:

Received 26 March 2013

Received in revised form 8 July 2013

Accepted 16 July 2013

Available online 29 July 2013

Keywords:

Adrenocortical disease (ACD)

Adrenal hormones

Domestic ferret

GonaCon

Gonadotropin-releasing hormone (GnRH)

Mustela putorius furo

ABSTRACT

Adrenocortical disease (ACD) is a common problem in surgically sterilized, middle-aged to old ferrets (*Mustela putorius furo*). The adrenal tissues of these ferrets develop hyperplasia, adenomas, or adenocarcinomas, which produce steroid hormones including estradiol, 17-hydroxyprogesterone, and androstenedione. Major clinical signs attributable to overproduction of these hormones are alopecia (hair loss) in both sexes and a swollen vulva in females. Pruritus, muscle atrophy, hind limb weakness, and sexual activity or aggression are also observed in both sexes. Males can develop prostatic cysts, prostatitis, and urethral obstruction. ACD is thought to be linked to continuous and increased LH secretion, due to lack of gonadal hormone feedback in neutered ferrets. This continuous elevated LH acts on adrenal cortex LH receptors, resulting in adrenal hyperplasia or adrenal tumor. This study investigated whether the immunocontraceptive vaccine GonaCon™, a GnRH vaccine developed to reduce the fertility of wildlife species and the spread of disease, could prevent or delay onset of ACD and treat alopecia in ferrets with existing ACD. Results showed that GonaCon provided relief from ACD by causing production of antibodies to GnRH, probably suppressing production and/or release of LH. Treatment caused many ACD symptoms to disappear, allowing the ferrets to return to a normal life. The study also found that the probability of developing ACD was significantly reduced in ferrets treated with GonaCon when young (1–3 years old) compared to untreated control animals. GonaCon caused injection site reaction in some animals when administered as an intramuscular injection but caused few side effects when administered subcutaneously. Both intramuscular and subcutaneous vaccination resulted in similar levels of GnRH antibody titers. Subcutaneous vaccination with GonaCon is thus recommended to prevent the onset of ACD and as a possible treatment for ACD-signs in domestic ferrets.

Published by Elsevier Ltd.

1. Introduction

Adrenocortical disease (ACD) is a common problem in neutered, middle-aged to old pet ferrets (*Mustela putorius furo*) [6]. It has been shown that early neutering contributes to ACD [2–4]. Female domestic ferrets may develop their first estrus in spring of the year following their birth, often between 4.5 and 6 months of age [4]. Once a female has begun an estrus cycle, she may remain in estrus for an extended period of time if not bred, causing health problems, such as estrogen-induced anemia. For this reason, pet female ferrets are generally spayed [4]. Because of the musky smell and sexual

aggressiveness of intact males, most male pet ferrets are castrated and descented. Most pet ferrets in the U.S. are spayed or castrated early, between 5 and 7 weeks of age [2,4].

ACD is associated with continuous production of pituitary luteinizing hormone (LH) due to the lack of negative gonadal hormone feedback in neutered ferrets. Ferrets and a few other mammalian species have functional LH receptors in the adrenal cortex [1]. Therefore, in neutered ferrets, unregulated elevation of LH stimulates the adrenal LH receptors, resulting in enlarged adrenals and ACD [1]. Enlarged adrenal glands produce several sex hormones including estradiol, 17-hydroxyprogesterone, and androstenedione. In early stages of ACD, these elevated hormones reduce hair growth in both sexes [3–6], resulting in generalized, patchy alopecia primarily involving the trunk. Other clinical signs of ACD are pruritus (itching), muscle atrophy, hind limb weakness, sexual activity or increased aggression. Males can develop prostatic cysts, prostatitis, and urethral obstruction. In rare cases, lethal bone

* Corresponding author. Tel.: +1 970 266 6161; fax: +1 970 266 6157.

E-mail addresses: Lowell.a.miller@aphis.usda.gov (L.A. Miller), Kathleen.a.fagerston@aphis.usda.gov (K.A. Fagerstone), bwagner@pitt.edu (R.A. Wagner), finklerrah@cox.net (M. Finkler).

marrow suppression may occur. The activated adrenal glands frequently develop hyperplasia and may become neoplastic in the form of adenomas and adenocarcinomas. The malignant tumors frequently expand and may metastasize, with lethal consequences.

Until recently, surgical removal of affected adrenal gland(s) was the primary form of treatment for ferret ACD. In the hands of an experienced veterinary surgeon, removal of the left adrenal is relatively easy and has a low risk associated with the adrenalectomy surgery. Due to the position of the right adrenal, near several blood vessels, its removal is more difficult. Surgical intervention of bilateral disease carries significant risk of post-operative complications. In many instances inherent risk concerns related to adrenalectomy, as well as the cost of surgery, are deterrents to use of surgery to cure ACD [7].

GnRH agonists can be effective in treating ferrets with ACD. These agonists have a higher affinity for GnRH receptors than the endogenous GnRH. When given over long periods of time in a slow release formulation, agonists cause down-regulation of pituitary gonadotrophs and significantly reduce secretion of LH and FSH. Two agonists, leuprolide acetate (Lupron™) and deslorelin acetate (Suprelorin™) have been shown to reduce sex hormones in ferrets and subsequent ACD, resulting in hair regrowth [8–10]. These agents are effective as long as a threshold concentration of the agonist can be maintained in the body.

Another product with potential to treat ACD is the immun contraceptive GnRH vaccine GonaCon, developed as a reproductive inhibitor for wildlife by the United States Department of Agriculture (USDA), National Wildlife Research Center (NWRC) [11]. In brief, the vaccine consists of numerous GnRH peptides conjugated in a systematic manner to a mollusk hemocyanin protein. This GnRH-mollusk conjugate is emulsified in a water-in-oil emulsion with a mineral oil adjuvant (AdjuVac) also developed at the National Wildlife Research Center.

GonaCon vaccine reduces available endogenous GnRH by stimulating production of antibodies that neutralize GnRH released from the hypothalamus in the vasculature between the hypothalamus and the anterior pituitary gland (add reference). Because of the reduction in available GnRH, we hypothesize that secretion of LH and FSH by the anterior pituitary is reduced. In females of many species [20], follicular development, ovulation, and estrus are inhibited; in males, testosterone levels are reduced, testicular size and aggressive behavior decrease significantly, and no interest is shown in estrous females. As long as antibody titers to GnRH are sufficiently elevated, reproductive behavior will be suppressed and the contraceptive effect will last in both sexes [11]. GonaCon has induced contraception with a single shot for 1–6 years in many mammalian species, including California ground squirrels (*Spermophilus beecheyi*) [12], domestic cats (*Felis catus*) [13], black-tailed prairie dogs (*Cynomys ludovicianus*) [14], domestic and feral swine (*Sus scrofa*) [15,16], wild horses (*Equus caballus*) [17], bison (*Bison bison*) [18], and white-tailed deer (*Odocoileus virginianus*) [19].

GonaCon is currently registered with the US Environmental Protection Agency as a contraceptive for use in white-tailed deer and wild horses. The primary uses of GonaCon are to resolve human-wildlife conflicts through management of overabundant wildlife populations [20] and to prevent disease transmission for sexually transmitted diseases such as brucellosis [18].

The objectives of this study were:

To test effects of GonaCon on the concentration of steroid hormones in ferrets affected by ACD.

To determine whether GonaCon could be used to treat alopecia in ferrets affected by ACD.

Table 1

Effect of treatment with GonaCon on hormone concentration in 9 neutered ferrets diagnosed with adrenal cortical disease (ACD).

Hormone	Normal range ^a	Pre-treatment	Post-treatment ^b
		Mean ± SEM	Mean ± SEM
Estradiol (pmol/L)	30–180	207(±29.6)	106(±8.5)
Androstenedione (nmol/L)	1–15	87(±22.3)	6.3(±1.3)
17-OH progesterone (nmol/L)	0.5–0.8	7.6(±2.6)	0.28(±0.8)

^a Normal hormone concentration values for ferrets [3,5].

^b Paired *T* test run for each hormone, all significant at *P* < 0.05. GonaCon post-treatment samples were drawn 2–3 months after injection.

To assess whether GonaCon, administered to juvenile, healthy ferrets, could be used to prevent the onset of ACD in surgically sterilized animals.

To test potential side effects and effectiveness of GonaCon administered through intramuscular (IM) or subcutaneous (SC) injection.

2. Materials and methods

2.1. Trial 1: effects of GonaCon as a treatment for ACD

A small study was conducted to determine whether GonaCon would be effective as a treatment for ACD in ferrets, as measured by regrowth of hair and decrease in adrenal hormones. Nine ferrets (3.5–6 years of age) with ACD (showing 100% alopecia and elevated adrenal sex hormones) were given one 500 µg vaccination with GonaCon intramuscularly using a 22 gauge, ½ inch-long needle in the neck. Regrowth of hair in these animals was monitored for four months.

The effect of GonaCon on adrenal hormones was measured by collecting blood samples from ferrets at vaccination and 2–3 months later. Serum was harvested by centrifugation and stored frozen at –20 °C until assays were conducted. Pre- and post-treatment serum was sent to the Clinical Endocrinology Service at The University of Tennessee, College of Veterinary Medicine, Knoxville, TN, a facility which has validated the radio-immunoassays for adrenal hormone concentrations in ferrets [3]. Serum samples were analyzed for estradiol, androstenedione, and 17-hydroxyprogesterone concentrations, which were compared with established reference range values for ferrets [3,5] (Table 1). A paired *T* test was used to test for differences in pre- and post-treatment hormone levels. Serum was used to determine antibody titers to GnRH by ELISA methods previously described [21], with the following changes: 200 ng antigen was used per well and all wells were blocked with a solution of 20% SEA BLOCK (Thermo Fisher Scientific, Rockford, IL, USA) and 5% Tween 20 in 0.01 M PBS.

2.2. Trial 2: effects of GonaCon administered intramuscularly and subcutaneously to prevent ACD

After determining that treatment with GonaCon could reduce symptoms of ACD in a manner similar to that observed by use of deslorelin, a large study was started to determine if GonaCon could prevent or delay the development of ACD that occurs in middle or old age ferrets. The hypothesis was that GonaCon could prevent the uncontrolled elevation of LH in young neutered ferrets and thereby prevent adrenal hyperplasia and the progressive symptoms of ACD. Privately-owned ferrets (*N* = 88) aged 1.0–3.5 years were enrolled in the study. Spayed females (*n* = 46) and neutered males (*n* = 42) entered into the study were free of health problems during the initial physical exam; ferrets did not have clinical signs or behaviors suggestive of adrenocortical disease (e.g., no alopecia, excessive pruritus, swollen vulva or prostate, stranguria, or signs of libido). The ferrets remained with the clients so neither diet

nor photoperiod was standardized during the study. Thirty-three ferrets were given an IM injection of 0.5 ml (500 µg) of GonaCon at the beginning of the study. Because some of the ferrets vaccinated IM (see below) developed injection site reactions, the other 55 ferrets in the study were given an SC injection. Boosts were given SC. The vaccinated ferrets were compared to 125 unvaccinated ferrets in the same age range that were free of ACD symptoms. The study was conducted over an eight-year period through records kept by several exotic pet veterinary clinicians.

Ferrets were vaccinated 1 to 3 times in a 3-year period; 27 ferrets were vaccinated twice and 13 were vaccinated 3 times. Before vaccination and between 1 and 3 months post vaccination, blood was collected from a subset of 40 animals for analyses of GnRH antibody concentrations as described above. A single injection of the vaccine proved effective in maintaining antibody titers so the remaining ferrets were not revaccinated. Titers did not differ between animals injected IM or SC so those data were pooled. The cumulative percentages of control and GonaCon-vaccinated ferrets developing ACD were plotted as curves. Fischer's exact test was used to test differences between percentages of ferrets with ACD of control versus treated ferrets for each year.

2.3. Trial 3: effects of GonaCon administered subcutaneously to prevent ACD

Occasionally a ferret given an IM injection in the previous study developed a severe injection site reaction, consisting of sterile pyo-granulomas, which slowly went away with symptomatic treatment. To determine if SC injections would cause fewer injection site reactions, 13 neutered ferrets (6 males and 7 females) 2–3 years of age without signs of ACD were injected subcutaneously with 0.5 ml (500 µg) of GonaCon on the dorsal scruff of the neck and blood drawn for determination of anti-GnRH titers. One year later ferrets were clinically evaluated, given a boost injection of GonaCon, and blood was again drawn. The injection site reactions were examined and effectiveness of the vaccine was measured through the level of GnRH antibody titers.

3. Results

3.1. Trial 1: effects of GonaCon administered to ferrets with ACD

Adrenal hormone levels in ferrets with ACD were significantly higher than normal ($P < 0.05$) (Table 1). Treatment with GonaCon caused adrenal hormones (estradiol, androstenedione and 17-hydroxyprogesterone) to return to their normal range within 3 months following vaccination. The drop in hormone levels was accompanied by improvement in clinical condition of neutered ferrets. The main clinical improvement was re-growth of hair in early stages of the disease (Fig. 1). Within 3 months after the GonaCon vaccination, most ferrets had anti-GnRH titers of 1:128,000. These high titers were associated with improvement of pelage from total alopecia (no hair) to 100% body hair (Table 2). Ferrets with lower titers (1:8000–1:32,000) had less hair growth (20–80% at 2 months) but still showed improvement, especially 3 months or more after treatment (60–90%). For other clinical signs of ACD there was a wide range of responses; many clinical signs, including swollen vulva in females, and pruritus, muscle atrophy, hind limb weakness, and sexual activity or aggression, did not completely resolve after the GonaCon injection.

3.2. Trial 2: effects of GonaCon administered IM or SC to prevent ACD

Control ferrets developed ACD significantly earlier than treated ferrets. The difference was significant for every year but more

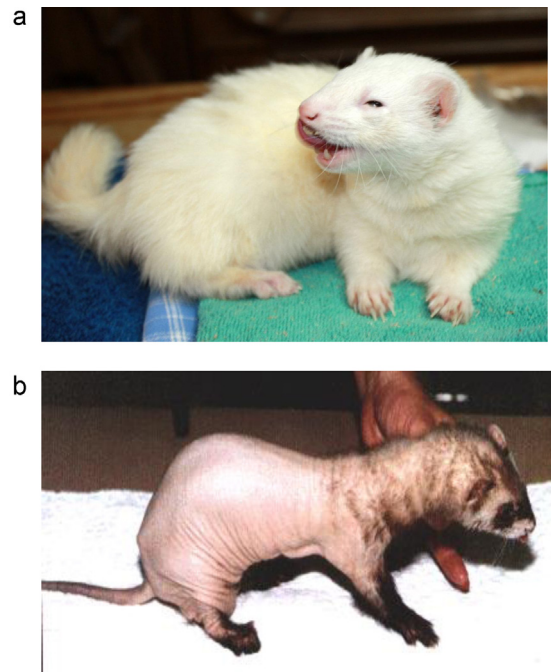


Fig. 1. (a) Ferret with normal pelage (100% hair) after GonaCon treatment. (b) Ferret with alopecia caused by adrenal cortical disease.

pronounced over time (year 1, $P < 0.003$, years 2–8 $P < 0.001$). The percentage of control ferrets (initial $n = 125$) showing signs of ACD (and number alive for each year) were 21% ($n = 101$), 64% ($n = 53$), 80% ($n = 33$), and 84% ($n = 25$) by 2, 4, 6 and 8 years, respectively (Fig. 2). This compares to percentages for treated ferrets (initial $n = 88$) of 1% ($n = 86$), 8% ($n = 79$), 20% ($n = 49$), and 24% ($n = 25$) at 2, 4, 6 and 8 years, respectively.

Most of the 1–3-month post vaccination titers were 1:128,000 or greater (64.3%), with other animals having titers of 1:8000 (2.4%), 1:32,000 (9.5%), and 1:64,000 (19%). There were 2 nonresponders (4.8%) with no measurable titers, one of which developed ACD 3 years after vaccination. Titers for ferrets were lower after one year, with the majority of animals maintaining titers of 1:32,000 to 1:64,000, although some ferrets maintained higher titers of 1:128,000 for 2 years. With a boost, titers increased and were maintained at high levels for a minimum of 2–3 years (80% of ferrets maintained titers of 1:128,000 or greater).

Table 2

Effect of GonaCon treatment on hair regrowth in 9 ferrets diagnosed with ACD and showing alopecia. This table shows the relationship of the anti-GnRH titer to hair regrowth (100% = full hair) at 2 months post treatment and hair growth at >3 months post-treatment.

2-Month GnRH titer	Hair growth	
	2-Month	≥3-Month
128,000	100%	100%
128,000	100%	100%
128,000	100%	100%
128,000	100%	100%
128,000	100%	100%
32,000	80%	90%
32,000	80%	80%
32,000	40%	60%
8000	20%	80%

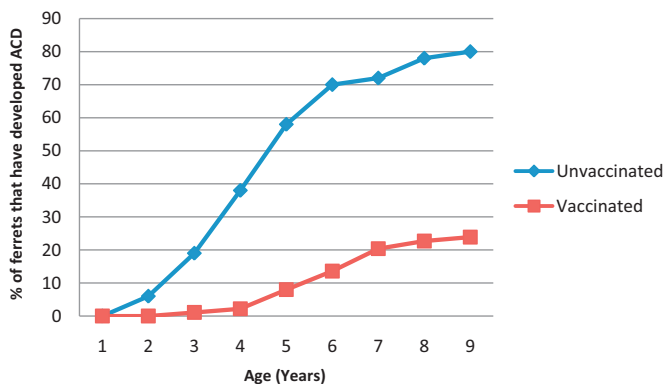


Fig. 2. Cumulative percentage of ferrets vaccinated in an ACD prevention study with GonaCon ($N=88$) versus control animals ($N=125$) that developed adrenal cortical disease over an 8-year period. Fisher's exact test was performed for each year (year 1, $P=0.04$, years 2–8 $P<0.0001$).

3.3. Trial 3: effects of GonaCon administered subcutaneously to prevent ACD

GnRH antibody titers in all 13 ferrets administered GonaCon by an SC injection were high (1:128,000) one year after treatment. At this time all ferrets were clinically normal with 100% pelage and no signs of ACD. At year 2, titer levels for 8 of the ferrets increased to 1:256,000 and titer levels for 5 ferrets remained at 1:128,000. None of the ferrets had injection site reactions other than an occasional firm raised subcutaneous nodule 0.5–1 cm in diameter to either the prime or boost doses detectable on clinical examination after two years and none had signs of ACD.

4. Discussion

Clinical signs of ACD in neutered ferrets correlate with increased levels of LH, which causes loss of body hair (alopecia) and elevated levels of adrenal hormones in serum. GonaCon in these trials acted as a treatment and preventive vaccine for ACD by decreasing the concentration of adrenal steroid hormones.

An advantage of GonaCon is that it provides an immune response for at least a year based on a single injection. As a treatment for ACD it was effective within two months following vaccination, with elevated adrenal sex hormones common to ACD returning to normal and ferrets with 100% alopecia regaining 60% or more of their hair within a 4-month period; those animals with highest GnRH antibody titers regained 100% of their hair and some resolved other clinical signs. However, GonaCon did not completely resolve some ACD clinical signs in all ferrets, including complete hair regrowth, pruritus, swollen vulva or aggressive behavior.

Treatment with GonaCon produces results similar to treatment with a GnRH agonist (e.g., deslorelin), which is lowering the unregulated elevation of plasma LH. However, the process by which this is accomplished in the two products is quite different. The GnRH agonists down-regulate LH receptors to reduce the level of circulating LH. In contrast, GonaCon vaccine reduces the availability of endogenous GnRH, thereby reducing the GnRH activated release of LH, and reducing levels of circulating LH. Deslorelin has been shown to be effective as a treatment for ACD. This study has shown that GonaCon is less effective than GnRH agonists (Lupron and deslorelin) in treating ACD, despite reversing alopecia in many animals. Clinical signs are not resolved as quickly with GonaCon as with the GnRH agonist. GonaCon is also less effective than deslorelin in treating other clinical signs of ACD, perhaps because once adrenal glands have become neoplastic, their production of sex hormones becomes autogenous, no longer dependent upon external stimulation by LH.

GonaCon was most effective in preventing ACD in ferrets that had not yet developed ACD. In the long-term ACD prevention study, GonaCon treatment resulted in a significant reduction in the percentage of ferrets which developed ACD; by 8 years of age the difference was striking (84% of untreated ferrets had ACD versus only 24% of treated ferrets). In many contraceptive studies with GonaCon in other species [15–21] it has been shown that one injection of GonaCon prevents the release of LH for a year or more.

Both IM and SC injection of GonaCon resulted in antibody titers that remained elevated for a year or more, providing clinical remission. The SC injections caused fewer and minor injection site reactions compared to IM injections. Many ferrets were given a second or third GonaCon injection during yearly clinical exams, ensuring continued remission from ACD. These ferrets had no injection site reactions relating to the yearly booster.

5. Conclusions

GonaCon has been demonstrated to be an effective, well-tolerated vaccine for preventing onset of ACD in ferrets. Although partially effective as an ACD treatment for ferrets, GonaCon did not eliminate all signs of ACD. The study also indicated that, to minimize side effects at the injection site, the vaccine should be administered SC rather than IM.

References

- [1] Schoemaker NJ, Teerdsb KJ, Mol JA, Lumeij JT, Thijssen JHH, Rijnberk A. The role of luteinizing hormone in the pathogenesis of hyperadrenocorticism in neutered ferrets. *Molecular and Cellular Endocrinology* 2002;197: 117–25.
- [2] Schoemaker NJ, Schuurmans M, Moorman H, Lumeij JT. Correlation between age at neutering and age at onset of hyperadrenocorticism in ferrets. *Journal of the American Veterinary Medical Association* 2000;216: 195–7.
- [3] Rosenthal KL, Peterson ME. Evaluation of plasma androgens and estrogen concentrations in ferrets with hyperadrenocorticism. *Journal of the American Veterinary Medical Association* 1996;209:1097–102.
- [4] Rosenthal KL, Peterson ME, Quesenberry KE, Hillyer EV, Beeber NL, Moroff SD, et al. Hyperadrenocorticism associated with adrenocortical tumor or nodular hyperplasia of the adrenal gland in ferrets: 50 cases (1987–1991). *Journal of the American Veterinary Medical Association* 1993;203:271–5.
- [5] Wagner RA, Dorn DP. Evaluation of serum estradiol concentrations in alopecic ferrets with adrenal gland tumors. *Journal of the American Veterinary Medical Association* 1994;205:703–7.
- [6] Johnson-Delaney CA. Ferret adrenal disease: 2006 perspective. *Exotic DVM* 2007;8(3):31–3.
- [7] Weiss CA, Scott MV. Clinical aspects and surgical treatment of hyperadrenocorticism in the domestic ferret: 94 cases (1994–1996). *Journal of the American Animal Hospital Association* 1997;33:487–93.
- [8] Wagner RA, Bailey EM, Schneider JF, Oliver JW. Leuprolide acetate treatment of adrenocortical disease in ferrets. *Journal of the American Veterinary Medical Association* 2001;218:1272–4.
- [9] Wagner RA, Piche CA, Jochle W, Oliver JW. Clinical and endocrine response to treatment with deslorelin acetate implants in ferrets with adrenocortical disease. *American Journal of Veterinary Research* 2006;66: 910–4.
- [10] Wagner RA, Finkler MR, Fecteau KA, Trigg TE. The treatment of adrenal cortical disease in ferrets with 4.7 mg deslorelin acetate implants. *Journal of Exotic Pet Medicine* 2009;18:146–52.
- [11] Miller L, Rhyan J, Killian G. GonaCon. A versatile GnRH contraceptive for a large variety of pest animal problems. In: *Proceedings of the 21st vertebrate pest conference*. 2004. p. 269–73.
- [12] Nash PB, James DK, Hui LT, Miller LA. Fertility control of California ground squirrels using GnRH immunocontraception. In: *Proceedings of the 21st vertebrate pest conference*. 2004. p. 274–8.
- [13] Levy JK, Friary JA, Miller LA, Tucker SJ, Fagerstone KA. Long-term fertility control in female cats with GonaCon, a GnRH immunocontraceptive. *Theriogenology* 2011;76:1517–25.
- [14] Yoder CA, Miller LA. Effect of GonaCon vaccine on black-tailed prairie dogs: immune response and health effects. *Vaccine* 2011;29:233–9.
- [15] Miller L, Rhyan J, Killian G. Evaluation of a GnRH contraceptive vaccine using domestic swine as a model for feral hogs. In: *Proceedings of the 10th wildlife damage management conference*. 2003. p. 120–7.
- [16] Massei G, Cowan DP, Coats J, Bellamy F, Quay R, Pietravalle S, et al. Long-term effects of immunocontraception on wild boar fertility, physiology and behavior. *Wildlife Resources* 2012;39:378–85.

- [17] Killian G, Thain D, Diehl NK, Rhyan J, Miller L. Four-year contraception rates of mares treated with single injection porcine zona pellucida and GnRH vaccines. *Wildlife Resources* 2008;35:5312–9.
- [18] Miller LA, Rhyan JC, Drew M. Contraception of bison by GnRH vaccine: a possible means of decreasing transmission of brucellosis in bison. *Journal of Wildlife Diseases* 2004;40:725–30.
- [19] Miller LA, Gionfriddo J, Fagerstone KA, Rhyan J, Killian G. The single-shot GnRH immunocontraceptive vaccine (GonaCon™) in white-tailed deer: comparison of several GnRH preparations. *American Journal of Reproductive Immunology* 2008;60:214–23.
- [20] Fagerstone KA, Miller LA, Yoder CA. Review of issues concerning the use of reproductive inhibitors, with particular emphasis on resolving human-wildlife conflicts in North America. *Integrative Zoology* 2010;1:15–30.
- [21] Miller LA, Johns BE, Killian GJ. Immunocontraception of white-tailed deer with GnRH vaccine. *American Journal of Reproductive Immunology* 2000;44:266–74.