

University of Nebraska - Lincoln

## DigitalCommons@University of Nebraska - Lincoln

---

Studies from the Zoological Laboratory: The  
University of Nebraska

Parasitology, Harold W. Manter Laboratory of

---

3-2-1895

### The Asiatic Lung-Distome in the United States

Henry B. Ward

*University of Nebraska - Lincoln*

Follow this and additional works at: <https://digitalcommons.unl.edu/zoolabstud>



Part of the [Parasitology Commons](#), and the [Zoology Commons](#)

---

Ward, Henry B., "The Asiatic Lung-Distome in the United States" (1895). *Studies from the Zoological Laboratory: The University of Nebraska*. 19.

<https://digitalcommons.unl.edu/zoolabstud/19>

This Article is brought to you for free and open access by the Parasitology, Harold W. Manter Laboratory of at DigitalCommons@University of Nebraska - Lincoln. It has been accepted for inclusion in Studies from the Zoological Laboratory: The University of Nebraska by an authorized administrator of DigitalCommons@University of Nebraska - Lincoln.

THE ASIATIC LUNG-DISTOME IN THE  
UNITED STATES.

BY

HENRY B. WARD, PH.D.,  
UNIVERSITY OF NEBRASKA, LINCOLN, NEB.

---

FROM

THE MEDICAL NEWS,

March 2, 1895.

[Reprinted from THE MEDICAL NEWS, March 2, 1895.]

---

**THE ASIATIC LUNG-DISTOME IN THE UNITED STATES.**

BY HENRY B. WARD, PH.D.,  
UNIVERSITY OF NEBRASKA, LINCOLN, NEB.

---

IN 1893 I reported<sup>1</sup> the occurrence of the Asiatic distome in the lungs of a cat examined in Ann Arbor, Mich. This was the first reported find of this species on this continent, and the possibility of its being a permanent guest in this country was so serious that I urged a careful examination of all cases of lung-parasites in the domestic animals, with a view to ascertaining whether this might be an isolated instance, or whether the parasite was actually established within our land, for it is true that the Chinese, among whom the parasite is very common, regard cats as great pets, and this single cat, of whose antecedents nothing was known, *might* have been brought to this country as a pet, and have wandered from its owner afterward.

In an extract<sup>2</sup> sent me this fall was a notice of an unknown distome found in the lungs of a dog. The description led me to suspect at once that it was *Distoma Westermanni*, and in response to my request Prof. Kellicott very kindly sent me some specimens

---

<sup>1</sup> In the *Centralblatt für Bakteriologie und Parasitenkunde*, Bd. xv, pp. 362-64; also in the *Veterinary Magazine*, vol. i, pp. 355-59.

<sup>2</sup> D. S. Kellicott: "Certain Entozoa of the Dog and Sheep." *Trans. Ohio State Med. Society*, 1894.

for examination. The study of these shows beyond question their identity with the form found in Ann Arbor and with the Asiatic species. The animal from which they were taken was "a shepherd dog from the country near Columbus, Ohio." Both the host and the locality from which it came render the possibility of its having been imported from the East practically *nil*, and to my mind demonstrate the establishment of the parasite in this country.

The existence of a new human parasite within our land, and especially of one so dangerous in its home as this distome, is a matter of sufficient importance to the medical profession to call for the publication in this place of some facts concerning its anatomy and development, as well as its diagnosis and frequency, together with other biologic data, especially as references to it are wanting in most American works.

In 1880 Bälz, a European physician, reported the common occurrence of parasitic hemoptysis in Japan, which, though ascribed to tuberculosis, was due, he thought, to a gregarine. Soon afterward he recognized the objects which he had taken for psorosperms as distome eggs, and was able to publish in 1883 a description of the parasite under the name of *Distoma pulmonale*. Later Leuckart demonstrated the identity of this form with a distome from the lung of a Bengal tiger that had died in the zoologic gardens at Amsterdam. This distome had been carefully studied and described in 1878 by Kerbert<sup>1</sup> under the name of *Distoma Westermanni*,

---

<sup>1</sup> Zool. Anz., i, pp. 271-73; later also in Archiv f. mikr. Anatomie, Bd. xix, pp. 529-578.

which has the right of priority, and must be retained as the name of the parasite according to the

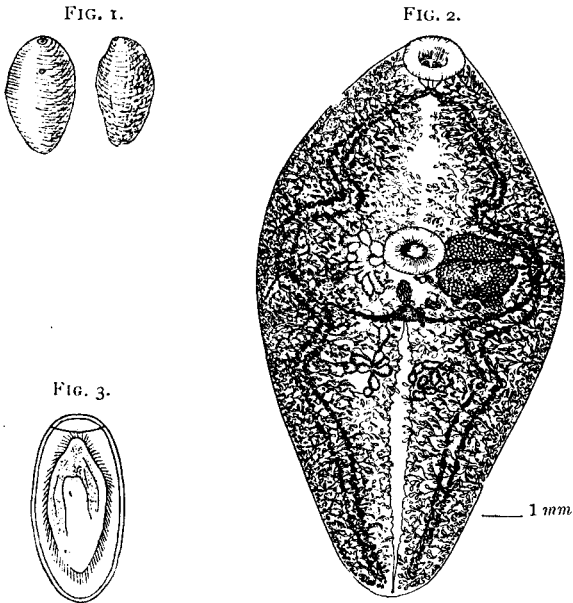


FIG. 1.—*Distoma Westermanni*; ventral and lateral views (after Leuckart). Natural size.

FIG. 2.—*Distoma Westermanni* from the ventral surface. Specimen from Columbus, O., mounted in balsam. Original. Magnified 5½ times.

FIG. 3.—Egg of *D. Westermanni* with embryo. (From Leuckart after Nakahama.) Magnified 225 times.

established laws of zoologic nomenclature. On its presence and importance among the Eastern nations there has appeared a long list of papers largely in-

accessible to the American physician. Dr. C. W. Stiles, helminthologist of the Bureau of Animal Industry at Washington, D. C., published,<sup>1</sup> in connection with a note on the original discovery of this parasite in the United States, a valuable bibliography of the species. The most important of these articles are those of Leuckart<sup>2</sup> and Yamagiwa,<sup>3</sup> from which, together with the papers of Kerbert and Stiles, and my own studies on the forms found in the United States, the following account was prepared.

*Distoma Westermanni* Kerbert 1878. Synonyms: *D. Ringeri* Cobbold, 1880. *D. pulmonis* K., S. and Y., 1881. *D. pulmonale* Bälz 1883. *Mesogonimus Westermanni* Railliet 1890.

Length, 8 to 10 mm. (Leuckart); 11 to 16 mm. (Ward); 15 to 20 mm. (Kellicott.) Breadth, 4 to 6 mm. (Lkt.); 5 to 7 mm. (Wd.); 6 to 8 mm. (Kct.). The body is thick and plump, somewhat resembling a dipterous larva in shape (Fig. 1), with the posterior end more pointed than the anterior, and the ventral surface much flatter than the high arched dorsal. In color the living distome is deep red or reddish-brown, darker along the middle of the body; the alcoholic specimen is dark steel-gray at the sides, with a brighter band along the center; the black dendritic acini (Fig. 2) of the vitelline gland can be easily recognized with a hand lens. The cuticula is everywhere covered by broad flat

<sup>1</sup> Johns Hopkins Hospital Bulletin, No. 40, May, 1894.

<sup>2</sup> Parasiten des Menschen, ii. Aufl., Bd. 1, pp. 404-440.

<sup>3</sup> Virchow's Archiv f. pathol. Anat. u. Physiol., Bd. cxxvii, pp. 446-456.

spines of varying length and size, which are lacking in poorly-preserved specimens.

The suckers are notably small and often difficult to see. The oral sucker has a mean diameter of 0.53 mm. (Lkt.), or 1.2 mm. (Wd.) for the American variety. It is not situated at the exact anterior extremity of the body, but is slightly subterminal, and its orifice is directed downward. The ventral sucker, or acetabulum, is a little larger than the oral, being 0.65 to 0.75 mm. in diameter (Lkt.), or smaller, 0.75 to 1 mm. (Wd.). It will be noticed that the oral was smaller in the specimens examined by Leuckart, whereas in those from Ann Arbor the reverse obtained. In the specimens from Columbus the oral suckers average 0.864 by 1.017 mm. and the ventral 1.17 by 1.31 mm., relatively the same as in the Asiatic form, but absolutely much larger. I should like to emphasize in this connection the extreme uncertainty of description based solely or even largely upon the size of organs as variable as a purely muscular sucker. Such descriptions are unfortunately very common in various quarters at present, and serve too frequently as a model for the description of new forms. For the accurate description of a species topographic relations are essential, as they are also for any identification of it subsequently. In no other way can a form be positively identified, and hence a short summary of these relations in *Distoma Westermanni* is here presented.

The general anatomy of the internal organs can easily be studied from specimens lightly stained and mounted in balsam (compare Fig. 2). Connected with the oral sucker, and lying partly at least upon it,

is the prominent pharynx; it is about half as long as the diameter of the oral sucker. The esophagus, which follows directly upon the pharynx, is short, and from its end arise almost at right angles the two crura intestini, which extend in a somewhat winding course to the posterior end of the body. The clear, irregular band through the center of this part of the worm indicates the position of the excretory sinus, a longitudinal tube varying much in caliber; it is filled from numerous canals along its sides, and opens almost at the posterior tip of the body.

The tissue of the body just below the surface is filled by the numerous acini of the vitellaria or yolk-glands, which impart to the lateral areas their dark, crowded appearance. These glands empty by longitudinal ducts into the two transverse ducts just behind the acetabulum. At the center, where these transverse ducts unite, is situated the vitelline reservoir. The ovary is a lobed organ at the right of the center immediately adjacent to the acetabulum; and a corresponding position on the left is taken by the condensed coils of the uterus, which are filled with yellow, thin-shelled eggs.

The testes, two in number, are located, one on either side of the excretory sinus, half-way from the acetabulum to the posterior end of the body. They are deeply-lobed organs, and are indistinct in outline in unstained specimens. Their ducts, which are not represented in Fig. 2, can be made out only with difficulty. They run obliquely toward the median side of the uterus coil, where they join and open at the common genital pore, which is situated immediately behind the acetabulum and a little to



the left of the median line. There is no prominent copulatory organ in this species.

The eggs, which may be seen in enormous masses in the uterus, or found free on the surface of the worm, or in the immediate vicinity of it, are oval, yellow, and provided with a thin shell, which has a cover (Fig. 3). They measure 0.08 to 0.1 mm. in length by 0.05 mm. in breadth (Lkt.), or 0.096 to 0.118 by 0.048 to 0.055 mm. (Wd.). The oval ciliated embryo develops within the egg some time after it escapes from its host. "The fate of these embryos," says Leuckart (*loc. cit.*, p. 436), "is at present entirely unknown. That they wander directly into the later host contradicts all analogy. They will probably, as is known of other forms, next seek an intermediate host, and in this produce a generation of cercariæ, which then for the first are brought in one manner or another into a man, whether directly into the lung, as Bälz assumes, is at least questionable. Much more probable is it that the residence in that organ is the result of a further migration."

*Distoma Westermanni* has been found in the lungs of the tiger, cat, and dog, as well as man. The description given by Kellicott (*l. c.*, p. 3) will give a good idea of the general appearance of the infected organ. He says: "On opening the thorax the lungs were found to present unusual appearances: small grown spots were thickly distributed over the entire surface of the pleura, and scattered over the lobes were many tumor-like swellings of a deep red color, contrasting strongly with the general pink of the lung. The tumors were mostly about the roots and along the dorsal borders of both sides. On cutting

open the tumors distomes were found within ; some were surrounded by a capsule, while others were burrowing after the fashion of the large distomes in the livers of sheep and cattle. These burrows were filled with débris and pus." Yamagiwa, who was a member of the Royal Japanese Commission for the investigation of the disease in that country, has given an account of the appearance of the human lung in several cases of post-mortem examination ; but the general characters were the same. He also calls attention to the occasional discovery of the parasite encysted in the liver, peritoneum, mesentery, and even in the cerebral hemispheres. In the lung they appear to be confined to the periphery of the organ and inclosed in special cysts which contain not only the distomes, but also eggs and masses of Charcot's crystals. These cysts communicate with the bronchi by fine openings through which the eggs and the crystals already mentioned reach the exterior in masses of mucus and blood. The number of eggs discharged in the course of a single twenty-four hours by a patient who had suffered thirteen years from the disease was estimated to be *not less than twelve-thousand!*

*Symptomatology.* When in the lungs, its common abiding place, the distome gives rise to periodic hemoptysis and chronic cough, with rusty mucoid expectoration. The condition of the patient remains good, and almost no abnormal sounds can be detected by percussion of the chest. Yamagiwa says that the general appearance of the expectorations is identical with that in tuberculosis, and, as a matter of fact, the disease was formerly diagnosed

as tuberculosis in Japan. The presence in the sputa of the eggs already described and figured is the only characteristic symptom, and positive diagnosis will rest then on the microscopic examination of the sputa, which will reveal, in case the parasite be present, numbers of its yellow-brown egg-shells. When one considers the prevalence of so-called tuberculosis in this country, and the frequently careless diagnosis of many, it is not at all unlikely that cases of this parasite may have been mistaken for tuberculosis, as Yamagiwa says was formerly the case in Japan. And this is the more probable, as the presence of such lung-parasites and the concurrent symptoms are doubtless unknown to many, and to most others are a matter of interest rather than important enough to deserve their careful attention, even though they may have heard of its occurrence in the far East.

The accidental rupture of a large bloodvessel by the destruction of the lung-tissue, and, in the severest cases, general anemia seem to be the only dangers to be feared. On removal from an infected district patients have apparently entirely recovered. During the continuance of the disease almost every patient suffers from malaise.

With regard to the region in which this parasite exists it may be said that Japan, China, Corea, and Formosa are known to be seriously infected. In one district of Japan, according to Bälz, almost every inhabitant suffered. In Formosa 15 per cent. of the entire population was infected. No doubt the disease is at home in the entire eastern portion of Asia, but exact knowledge of this region is lack-

ing. According to the report of the Japanese Commission, those affected are largely laborers, and men rather than women.

Of the means by which the parasite reaches the lungs nothing is known, and the statement of Yamagiwa that the drinking-water is at fault rests on rather uncertain ground: the observation that in a certain town those affected drank from a single stream.

In regard to the parasite in our own country it is not necessary to emphasize the importance of immediate investigation as to the region in which it is established, and of efforts to stamp it out, or at least to keep it within its present bounds. No less important is a full knowledge of its life-history, that the means of infection may be accurately known, and by wide publicity its spread be prevented so far as is possible. For both of these ends all cases of the disease should be reported with as little delay as possible, and care should be exercised to investigate every case of lung-parasite, so that an accurate opinion as to its character may be given. In any case I shall be glad to receive specimens of suspected parasites for determination.