

University of Nebraska - Lincoln

DigitalCommons@University of Nebraska - Lincoln

---

Canadian Cooperative Wildlife Health Centre:  
Newsletters & Publications

Wildlife Damage Management, Internet Center for

---

July 2000

## Canadian Cooperative Wildlife Health Centre, Volume 7-1, Summer 2000

Follow this and additional works at: <http://digitalcommons.unl.edu/icwdmccwhcnews>



Part of the [Environmental Sciences Commons](#)

---

" Canadian Cooperative Wildlife Health Centre, Volume 7-1, Summer 2000 " (2000). *Canadian Cooperative Wildlife Health Centre: Newsletters & Publications*. 42.

<http://digitalcommons.unl.edu/icwdmccwhcnews/42>

This Article is brought to you for free and open access by the Wildlife Damage Management, Internet Center for at DigitalCommons@University of Nebraska - Lincoln. It has been accepted for inclusion in Canadian Cooperative Wildlife Health Centre: Newsletters & Publications by an authorized administrator of DigitalCommons@University of Nebraska - Lincoln.

**Canadian  
Cooperative  
Wildlife  
Health Centre**



**Centre  
Canadien  
Coopératif de la  
Santé  
de la Faune**

Newsletter Volume 7 - 1, Summer 2000

In this issue:

**News from the CCWHC**

New Staff Member - Western/Northern Regional Centre

Surveillance for West Nile Virus - Summer 2000

**Feature Article**

Dorsal-spined Larvae in Cervids

**Regional Reports**

**Atlantic Region**

Organophosphate Pesticide Poisoning of Seagulls - St. John's, Newfoundland

Successful euthanasia of a juvenile fin whale

Psittacosis in Wild Rock Doves

**Quebec Region**

Walleye myopathy

The St-Lawrence beluga whale: summary of lesions detected in stranded individuals submitted for necropsy during 1999.

**Ontario/Nunavut Region Western/Northern Region**

An Epizootic of Iridovirus in Oregon Spotted Frog Tadpoles (*Rana pretiosa*)

Epidemic Avian Cholera in Double-Crested Cormorants in Saskatchewan

Winter Ticks in Stone's Sheep

California Bighorn Sheep in British Columbia

## News from the CCWHC

### New Staff Member - Western/Northern Regional Centre

In July, Dr. Marc Cattet joined the staff at Saskatoon. His position is partially to compensate for the heavy commitment by Dr. Trent Bollinger in coordinating a multi-agency study of avian botulism on the prairies. Dr. Cattet trained in Wildlife Biology (U. of Guelph, 1982), Ecology (U. of AB, 1988) and worked in the Northwest Territories and Ontario, before entering the Ontario Veterinary College, where he received a DVM in 1993.



After a short time in veterinary practice, Dr. Cattet began a study of the physiological and biochemical responses of polar bears to prolonged fasting at the U. of SK., and received his Ph.D. this spring. During his Ph.D., Dr. Cattet also collaborated with Dr. Nigel Caulkett, a veterinary anaesthesiologist and associate member of CCWHC, in development and testing of new drugs for immobilizing wild animals, and in assessing the effects of handling on animals. One aspect of Dr. Cattet's position with CCWHC is to assess the need for and feasibility of assistance of various types in the area of chemical immobilization and related animal handling as an expansion of CCWHC's services. Dr. Cattet can be reached at [marc.cattet@usask.ca](mailto:marc.cattet@usask.ca), or (306) 966-2162.

### Surveillance for West Nile Virus - Summer 2000

The appearance of West Nile Virus in wild birds and the death of humans in New York State in 1999, stimulated a very large multi-pronged surveillance program in Canada this summer. The CCWHC's role within the program was to organize and conduct an enhanced surveillance program for disease in wild birds from the AB-SK border eastward. This program was coordinated by Ian Barker (Ontario Regional Centre). With support from Health Canada, additional student assistants were placed in each of the four regional centres to help deal with the increased diagnostic case load. The provincial veterinary diagnostic laboratories of New Brunswick, Newfoundland and Labrador, and Nova Scotia also participated actively in the program. As of 2 October, 2093 birds had been examined, with the largest number of submissions made to the Ontario and Quebec Regional Centres. To date, no case of West Nile Virus has been recognized. A valuable "bycatch" of the program is that we have been able to add a great deal of information on other causes of wild bird mortality to the national database. For detailed information on West Nile Virus, visit the CCWHC website <http://wildlife.usask.ca> and see the CCWHC newsletter Vol. 6(2).

# Feature Article

## Dorsal-spined Larvae in Cervids

Dorsal-spined larvae (dsl) are what some might call the bane of existence for game ranchers, animal health regulators, and veterinarians required to take rectal samples from bull elk. What are dsl, where are they likely to occur, and is all the fuss warranted? Addressing the last question first will identify my bias. Mine is a position, however, that I suspect is shared pretty much by entrepreneurial farmers and those whose job it is to enforce animal health laws.

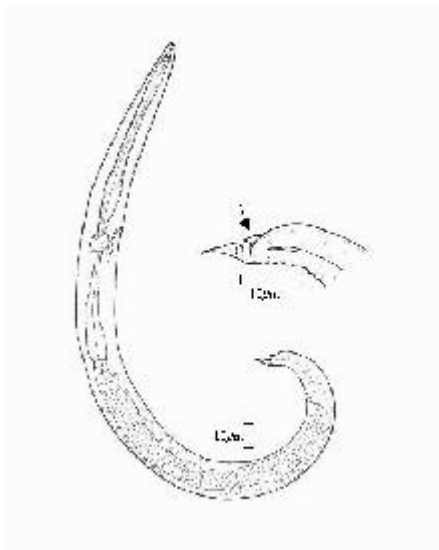


Fig. 1 adapted from: Lankester, M.W., V.J. Crichton, and H.R. Timmermann. 1976. A protostrongylid nematode (Strongylida: Protostrongylidae) in woodland caribou (*Rangifer tarandus caribou*). *Can. J. Zool.* 54: 680-684.

At least 3 species of nematodes that produce dsl in cervids are capable of causing serious disease in indigenous cervids. If it is possible to prevent their spread or introduction and thereby ensure the health of Canadian wildlife, then it is our responsibility to try.

These larvae have a distinct microscopic appearance. The end of their tail is kinked and ends in a sharp point (Fig.1). Dorsal to the kink, a sharp piece of body wall projects as a spine. The kinked tail and dorsal spine are thought to provide added purchase needed by the larva in penetrating the foot tissue of a terrestrial gastropod (snail or slug), in which development to the infective stage occurs.

Dorsal-spined larvae are produced by most members of a large family of parasitic nematodes, the Protostrongylidae. The family is known as the "lungworms" and, as adults, most do inhabit the lungs of ruminants. However, one of the best known lungworms, *Dictyocaulus*, is not a member of this family nor does it produce dsl. To further complicate things, the species of concern here (the sub-family Elaphostrongylinae) do not live in the lungs. Instead, they occur in either skeletal muscle or the central nervous system (CNS). But they retain the characteristics of all lungworms which is to use the lungs of their host as an exit route for larvae. In the CNS or muscles,

female worms inject their eggs into veins that eventually pass through the lungs. Eggs are filtered out, hatch and dislodge up the airways to the pharynx, are swallowed and passed out in feces. Larvae concentrate in the mucous film covering the pellet, rather than being mixed throughout the fecal material. This curious location, only on the surface, is presumed to be an adaptation that allows larvae to be washed off into the soil where survival is higher and gastropods are available. It is also the reason that only pelleted fecal samples can be used to reliably test for the larvae's presence.

This group of cervid parasites, the "extrapulmonary" lungworms, includes 3 species of the genus *Parelaphostrongylus* (*tenuis*, *andersoni* and *odocoilei*,) native to North America and 3 species of the genus *Elaphostrongylus* (*cervi*, *rangiferi* and *alces*) that evolved in Europe and Asia. Two of the latter species, however, have been spread elsewhere, including North America, by translocation of infected hosts. This article will describe the host and geographic distribution of these 6 species and the disease conditions they cause. Detailed information and citations for factual statements can be found in a soon to be published article (Lankester, M.W. Extrapulmonary lungworms of cervids. In: W.M. Samuel, M.J. Pybus, and A.A. Kocan (eds). Parasitic Diseases of Wild Mammals. Iowa State University Press, Ames, Iowa).

*Parelaphostrongylus tenuis*, the meningeal worm, occurs in almost 100% of wild white-tailed deer in eastern North America. For unknown reasons, its distribution excludes the southern portion of the US southeastern coastal states and FL. (Fig.2). The parasite has been reported as far west in Canada as northeastern SK and westward in the US to a line running south-east from the SK-MB border to north-eastern TX. Extension further west is believed to have been prevented by the dry central plains. Once beyond the plains, suitable gastropods and a flourishing white-tail population exist and there is no reason to think that *P. tenuis* could not become established in western North America, if it were introduced. The west also has valued populations of other native cervids, most of which are susceptible to parelaphostrongylosis.

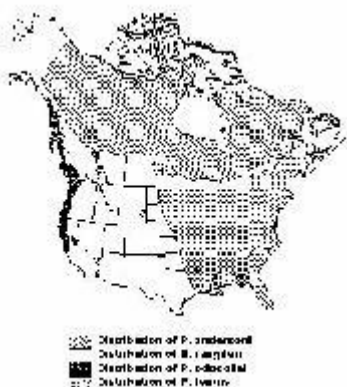


Fig. 2: Note - Both *E. rangiferi* and *P. andersoni* occur in NF.

In its normal host, the white-tailed deer, *P. tenuis* causes no noticeable disease. However, in most other native cervids and in several bovids and camelids, development in the CNS results in conspicuous neurologic signs ranging from lameness, fearlessness, depression

and weight loss to severe motor and sensory impairment (paresis, ataxia, stumbling, circling, blindness). All hosts are not equally susceptible to *Parelaphostrongylus* and severity of the disease is dose dependent. Among native cervids, caribou and mule deer are likely to show the most severe signs, followed by moose and then elk/wapiti. Impact of this parasite on moose and elk populations in eastern N. America has been difficult to quantify. Nonetheless, it is clear that as deer numbers increase, moose decline and this parasite is a contributing factor. Wapiti develop neurologic disease but a few introduced populations persist on deer range in the east. Of great concern are ranched elk that may survive infection and be a source of dsl. However, the greatest risk of spreading *P. tenuis* westward is presented by white-tails, an increasingly popular species in the game ranching industry.

*Parelaphostrongylus andersoni* and *P. odocoilei* are muscle worms and do not enter the CNS of their hosts. Hence, they cause no neurologic disease. Both, however, produce large numbers of eggs that hatch as larvae in the lungs, inducing an intense pneumonia. The impact of *P. andersoni* infection will be greatest in the young animals that can pass large numbers of larvae. Older animals seem to develop a resistance and may eventually overcome the infection. *P. odocoilei*, however, maintains high larval output in young and old animals. These worms apparently are long-lived.

*P. andersoni* was first found in white-tailed deer of the southeastern US (where *P. tenuis* is absent). Its distribution in this host beyond the southeast is spotty (NJ, MI, WY and southeastern BC) but probably is incompletely known. It is much more widespread in woodland and barren-ground caribou, having been found in this host from NF to northern AK. *P. odocoilei* is strictly a western parasite, occurring in mule deer of CA, southern BC and west-central AB. It is also found in black-tailed deer of the Pacific coast from CA into BC, including Vancouver island. This parasite also infects woodland caribou in west-central AB and has been implicated as a possible cause of death in mountain goats. It has recently been discovered in Dall's sheep in the NT by Dr. S. Kutz and colleagues (U. of Sask.).

A foreign parasite, *Elaphostrongylus rangiferi* was introduced into Canada in 1908 when Sir Wilfred Grenfell purchased infected reindeer in Norway to be used for food and as draught animals in NF. Upon arrival, the reindeer were herded across native caribou range and some escaped to join their close cousins. Most caribou herds in NF are now infected. A slightly longer larva, similar to that of *E. rangiferi*, has been reported in caribou of Labrador, but otherwise there is no evidence that this parasite has spread to mainland Canada. *E. rangiferi* is a serious pathogen of reindeer and caribou. Because it inhabits the CNS (like *P. tenuis*) conspicuous neurologic signs are a consequence of heavy infection. The resultant disease, cerebrospinal elaphostrongylosis (CSE), is characterized by lameness, head tilt, ataxia, and partial or total paralysis of the hind quarters. Lightly infected animals lose weight, fall behind the herd and appear confused or tame. Periodic outbreaks following warm moist summers, that are ideal for larval development in gastropods, are responsible for heavy losses in the reindeer industry in Fennoscandia. Young-of-the-year animals are affected mostly. A similar epizootic was seen in young caribou in central NF in the early 1980's. More recently, the parasite

finally spread to an isolated caribou herd on the Avalon Peninsula. The impact on this herd, that had no prior experience with the parasite, was dramatic. Cases of CSE were first seen in the Avalon herd in the late winter of 1995. Both calves and adult animals were affected. Reports of sick animals and numerous carcasses continued for the next 4 winters, during which time the herd declined from an estimated 7,500 animals to 1,850.

In Norway, this parasite also affects goats and to a lesser extent, sheep. Ironically, sporadic outbreaks of CSE in reindeer of Norway seem to be a thing of the past, thanks to the routine use of Ivermectin by herders. This drug does not kill all adult *E. rangiferi* but does suppress larval output. Its sustained use seems to have diminished the prevalence of the parasite. Unfortunately, this method of control is impractical in wild caribou of NF where the parasite is established.

When first discovered in Canada, this parasite was referred to as *Elaphostrongylus cervi*, since that was the name being followed at the time by European workers. However, more recently, it has been argued that the parasite in reindeer (and the one brought to Canada) is different from that found in other cervids of Europe and Asia. Workers have since returned to using its original name, *E. rangiferi*.

*Elaphostrongylus cervi* is a parasite of red deer, maral deer and Asiatic sika deer. It is found in the United Kingdom, Fennoscandinavia, Europe and in Asia (where it has been known as *E. panticola*). It was spread to New Zealand with red deer from the UK. More recently, infected red deer from New Zealand were identified upon entry into Australia and Canada. Presently *E. cervi* is not known to occur anywhere in North America.

This parasite is neurotropic and worms developing in the CNS, before moving into muscles, cause ataxia and hind-quarter weakness. Pneumonia, neurologic disease and lowered carcass value have been of greatest concern in deer farming operations in Asia. There appear to be differences in the pathogenicity of *E. cervi* across its range. In Europe, Fennoscandinavia and New Zealand, infected animals rarely show disease signs whereas epizootics of elaphostrongylosis periodically cause considerable economic loss on deer farms in Asia. The name *E. cervi* was first given to the form of the parasite found in red deer in Scotland and the name *E. panticola* to the form from Siberian red deer or maral deer and sika deer farmed in Kazakhstan. Although, most authors presently consider *E. panticola* to be a synonym of *E. cervi*, differences in pathogenicity due either to farming practices or host and parasite strain are possible. Nonetheless, the form of *E. cervi* present in New Zealand has been shown experimentally to cause neurologic disease in mule deer of North America.

The sixth (and last) recognized species of elaphostrongyline nematode is *E. alces*, known so far only in moose of Sweden, Norway and possibly Finland. Like other members of the genus *Elaphostrongylus*, this worm causes neurologic disease as a result of its close association with the CNS *en route* to skeletal muscles. The disease is believed responsible for declines in some moose populations in Sweden and natural infection of reindeer is also possible. It does not occur in North America.

Preventing spread of elaphostrongyline nematodes requires that infected cervid hosts can be reliably identified. This remains problematic although some progress has been made. Presently, a definitive diagnosis is only possible by killing the suspect host and recovering adult male worms. The standard method for recovering dsl from the feces of patent animals is improved by using the Baermann-beaker extraction method but the physical similarity of these larvae precludes identification based solely on morphometrics. Dr. A. Gajadhar and colleagues at the Canadian Food Inspection Agency (CFIA) have recently described an assay that does distinguish all species based on differences in their DNA. One or 2 larvae from a fecal sample are sufficient to make an identification. Still, this method is of no value in identifying an infected host that may only shed larvae intermittently or one that has not been infected long enough for adult worms to have matured and produced larvae. Some of these, so-called prepatent infections, can now be identified from a blood sample. Dr. O. Ogunremi of CFIA has developed an ELISA test that will identify white-tails, elk and moose infected with *P. tenuis* and elk infected with *E. cervi* as early as 16 days after infection.

Development of these tools is very encouraging but, as with most new methods, they require refinement and rigorous verification before widespread use is possible. As well, their specificity or ability to separate the elaphostrongyline nematodes from a few others such as *Varestrongylus alpenae* that produce dsl must be demonstrated. Meanwhile, knowledge of the host and geographic distribution of this important group of cervid parasites hopefully will assist efforts to prevent their further introduction and spread within Canada. (Murray W. Lankester, Department of Biology, Lakehead University, Thunder Bay, ON, P7B 5E1).

## Regional Updates

### Atlantic Region

#### Organophosphate Pesticide Poisoning of Seagulls - St. John's, Newfoundland

On Saturday, April 15th, 2000, reports were received from numerous sources of sick and dead herring gulls (*Larus argentatus*) around a city lake (Quidi Vidi Lake). Symptoms included vomiting, lethargy, drooped wings, paralysis and, in some cases, very alert birds that could not control their body movement but would defend themselves with their beaks. Throughout the remainder of the weekend and until approximately April 25th, affected birds were recovered from ponds and other spots in the St. John's area. In some cases, birds observed overnight would recover and eventually be released.

Investigations discovered that on Friday, April 14th, a cannister had exploded at the St. John's municipal landfill site due to the action of the landfill's compactor. The fluid that hit the compactor and accompanying bulldozer was, according to the equipment operators, orange- yellow with a noxious odor. Employees washed down the equipment



and worked elsewhere on the site for the remainder of the day. No samples were available for analysis from the equipment or the cannister, as it was buried.

Initial suspicions about the cause of illness centered on the landfill site and included pesticides, botulism and rat poison (zinc phosphidine had been used previously). Analysis of stomach contents at the Atlantic Veterinary College and Environment Canada's laboratory in St. John's revealed the presence of fensulfothion (Dasanit). Brain cholinesterase inhibition was measured in a number of samples as well, confirming the action of the pesticide. Tests were negative for botulism and rat poison.

Final counts of dead birds exceeded 800 with herring gulls representing the largest single species affected; others included greater black-backed gulls (*L. marinus*), ring-billed gulls (*L. delawarensis*), common ravens (*Corvus corox*), starlings (*Sturnus vulgaris*), and crows (*Corvus branchyrhynchos*).

Although it is assumed that the cause of the die-off was the exploded cannister, it was never recovered due to human health risks and the benefit of leaving the product where it was. Dasanit was used commonly in past years to control root maggot in root crops in this province but has not been sold commercially for 10-15 years.

The cooperative efforts of Environment Canada (Canadian Wildlife Services & Environmental Protection Services), the Canadian Cooperative Wildlife Health Centre, Newfoundland Department of Environment and Labour, the City of St. John's, the Animal Health Division (Newfoundland Department of Forest Resources & Agrifoods) and other associated agencies is acknowledged.

A complete write up on this die-off will be available in the future. (Dr. Hugh Whitney, Provincial Veterinarian, Animal Health Division, Newfoundland Department of Forest Resources and Agrifoods)

### **Successful euthanasia of a juvenile fin whale**

On the morning of December 17, 1999, a 10.5 m-long male fin whale (*Balaenoptera physalus*), identified as a young animal on the basis of its size, was found stranded on the shore of the Cardigan River, eastern Prince Edward Island, approximately 4 km from its opening into the Northumberland Strait. The animal was immobile, lying slightly on its left side in barely 50 cm of water. It was breathing at intervals of 40 seconds, and the palpebral reflex of its right eye was interpreted as normal. The marked concavity of its epaxial muscles and the relative prominence of some of its ribs indicated a severe state of emaciation. The process of stranding in a whale quickly results in severe pathophysiological changes which greatly compromise its long-term survival. Despite this, large whales may take as long as 4-5 days to die once stranded. Moreover, attempting to move a large whale weighing many tons in order to return it to open water is usually impossible without causing significant injuries to the animal. For these reasons, including the very poor body condition of this particular animal, euthanasia on humane grounds was considered the most appropriate course of action.

A local anesthetic was injected into a small region of the skin and intercostal muscle immediately caudal to the origin of the whale's right flipper. A 4 x 1000 mm needle, previously made by a local machine shop, was then inserted transversely across the thorax for a distance of approximately 70 cm, until a steady stream of blood suddenly began to flow from the needle. The following drugs were immediately injected: 5000 mg of xylazine (a sedative), 100 ml of a commercial euthanasia solution (T-61), and 1200 milliequivalents of potassium (which, at high doses, causes cardiac arrest) as potassium chloride solution. The whale showed no immediate reaction to this injection.

Approximately one hour elapsed before all vital signs disappeared. During that interval, the animal opened and closed its mouth and extended its tail several times, took a few deep inspirations followed by unusually slow expirations, and had a brief episode of fasciculations of its epaxial muscles. However, no convulsion was ever observed. A necropsy performed the following day revealed no significant disease process other than emaciation.

In the northern population of fin whales, females give birth (every 2-3 years) in low latitude waters, some time between December and April, shortly before migrating to northern latitudes for the summer.

The calves are about 6.5 m long when born, and are weaned at about 7 months of age when they are 11-12 m long. Physical maturity (average length of 19-20 m) is not reached until 20-30 years of age. The length of this young whale suggests that it had barely reached weaning age. Therefore, the most likely explanation for its severe emaciation is that it had been separated from its mother, probably several weeks earlier, had been unable to fend for itself, and had gradually starved. (Contributors: Pierre-Yves Daoust, CCWHC - Atlantic region; Art Ortenburger, Department of Health Management, Atlantic Veterinary College). The above manuscript has been submitted for consideration for publication to The Canadian Veterinary Journal, copyright Canadian Veterinary Medical Association 2000.

### **Psittacosis in Wild Rock Doves**

On June 29, 2000, a dead wild rock dove (*Columba livia*), was found at Moncton, New Brunswick, in an area frequented by the public. Necropsy at the New Brunswick Provincial Veterinary Laboratory revealed severe inflammation of the heart surface, air sacs, lungs, abdominal cavity and pancreas. Bacterial cultures revealed only a very light growth of *E. coli* from the air sacs. No bacteria were recovered from lungs, liver or pericardial sac.

A second wild Rock Dove found dead near the same site on July 20, had similar lesions as well as multiple areas of hepatitis. *E. coli* and alpha hemolytic *Streptococcus* were recovered in moderate growth from a peritoneal swab but there was no bacterial growth from the liver.

In view of the rather unremarkable bacteriologic culture results, samples were sent to the Diagnostic Virology Laboratory at the Atlantic Veterinary College for *Chlamydia* testing.

Samples of lung, air sac, liver and spleen all tested strongly positive for *Chlamydia psittaci* using the fluorescent antibody and RT-PCR techniques. Tissue samples have been sent to a referral laboratory to attempt *Chlamydia* isolation.

These two Rock Doves apparently represent the first known cases of psittacosis in wild birds in New Brunswick. Public health officials were promptly notified and the area is being carefully monitored for additional bird mortality. (James P. Goltz and J. Gale Hines, Provincial Veterinary Laboratory, Fredericton, New Brunswick).

**Note:** The necropsy of these birds was done as part of West Nile Virus surveillance in Atlantic Canada, funded by the Canadian Cooperative Wildlife Health Centre and Health Canada. Enhanced surveillance of dead wild birds for West Nile Virus is providing the opportunity to find out more about all causes of mortality in wild birds in the geographic areas being surveyed.

Editor's Note: The organism *Chlamydia psittaci* occurs in many avian species, usually as a subclinical infection; clinical disease in birds is much less common. Humans may become infected by inhalation of organisms from birds, particularly from dried feces or secretions. In humans, psittacosis, also known as ornithosis or chlamydiosis, may result in fevers, chills, headache, and signs of respiratory or generalized infection.

## Quebec Region

### Walleye myopathy

A walleye (*Stizostedion vitreum*) was captured in Lac des Dix Milles, in the Parent region of Mauricie-Bois-Francs (46.45 N - 74.383 W) during the month of June 2000. The peculiar appearance of the fish's skeletal musculature incited the fisherman to submit it for pathological evaluation. It was sent to the Faculté de médecine vétérinaire of the Université de Montréal (Saint-Hyacinthe, Québec) by a provincial wildlife conservation agent. Only fillets cut out from this fish were submitted for evaluation.

Both fillets had similar morphological changes. One fillet measured approximately 29.5 cm in length and weighed 253.0 g. The internal aspect of the fillet appeared to be more affected. More than 50% of the muscle mass had a cooked appearance, a brownish color and was easily broken apart. The brownish foci extended to half the thickness of the muscle mass, occasionally involving the full thickness of the fillet. Microscopically, sections of skeletal muscle had areas of muscle fiber necrosis. The necrotic muscle fibers were brightly acidophilic, had a coagulated appearance with loss of internal striations and were irregularly fragmented. Numerous fragments of necrotic muscle were mineralized. The edge of necrotic myofibers was occasionally infiltrated by small aggregates of inflammatory cells. The connective tissue encircling the necrotic myofibers was often quite prominent and thickened (suggestive of fibroplasia).

The microscopic findings are compatible with a condition known as "walleye myopathy". This muscle disease, which is of unknown cause, has been observed only in the walleye and is characterized by necrosis of the white muscles of the fish. In domestic animal species, myopathies can have varied etiologies including nutritional, toxic and exertional causes amongst others. The affected fish do not appear to display clinical signs. These muscular lesions will most likely be noticed by the fisherman eviscerating and preparing his prized catch (Uhland, F., Carl *et al.*, Maladies des poissons d'eau douce du Québec: guide de diagnostic, Les Presses de l'Université de Montréal, 2000, 466 pages). Prevalence of this disease in walleye within Québec is unknown. No cases were detected during gross examination of 357 walleye caught in the St-Lawrence at the Saint-Nicolas provincial fishing station (Mikaelian, I. And D. Martineau. Inventaires des conditions pathologiques chez les poissons du Saint-Laurent au site de Saint-Nicolas en 1995. Environnement Canada - Région du Québec, Conservation de l'environnement, Centre St-Laurent, Rapport scientifique et technique ST-141, 1997a, 55 pages). J (André Dallaire and Daniel Martineau, CCWHC - Quebec region.

### **The St-Lawrence beluga whale: summary of lesions detected in stranded individuals submitted for necropsy during 1999.**

Nine beluga whales (*Delphinapterus leucas*) were examined at the Faculté de médecine vétérinaire of the Université de Montréal (Saint-Hyacinthe, Québec) during 1999. A total of 17 individuals were found stranded along the shores of the St-Lawrence during that same period. This is similar to the average number of beluga whales that have been examined and found dead in the St-Lawrence each year since 1983 ( 7.5 and 15.5 respectively). Six of the submitted individuals were adequately preserved as to allow for an accurate diagnosis, suggesting that stranded whales are signaled rapidly to the authorities.

An 11-year-old female was diagnosed with a wide-spread glandular cancer (neuroendocrine carcinoma). Neoplastic nodules measuring up to 30 cm in diameter formed large masses within the lumbar portion of the spine, with extensive invasion of bone. The tumors were also invading the adjacent skeletal muscle.

A 15-year-old male most likely died following trauma. This whale had multiple fractures of the skull with hemorrhage, and fractured ribs on he right portion of the thorax. The force of impact that could have caused these lesions, along with the linear distribution of the rib fracture sites, dorsally on one side, suggest a collision with either a high speed craft of small size or with a larger boat.

Lesions resulting from bacterial infection were considered significant in three beluga whales. A 17-year-old male had severe and diffuse inflammation of the bladder of probable bacterial origin (the causative organism was unfortunately not isolated from samples submitted for bacteriology). A 16-year-old female had a moderate to severe, diffuse and suppurative inflammation of the milk duct in the mammary gland while the death of another 18-year-old female was linked to wide-spread infection with *Streptococcus phocae*.

Verminous (parasitic) pneumonia attributed to *Halocercus* spp. contributed to the death of a 10-year-old female beluga whale. A 14-year-old male had inflammation of the aorta (aortitis) involving the entire thickness of the *tunica media* of the aorta. Collapse of the lung was observed in a young newborn calf. This finding, along with the detection of occasional keratinized squamous cells within alveoli and bronchioles, suggests this calf could have died of foetal hypoxia during a problematic birth. A 17-year-old male was diagnosed with cancer of the thyroid gland (final histological classification pending). (André Dallaire and Daniel Martineau, CCWHC - Quebec Region).

## **Ontario/Nunavut Region**

The extremely high submissions of bird specimens for West Nile Virus examination was the priority for the Ontario Region throughout the summer and precluded preparation of a regional report. Ontario Region examined 1450 of the total of 2093 birds examined in Canada for the West Nile surveillance program, and most of these were examined from late July to the end of August.

## **Western/Northern Region**

### **An Epizootic of Iridovirus in Oregon Spotted Frog Tadpoles (*Rana pretiosa*)**

Due to precipitous declines in wild Oregon spotted frog (*Rana pretiosa*) populations, a collaborative effort between the Greater Vancouver Zoo, local academic institutions, and Provincial Government Ministries was initiated earlier this year to attempt captive propagation and possibly reintroduction of these animals into historic habitats within the Fraser Valley, British Columbia.

Egg masses were collected from a local breeding pond, transported to zoo holding facilities and installed in a series of 28 to 40 gallon glass aquaria; pond water was used as an initial source of static water and feed. Within 2-4 weeks of arrival, progressively increasing numbers of mortalities were incurred with approximately 100 to 150 larvae lost per day at the peak of the epizootic. In the 1500 eggs collected, mortality was approximately 90 percent.

Fresh and formalin fixed tadpoles were presented to the Animal Health Center for diagnostic evaluation. Throughout the course of the investigation, the tadpoles were generally in good body condition and aside from occasional abdominal distension due to ascites or secondary cutaneous fungal infection, there were no apparent gross lesions. Aerobic culture sporadically yielded *Aeromonas hydrophila*.

Histologically, liver cells with internal structures typical of virus infection (inclusion bodies) were seen consistently. Similar inclusions noted within the gill, respiratory epithelia, oral mucosa and skin and were occasionally admixed with small amounts of dispersed karyorrhectic and pyknotic nuclear debris.

At the time of initial submission and throughout the course of the disease, tissues from whole tadpoles were homogenized and inoculated onto four fish cell culture lines (CHSE, EPC, FHM and RTG) and incubated at 15C. Viral recovery was most efficient with EPC, then CHSE, FHM and no viruses were isolated by RTG. Up to 5 cell line subcultures were undertaken. Negative staining electron microscopy of fresh viscera and culture supernatant disclosed large numbers of iridovirus-like particles.

As a result of the histopathology, ancillary studies, and recent investigations demonstrating transmission of certain viral pathogens between fish and amphibia, a small scale study was begun in an attempt to detect the virus in insect and fish larvae from the pond where the eggs had been collected. To date, no viruses have been recovered from other pond specimens by virus culture. Investigations to further characterise the virus and its epizootiology are pending. (Stephen Raverty, AHC, BCMAFF and Trent Bollinger, CCWHC)

### **Epidemic Avian Cholera in Double-Crested Cormorants in Saskatchewan**

In late July, a biologist traveling on Kazan Lake (55°33'N, 108°22'W), in the boreal forest of Saskatchewan, reported observing as many as 6,000 dead cormorants on a large island colony. Staff from Saskatchewan Environment and Resource Management and the CCWHC visited the colony on 1 August, confirmed large-scale mortality, and secured specimens for diagnosis. Typical lesions and strong growth of the bacterium *Pasteurella multocida* lead to a diagnosis of Avian cholera.

On 2 August, a colony of cormorants on Doré Lake (54°42'N, 107°32'W), 100 km SE of Kazan Lake, was visited but no evidence of epidemic disease was seen. When revisited on 21 August, however, freshly-dead cormorants were numerous on the Doré Lake colony site. In addition, there were very few birds left on the colony site - perhaps 300 when 2000 or more fledged young of the year would be expected. Diagnostic examination confirmed avian cholera as the cause of death on the Doré Lake colony.

Total mortality could not be estimated at either the Kazan Lake or Doré Lake colonies. It was extensive at both and involved primarily young of the year. A small number of adults also were affected.

This is the second epidemic of avian cholera on the Doré Lake colony since monitoring of this colony began in 1994. The Kazan Lake colony is rarely visited and its disease history is not known. (Ted Leighton, CCWHC W/N region).

### **Winter Ticks in Stone's Sheep**

This is the second year of a study of the effects of winter ticks (*Dermacentor albipictus*) on a small population of Stone's sheep wintering at low elevation in B.C. Field work this spring revealed that all animals marked last year survived. A number of these animals had very severe loss of hair in the spring of 1999, reminiscent of hair loss seen in moose. A similar hairloss pattern was present in the sheep this year, however there were fewer

ticks present on the sheep. This spring was much warmer than 1999, with an early snowmelt. Sampling of these sheep is allowing us to develop a database on the background health of this thornhorn subspecies. We will be initiating a survey of parasites, particularly lungworm, in Stone's sheep in northeastern BC this summer and fall. It will parallel a study on Dall's sheep in the NT and the Yukon. (Helen M. Schwantje, Wildlife Branch, MELP, Victoria, BC).

### **California Bighorn Sheep in British Columbia**

In September 1999 a number of white-tailed deer carcasses were found in the south Okanagan in southcentral BC. In addition, several dead California bighorns were present in the same area. Necropsies of fresh carcasses revealed hemorrhagic lesions suggestive of Epizootic Hemorrhagic Disease (EHD). Local sentinel cattle herds had evidence of exposure to EHD viruses, however these viruses were not isolated from any of the wildlife specimens.

Subsequently, upwards of 75% of the California bighorn sheep in the south Okanagan population died during winter and spring from a pneumonia die-off. The bacterium *Pasteurella multocida* was consistently cultured from necropsied animals. Lungworm was present in varying degrees, with marked damage in some animals' lungs. There was confirmation of exposure to parainfluenza 3 and respiratory syncytial viruses in some animals. Consistently low levels of selenium are found in this population. The herd winters in the Okanagan Valley which is highly developed for human use, including residences, orchards and vineyards. The range is considered to be in poor condition with noxious weeds and forest encroachment. Domestic sheep are present and contact could have occurred.

The south Okanagan bighorns are nationally recognized for wildlife viewing and trophy hunting. As could be expected, concern from all for the sheep is very high. There is a strong commitment within government, sportsman and naturalist organizations, as well as the public, to restore this herd. Previous work and new collaborative efforts are underway to identify the factors believed to have contributed to this die-off and to act to correct as many of these as possible as soon as possible. A workshop is planned and we hope to invite a number of wildlife professionals currently working with sheep diseases and management in Canada and the US to enlist their aid. Our thanks to those of you who have already offered advice. (Helen M. Schwantje, Wildlife Branch, MELP, Victoria, BC).

Copyright © 1999/2001  
CCWHC

Online @ <http://wildlife1.usask.ca/newsletters/newsletter7-1.htm>