

University of Nebraska - Lincoln

DigitalCommons@University of Nebraska - Lincoln

---

Faculty Publications from the Harold W. Manter  
Laboratory of Parasitology

Parasitology, Harold W. Manter Laboratory of

---

11-1956

## Studies on the Helminth Fauna of Alaska. XXV. The Ecology and Public Health Significance of *Echinococcus sibiricensis* Rausch & Schiller, 1954, on St. Lawrence Island

Robert L. Rausch

Arctic Health Research Center, rausch@u.washington.edu

Everett L. Schiller

Arctic Health Research Center

Follow this and additional works at: <https://digitalcommons.unl.edu/parasitologyfacpubs>



Part of the [Parasitology Commons](#)

---

Rausch, Robert L. and Schiller, Everett L., "Studies on the Helminth Fauna of Alaska. XXV. The Ecology and Public Health Significance of *Echinococcus sibiricensis* Rausch & Schiller, 1954, on St. Lawrence Island" (1956). *Faculty Publications from the Harold W. Manter Laboratory of Parasitology*. 531.  
<https://digitalcommons.unl.edu/parasitologyfacpubs/531>

This Article is brought to you for free and open access by the Parasitology, Harold W. Manter Laboratory of at DigitalCommons@University of Nebraska - Lincoln. It has been accepted for inclusion in Faculty Publications from the Harold W. Manter Laboratory of Parasitology by an authorized administrator of DigitalCommons@University of Nebraska - Lincoln.

## STUDIES ON THE HELMINTH FAUNA OF ALASKA

### XXV. THE ECOLOGY AND PUBLIC HEALTH SIGNIFICANCE OF *ECHINOCOCCUS SIBIRICENSIS* RAUSCH & SCHILLER, 1954, ON ST LAWRENCE ISLAND

BY ROBERT RAUSCH AND EVERETT L. SCHILLER

*Zoonotic Disease Section, Arctic Health Research Center, Public Health Service,  
U.S. Department of Health, Education, and Welfare, Anchorage, Alaska*

(With Plates VII and VIII and 3 Figures in the Text)

The occurrence of a species of *Echinococcus* (Rudolphi, 1801) on St Lawrence Island was noted by the writers in early 1950. Recognition of its unusual host relationships led to an investigation of the ecology of this cestode, *E. sibiricensis* Rausch & Schiller, 1954. It is the purpose of this paper to report the results of this work, with emphasis on alveolar hydatid disease in man, of which this cestode is the etiologic agent.

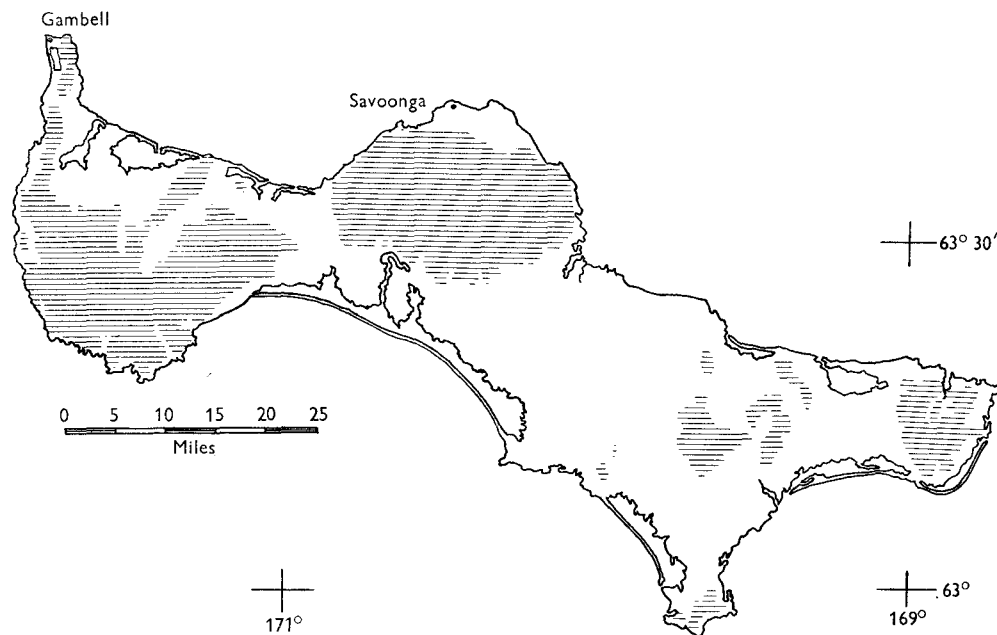
#### ST LAWRENCE ISLAND—GEOGRAPHY

St Lawrence Island is situated in the Bering Sea between Alaska and Siberia—about 100 miles from the nearest point in Alaska, and 38 miles off the Chukotski Peninsula, north-east Siberia (Text-fig. 1). Of volcanic origin, the island is some 90 miles long, and 20–25 miles wide. About half the land surface is covered by mountains, which range in altitude up to about 2000 ft. The climate is cold and damp, and high winds are frequent. The warmest months are July and August, but even then there are days with temperatures near freezing. In the summer the lowlands are wet, with numerous ponds typical of the arctic tundra. At higher elevations the vegetation is characteristic of the dry alpine tundra. The temperature in the winter reaches a minimum of about  $-30^{\circ}$  F. For more than half the year the island is surrounded by pack ice.

The mammals of the island are mainly holarctic species characteristic of high boreal regions: viz. a shrew, *Sorex tundrensis jacksoni* Hall & Gilmore; arctic fox, *Alopex lagopus* Linnaeus; ground squirrel, *Citellus undulatus lyratus* Hall & Gilmore; varying lemming, *Dicrostonyx torquatus exsul* Allen; red-backed vole, *Clethrionomys rutilus albiventer* Hall & Gilmore; tundra vole, *Microtus oeconomus innuitus* Merriam. Other land mammals occur there rarely, coming via the pack ice from Asia. Reindeer were introduced in the latter part of the century, but are now very few. Numerous dogs are kept by the Eskimo.

St Lawrence Island is inhabited by about 550 Siberian Eskimo (*Yuit*), who live in two villages—Gambell (*Sevuokuk*), slightly the larger, situated at the north-west extremity of the island, and Savoonga (correctly *Sevungak*), located about half-way down the north coast. Of the two, Savoonga has less contact with Europeans. Both villages are characterized by an assortment of wooden houses of

frame construction. About 60 % of the food consumed by the Eskimo consists of flesh of sea mammals, among which the walrus is the most important. Birds and their eggs are eaten during the summer months. The people travel extensively over the island in winter for fox trapping and for hunting. Winter travel is possible only through use of sledge dogs, of which there were about 1200 in the winter of 1954-5. Outlying fishing camps, occupied during the summer months, are reached by boat. Water for household use is obtained from nearby lakes or ponds in the summer. During the remainder of the year, ice is melted. Fuel for cooking is often scarce. The dogs are usually chained near the houses, which results in a general contamination of village areas by their excreta. There is no satisfactory disposal of human wastes, since the severe climate prevents, or at best makes difficult, the application of standard methods of sanitation.



Text-fig. 1. Map of St Lawrence Island; areas of 200 ft. or more in altitude are shaded.

#### MATERIALS AND METHODS

Field observations on St Lawrence Island have been made intermittently during the period 1950 through 1954. During this time *Echinococcus sibiricensis* has also been maintained in the laboratory through the use of experimental animals.

Since *E. sibiricensis* does not occur on the North American continent, live-trapped arctic foxes from the Alaskan mainland have been used routinely as the final host of the cestode in the laboratory. For special purposes, arctic foxes from isolated islands (e.g. Aleutian Islands), where the life cycle of *Echinococcus* spp. could not be completed (absence of other species of land mammals), have been employed. Laboratory-reared dogs also served satisfactorily for this purpose.

For study of the larval development of *E. sibiricensis*, infective eggs were taken directly from the gravid segments of living cestodes. The latter were obtained by opening the small intestine of the final host in tap water, after which the cestodes were washed free and isolated by decantation. In determining the capacity of various species of mammals to serve as the intermediate host of *E. sibiricensis*, accurate counts of the eggs administered were not made. However, all animals used in a given experiment received approximately the same number of eggs, so that information on comparative susceptibility could be obtained. The actual number of eggs given ranged from about 400 to 2000, but larger numbers were given in certain instances. The eggs were usually introduced directly into the stomach of the experimental animals by means of pipettes of appropriate size, and the operation was performed while the animals were under ether-induced anaesthesia.

Two species of microtine rodents have been used routinely as the intermediate hosts for *E. sibiricensis* in the laboratory, as well as for controls in the attempted infection of other species of mammals. Field voles, *Microtus pennsylvanicus* Ord, were laboratory-bred, the original stock having been obtained from the eastern United States. Red-backed voles, *Clethrionomys rutilus* Pallas, do not breed readily in small cages, so these animals were live-trapped in the vicinity of Anchorage, Alaska. *Echinococcus*-infected microtine rodents have never been reported on the Alaskan mainland (Rausch, 1952).

Mammals of nearly all species considered herein have been exposed also to infection with *E. granulosus* (Batsch, 1786), the eggs of which were obtained at the autopsy of dogs to which had been fed larval cysts from the lungs of elk, *Alces alces* Linnaeus (called moose in North America). Results in all rodents thus exposed have been negative. Experimentally infected mammals were killed after passage of a desired interval of time. Following autopsy, tissues for sectioning were fixed in 10 % formalin, dehydrated in ethanol, and embedded by the paraffin method. Sections were routinely stained with haematoxylin-eosin, but special stains were applied in some instances.

## RESULTS

Observations concerning the adult and larval stages of *E. sibiricensis* are discussed separately.

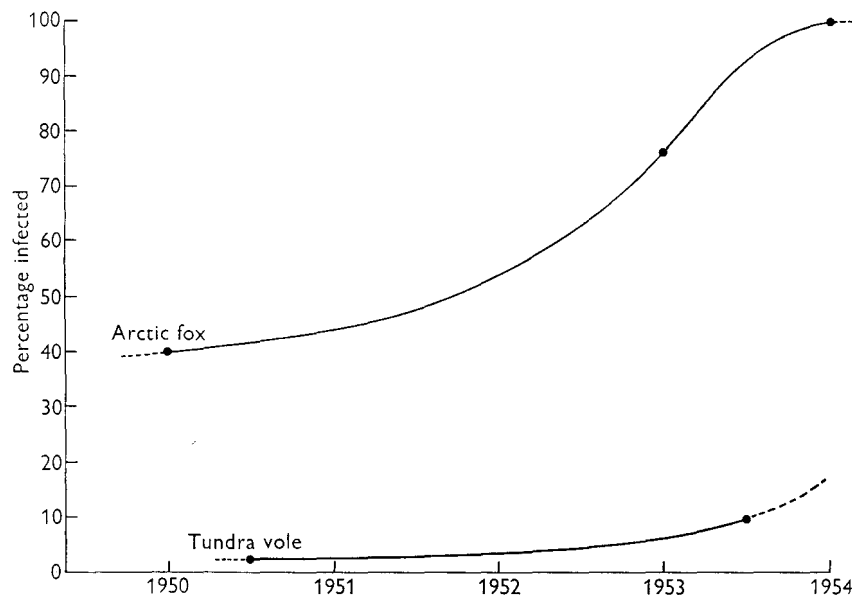
### I. *The adult cestode and the final host*

*Distribution.* St Lawrence Island represents the easternmost limit of the distribution of *E. sibiricensis*, according to present knowledge. It is probable that the cestode was brought to St Lawrence Island from Asia by foxes carried by the pack ice (Rausch, 1953a; Rausch & Schiller, 1954). If this is true, *E. sibiricensis* must have been a part of the island's fauna before its colonization by man. Since the Eskimo travelled for centuries between the island and the continent of Asia, the cestode might have been introduced by means of infected dogs in relatively recent times.

A species of *Echinococcus* ecologically identical with *E. sibiricensis* occurs on Bering Island (Barabash-Nikiforov, 1938; Afanas'ev, 1941). The pack ice does not

reach Bering Island, but an indigenous race of the arctic fox is found there. The cestode was probably introduced when red-backed voles, *C. rutilus*, were intentionally brought to the island in the latter part of the last century (Stejneger, 1884; Barabash-Nikiforov, 1943; Johansen, 1950). The voles apparently originated in Kamchatka, and their presence made possible the completion of the life cycle of this cestode.

The classical alveolar hydatid disease of man, with which that seen on St Lawrence Island is clinically identical, is frequently diagnosed in central and north-eastern Siberia. According to Semenov (1954), the disease in man has been observed as far east as the lower Kolyma River region. Excepting St Lawrence



Text-fig. 2. Incidence of *Echinococcus sibiricensis* in the final and intermediate hosts over a 5-year period. Data are based on 106 foxes in 1950, 257 in 1953, and 40 in 1954.

and Bering Islands, the cestode has a wide distribution from south-central Europe eastward across European Russia and Siberia. It may well be restricted in its distribution in the palearctic region by the occurrence of certain species of microtine rodents.

*Host-relationships.* The arctic fox is the natural final host of *E. sibiricensis* on St Lawrence Island. The incidence of infection in this animal ranged from 40% in the winter of 1950–1, to 100% in the winter of 1954–5 (see Text-fig. 2). These values were based on the presence of fully developed strobilae only; early infections, with the scolices and beginning segments deeply embedded in the mucosa, were not detected by routine post-mortem examinations. The samples of foxes examined were taken at random from many animals trapped in early winter by the Eskimo. We have no data for the summer months, since large series of animals were not obtainable at that season.

*Studies on the helminth fauna of Alaska*

399

The individual infected fox usually harbours large numbers of the cestodes. At autopsy, infections were visually evaluated as light, moderate, heavy, or very heavy. Most animals, during the time of this work, were moderately to heavily infected. Actual counts were made on representative animals, using the Sedgewick-Rafter counting chamber, and computing the total according to the average number of cestodes per cubic millimetre of sample. Infections designated as light ranged up to 25,000 cestodes; 30,000 to 50,000 was moderate; 60,000 to 80,000 was heavy. One fox, the most heavily infected animal observed, harboured in excess of 450,000 cestodes.

The cestodes attain maturity rather soon after the larvae are ingested by a canine animal. In three experimentally infected arctic foxes, we observed eggs in the faeces at 32, 33 and 33 days. The average number of eggs per gravid segment is about 200. After the production of many eggs, the adult cestodes gradually become sterile and eventually die (Rausch, 1953*b*); thus the infection of the final host is self-limiting. The production of eggs may cease as early as 3–3½ months after the date of infection, although a few cestodes may be found, in the arctic fox, as long as 7 months after infection. The greatest length of strobila, with more numerous segments, is attained by these senile cestodes. We have not determined whether duration of infection is dependent to any extent upon the diet of the host, or upon other factors less easily defined.

The adult cestodes are distributed throughout the small intestine of the final host, from a few centimetres below the stomach nearly to the caecum. The density increases posteriorly as far as the mid-ileum, where it begins to decrease. We have no observations which indicate that the final host is adversely affected by heavy infections. It seems possible that a mild enteritis might immediately follow the establishment of great numbers of immature cestodes in the mucosa, but this has not been confirmed. On St Lawrence Island, *E. sibiricensis* occurs commonly with *Taenia crassiceps* Rudolphi, 1810, *Toxascaris leonina* (von Linstow, 1902), *Uncinaria stenocephala* (Railliet, 1884), and sometimes with *Diphyllbothrium* sp.

While it has not been possible to obtain an accurate index of the status of the fox population on St Lawrence Island, estimates are based on field observations, trapping success of the Eskimo, and information provided by experienced Eskimo thoroughly familiar with the island. It has been clearly established that the density of foxes has been relatively high since 1949. During the time interval under consideration, foxes have been most abundant in the years 1953 and 1954.

Over the past six years, mouse-like rodents have comprised the major food of the arctic fox. Only the tundra vole has been important, however, since population densities of the other two species occurring here have been very low. The increase in the incidence of the adult *E. sibiricensis* in the arctic fox was directly related to the increase in the density of the vole population during the time of our observations.

The dog is also a suitable final host of *E. sibiricensis*. We have noted only a relatively low incidence of infection in dogs on St Lawrence Island, but they are, as a rule, restrained and have little opportunity to capture and eat voles. During the winter months, dogs are hampered by the snow in their efforts to capture small

rodents. In a series of thirty-one dogs autopsied in March and April 1951, 12% were found to be infected. A smaller series examined in the spring of 1950 gave negative results. Because of their value as draft animals, dogs were not often available for autopsy. We were unable to secure any of these animals in the summer months when the highest percentage of infection is to be expected. Information on this point would have been especially desirable during the summers of 1953 and 1954, when the tundra voles were abundant in the villages and relatively available to the dogs, whether the latter were chained or not. The size of the adult cestode does not differ in foxes and dogs.

It has not yet been determined experimentally whether the red fox is a suitable host for *E. sibiricensis*. The red fox is found sporadically on St Lawrence Island, but was not observed there during the course of our work. We attempted, unsuccessfully, the infection of six red foxes from the Alaskan mainland. However, all but one of these were old animals which had been in captivity for some time, so the results are not considered reliable. In one instance, an arctic fox and a red fox were fed material from the same vole; the arctic fox became infected, while the red fox did not. However, on the basis of circumstantial evidence alone, it appears that the red fox must be important in the epidemiology of alveolar hydatid disease in Eurasia. This problem is being investigated at the present time by Dr Hans Vogel, of the Tropeninstitut, Hamburg. Both the red fox, *Vulpes vulpes* Linnaeus, and the grey fox, *Urocyon cinereoargenteus* (Schreber), would come under consideration if *E. sibiricensis* became established in Canada and/or the United States.

## II. *The larval cestode and the intermediate hosts*

The larval stage of *E. sibiricensis* was first collected in 1950, in the course of a routine survey of the helminths parasitic in rodents on St Lawrence Island. Although its occurrence in an unusual intermediate host (the tundra vole) was recognized, it was thought to be the larval stage of *E. granulosus* (Batsch, 1786), and was so reported (Rausch & Schiller, 1951). The possibility of the existence of a distinct species on St Lawrence Island was suggested soon thereafter (Rausch, 1951).

The tundra vole, *Microtus oeconomus*, was the only species of rodent which had any importance, during the time of our work, as a natural intermediate host of *E. sibiricensis*. Beginning at least as early as the summer of 1949, the tundra vole population increased rapidly. The greatest density was attained in the summer of 1954, when the total population exceeded any previously observed by Eskimo now living. One of us (R.R.) travelled by dog-team over the full length of the island in November 1954. Observations made at this time confirmed the opinion that the voles were abundant wherever there was suitable habitat.

With the increase in the number of voles, there was a concurrent increase in the prevalence of the larval *E. sibiricensis* (see Text-fig. 2). This was correlated with the predator-prey relationship existing between the vole and the arctic fox, and was wholly dependent upon a sustained high population of both voles and foxes.

In the summer of 1950, only 2% of 385 voles examined harboured the larval

*Studies on the helminth fauna of Alaska*

401

stage of *E. sibiricensis*, but the incidence of infection had increased to 10% (320 animals examined) in the summer of 1953.\* Our data on prevalence of the parasite are based on the macroscopic examination of the animals. Sectioning of the entire liver to detect early infections, as suggested by Thomas, Babero, Gallicchio & Lacey (1954) is impracticable. Foci in the liver can be recognized macroscopically as early as 48 hr. following ingestion of the eggs in experimentally infected voles. Visual identification of the larval cestode can be made with certainty by the tenth day (Rausch, 1954). No other species of taeniid cestode, whose larval stage might be confused macroscopically with that of *E. sibiricensis*, occurs on St Lawrence Island. This, however, is not true for mainland Alaska.

Tundra voles from St Lawrence Island did not reproduce readily in captivity, so our observations on this animal as a host for *E. sibiricensis* are limited mainly to natural infections. As would be expected, rather light primary infections were frequent, but heavily infected animals were sometimes observed showing a remarkable degree of generalized infection following metastasis of larval tissue elements. In the latter, secondary foci were most often localized in the mesenteries, but they were also frequently found in the spleen, ligaments of the uterus and bladder, and in subcutaneous locations. Primary foci are known to occur only in the liver. Pulmonary involvement has not been observed, even in those animals with generalized metastases. Histologically, nothing has been observed which differs essentially from the larval development as described from *M. pennsylvanicus* (see Rausch, 1954).

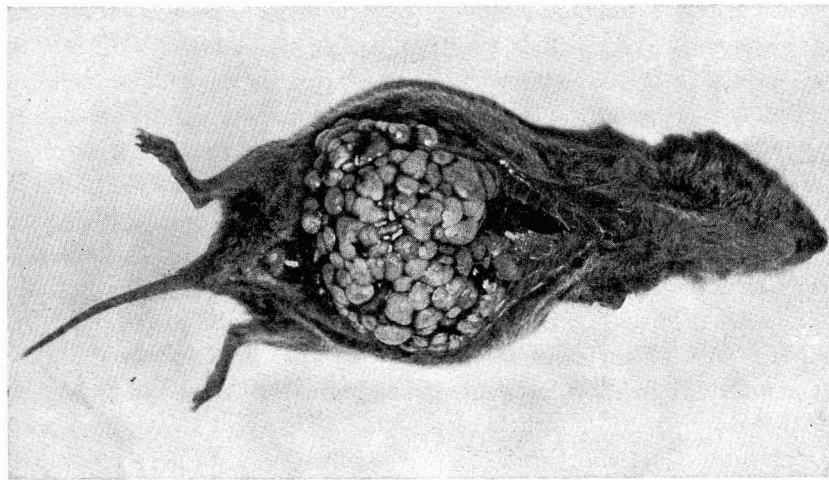
The common field vole, *M. pennsylvanicus*, is widely distributed in North America. It is susceptible to infection with the larval *E. sibiricensis*, and provides optimum conditions for development of the parasite. A typical heavy infection of 5 months' duration in this vole is shown in Text-fig. 3. Sections of 14-day, 45-day, and fully developed larvae from the same host are portrayed in Pl. VII, figs. 4-6, respectively. In addition to the laboratory-reared animals, we have also experimentally infected a number of field voles live-trapped in the vicinity of Anchorage, Alaska. Other species of *Microtus* appear equally susceptible to infection, good results having been obtained with *M. californicus* (Peale), and with a single specimen of *M. abbreviatus* Miller. These animals were live-trapped; the former near Davis, California, and the latter on St Matthew Island, Bering Sea.

*Clethrionomys rutilus*, a holarctic species of red-backed vole, is a suitable intermediate host for *E. sibiricensis* also. On St Lawrence Island, this vole occupies a habitat different from that of *Microtus oeconomus*, so that serious interspecific competition would seem unlikely. Nevertheless, red-backed voles were very uncommon during the time of our work, and we obtained only twenty-five of them. Of these, three adult animals captured in the summer of 1951 were heavily infected, while only one of twenty-two immature and subadult animals captured in the summer of 1953 was infected. A high prevalence of the larval stage of *Echinococcus* in *Clethrionomys rutilus* on Bering Island was reported by Barabash-Nikiforov (1938), Afanas'ev (1941), and Johansen (1950).

\* Of 200 tundra voles collected on St Lawrence Island during July, 1955, 31 (15.5%) were infected.



For the experimental study of the larval development in the red-backed vole, we have used only *C. rutilus dawsoni* Merriam, a form widely distributed in mainland Alaska. The course of the larval growth in this host appears to be identical with that seen in *Microtus pennsylvanicus*. The red-backed vole tolerates infection well, and the animal survives long after the growth of the larval tissue has caused marked distortion of the body. When heavily infected, the liver can within 50 days exceed the weight of the remainder of the animal's body. In this condition the animals have an almost spherical shape, and are unable to right themselves when turned on their backs. If the number of eggs given is too great, the animals die from excessive damage to the liver within 30 days. In the laboratory, and under natural conditions, many secondary foci are seen in chronically infected animals, even though the initial infection is relatively light.



Text-fig. 3. Common field vole, showing extensive larval development in the liver, five months after experimental infection with *Echinococcus sibiricensis*.

The brown lemming, *Lemmus sibiricus* Kerr, is potentially an important intermediate host for *E. sibiricensis*. This rodent has a wide distribution in the arctic regions of Asia and North America, and is an important food resource for the arctic fox. The brown lemming is easily infected experimentally, and development of the larval cestode is identical with that observed in *Microtus pennsylvanicus* and *Clethrionomys rutilus* (see Pl. VII, fig. 7). *E. sibiricensis* could become established wherever the brown lemming and arctic fox occur together.

The muskrat, *Ondatra zibethica* Linnaeus, seems to be highly susceptible to infection, although our observations concerned only two animals. These muskrats were killed 31 and 45 days following ingestion of the eggs. The appearance of the larvae in both animals was typical of those of a comparable age in *Microtus pennsylvanicus* and *Clethrionomys rutilus*. The occurrence of the larval stage of *E. granulosus* in the muskrat was reported by Spasskii, Romanova & Naidenova (1951). These animals were trapped in western Siberia, and it is probable that the

*Studies on the helminth fauna of Alaska*

403

species involved was *E. sibiricensis*. We have not attempted the experimental infection of muskrats with *E. granulosis*.

Eight mice of the genus *Peromyscus* were available for experimental infection with *E. sibiricensis*. Of these, six were subspecies of *P. maniculatus* Wagner, and there was one each of *P. boylii* Baird, and *P. truei* Shufeldt. All but one gave negative results when examined. The specimen of *P. truei*, live-trapped near Davis, California, showed a well-advanced infection when killed on the forty-fifth day. Macroscopically, the involved liver was typical in appearance, as compared with larval development in the field vole and red-backed vole. Sections showed very little leucocytic infiltration, and a minimal amount of connective tissue between the larval tissue and normal hepatic cells. The subgerminal layer was well developed, and the germinal membrane was quite cellular; scolices were numerous, and normally formed. In short, larval development was in all respects identical with that seen at 45 days in the field vole, the red-backed vole and muskrat. Additional work is needed with species of *Peromyscus*, as there may be considerable differences in degree of susceptibility in the various species of this genus.

The larval *E. sibiricensis* is capable of invading the liver of the varying lemming, *Dicrostonyx torquatus* Pallas, but it is soon overcome by the tissue reaction of the host. Animals killed on the twelfth day after ingestion of the eggs showed numerous foci which were macroscopically characteristic of an early infection. By the twentieth day, numerous foci were still present, but appeared unusually small. Sections disclosed that the lesions had a spherical shape, and there was no evidence of proliferation of larval tissue (Pl. VII, fig. 8). The subgerminal membrane was calcified, and degenerative changes had taken place in the germinal membrane as well. The zone of tissue reaction ranged from 100 to 150  $\mu$  in thickness, and was comprised of a loose stroma of connective tissue in which polymorphonuclear neutrophils were numerous. There were also scattered aggregations of lymphocytes around the periphery. Giant cells were not a prominent part of the reaction, although they have been observed frequently in other resistant species of hosts. The latest observations were made nearly 5 months (147 days) after ingestion of the eggs. At this time, calcification was evident macroscopically. Sections showed completely calcified areas surrounded by a zone of tissue reaction from 200 to 350  $\mu$  thick (Pl. VII, fig. 9). The connective tissue stroma was relatively loose, but acellular. Polymorphonuclear neutrophils were present peripherally, along with a few mononuclear cells. Focal aggregations of lymphocytes were fewer, but still present. It is concluded that the larval *E. sibiricensis* is incapable of development in the varying lemming.

Fourteen hamsters, *Mesocricetus auratus* Waterhouse, were exposed to infection, but only one had any evidence of larval invasion. The liver of this animal, examined on the tenth day, contained eight small foci which macroscopically resembled early-stage larvae. Microscopically, a lesion was demonstrated having a well-circumscribed necrotic centre containing considerable granular debris (Pl. VII, fig. 10). The area of necrosis was surrounded by a zone of polymorphonuclear neutrophils, which in turn was bounded by a thick zone of cells, mostly phagocytes. A peripheral zone, about 200  $\mu$  thick, was comprised of connective tissue, with

numerous lymphocytes and a few polymorphonuclear neutrophils. It is concluded that the hamster is not a suitable intermediate host for *E. sibiricensis*.

For the present work, the experimental infection of four species of sciurid rodents was attempted. Thomas *et al.* (1954) reported having observed well-developed larvae of *Echinococcus* in two of twelve ground squirrels, *Citellus undulatus lyratus* Hall & Gilmore, collected by them at the north-east end of the island in the summer of 1954. Of 111 squirrels from St Lawrence Island examined by us, all were free of this cestode. In order to gain some understanding of the degree of susceptibility of this squirrel, we attempted the infection of seven specimens of *C. undulatus ablusus* Osgood, trapped on the Alaskan mainland. These animals were killed on the tenth and fifteenth days. No lesions were observed macroscopically at time of autopsy, but definite evidence of larval invasion of the liver was visible in sections from only one of the five squirrels studied in detail. Many very small scattered foci of polymorphonuclear neutrophils were noted in the livers of all five animals; most of these were perivascular and involved both the interlobular and central veins. In one animal, a few rather large lesions were also present, consisting of areas of degenerating hepatic cells into which great numbers of polymorphonuclear neutrophils had migrated. A few macrophages were present, but no giant cells were observed. Larval tissue could not be identified, and the findings indicated that the larval cestodes were unable to establish themselves in this mammal. Five field voles exposed as controls had heavy infections when killed on the fifteenth day. Complement-fixation tests were performed on serum from four of the squirrels, and all gave an anticomplementary reaction.

With the above-described experiments in mind, the observations of Thomas *et al.* are difficult to explain. The squirrels examined by us were collected in the summers of 1950 and 1953, when the probability for natural infection might have been significantly less.\* However, it seems that the ground squirrel is not readily susceptible, and the histological findings suggest that the larvae die early, before they migrate far from the hepatic blood vessels through which they enter the liver. Since the condition noted by Thomas *et al.* was apparently identified only by macroscopic examination, it is possible that the interpretation was erroneous. *C. undulatus* has a wide distribution in Asia and North America and might have some importance in the epidemiology of alveolar hydatid disease if it harbours the larval cestode. We expect to investigate this problem further.

One of three red squirrels, *Tamiasciurus hudsonicus* (Erxleben), was found on the fifteenth day after ingestion of ova to have many hepatic lesions. These were larger than the larvae occurring in control voles killed at the same time, and measured as much as 3 mm. in diameter. Sections disclosed larval vesicles embedded in a wide zone of degenerating hepatic cells. The path of larval migration was infiltrated by lymphocytes, and the zone immediately around the larvae contained great numbers of mononuclear leucocytes. Erythrocytes were abundant in the vicinity of the parasites. There was no evidence of any fibrosis. Some of the larvae had produced numerous exogenous vesicles, but these did not have a

\* Thirty ground squirrels collected on the island in July, 1955, were negative.

typical appearance. In some there had been considerable proliferation of the subgerminal tissue, but the germinal layer was not well developed in any of them. Many of the lesions contained no recognizable larval tissue, and it was concluded that the parasites had been overcome. The complement-fixation test was negative for this animal. Evidence available indicates that the red squirrel probably cannot serve as the intermediate host for *E. sibiricensis*.

An adult specimen of flying squirrel, *Glaucomys sabrinus* (Shaw), received a large number of eggs via stomach tube. When examined on the fifteenth day, hepatic foci were evident macroscopically. Upon sectioning, these were found to consist of vesicles up to  $375\mu$  in diameter, surrounded by a zone containing many leucocytes. The latter was comprised of necrotic and degenerating hepatic cells with many polymorphonuclear neutrophils and large mononuclear cells. Lymphocytes had infiltrated the path of larval migration from the adjacent veins. Large foreign-body giant cells were occasionally present. In most of these foci, a thin layer of larval tissue was recognized. There was no evidence of exogenous or endogenous proliferation, however, and the larvae appeared to be poorly developed. The complement-fixation test for this animal was positive. It is doubtful, however, that the larvae would have been able to persist and develop.

An adult hoary marmot, *Marmota marmota caligata* (Eschscholtz), received many eggs, and was examined on the fifteenth day. No lesions were observed macroscopically, and on sections nothing was seen suggestive of larval invasion. The complement-fixation test for this animal, however, was positive.

We attempted the infection of two young domestic rabbits. When the first was killed after 30 days, many white foci were found in the liver. Granulomatous lesions (Pl. VII, fig. 11) resembling those seen in the hamster were located on sections. Small larval vesicles, without any germinal tissue, were closely surrounded by a thick zone in which phagocytes were numerous. This in turn was enclosed by a zone of fibrosis, in which a few lymphocytes and eosinophils were present. The serum of this animal gave a strong positive in the complement-fixation test for hydatid disease. The second rabbit, killed at  $2\frac{1}{2}$  months, had only a small number of healed lesions; its complement-fixation test was negative.

A 2-year-old horse was fed several thousand eggs of *E. sibiricensis*, and was killed 45 days later. Granulomatous lesions could be found throughout the liver, but nothing identifiable as tissue of the larval cestode was observed in sections. Centrally, a necrotic mass was located, containing cellular and non-cellular debris and areas of calcification (Pl. VIII, fig. 12). This was surrounded by a rather thick zone which contained a great many phagocytes and large giant cells. Peripherally, the mass was bounded by a zone of fibrosis containing lymphocytes and eosinophils, the latter abundant focally. Although negative prior to artificial infection, the complement-fixation test for hydatid disease was strongly positive at the time the horse was autopsied. The overall conclusions were somewhat obscured by the fact that this animal harboured numerous strongyles; however, it appears unlikely that the larval stage of *E. sibiricensis* is able to persist in the horse.

A herd of about 200 reindeer ranges over much of St Lawrence Island. Since these animals must frequently ingest eggs of *E. sibiricensis*, infection would seem

unavoidable if reindeer were susceptible. Since it is desired that they increase in number, these reindeer are no longer killed; however, permission to examine a few animals was granted by the Alaska Native Service and the Council of the village of Savoonga. Three old animals, one steer and two cows, were killed for study. Macroscopically, nothing suggestive of the presence of the larval cestodes was noted, excepting a few small foci observed in the liver of one old cow. Microscopically, these were found to be granulomatous lesions resembling those resulting when the larval cestodes invade the hepatic tissue of resistant species of mammals and are unable to persist. Although no reindeer have been available to us for experimental use, we believe that this species is not a satisfactory intermediate host for the cestode.

Two domestic goats, the only ruminants available for experimental purposes, were exposed to infection. The first of these animals was 7 days old when given several thousand eggs via stomach tube. When examined 15 days later, its liver was found to contain many necrotic-appearing foci averaging about 1 mm. in diameter. Compared macroscopically with the larval cestodes occurring in voles infected as controls, it was noted that these foci appeared more opaque, averaged smaller in size, and did not give the impression of being vesicular. Sections disclosed necrotic areas about 500  $\mu$  in diameter which contained degenerated hepatic cells and much granular debris, most of which was eosinophilic. Bounding this was a thin zone of palisaded epithelioid cells, which in turn was surrounded by a thick zone of mononuclear leucocytes, apparently lymphocytes. No trace of tissue resembling that of the larval cestode could be identified. There were well-defined paths of larval migration from the interlobular veins, densely infiltrated by mononuclear leucocytes. The processes of larval migration and host tissue reaction were much delayed when compared with those seen in voles. The complement-fixation test for hydatid disease gave a positive result.

The second goat, over a year old, was given a similar number of eggs in feed. When examined on the twenty-fifth day, no trace of larval migration was detected. Sections of the liver likewise gave negative results. The complement-fixation test was positive. It is possible that degree of susceptibility is influenced by the animal's age.

It is significant that Afanas'ev (1941) observed no *Echinococcus* infections in cattle, swine, or reindeer slaughtered on Bering Island. He believed that the cestode was absent from nearby Mednyi Island '... because its intermediate host, the vole, is also absent there'. All evidence supports the conclusion that ruminants cannot serve as the intermediate host of *E. sibiricensis*.

Two rhesus monkeys were exposed to infection, and examined after 30 days and 2½ months, respectively. In the first animal, lesions macroscopically resembling those typical of an early infection were found in the liver, although their size was smaller than expected after 30 days' growth. The central part of the lesions consisted of a rather amorphous mass of eosinophilic material with numerous phagocytic cells around the edges; no larval tissue was recognized. This mass was enclosed by a rather dense zone in which lymphocytes were abundant, along with numerous scattered eosinophils. Peripherally, the lesion was circumscribed by a dense zone

of collagenous fibres which bordered directly upon the normal hepatic cells (Pl. VIII, fig. 13). The complement-fixation test was strongly positive.

The second monkey, after 2½ months, exhibited a number of hepatic lesions of relatively large size (Pl. VIII, fig. 14). There had been much proliferation of the subgerminal layer, but there was no evidence of the germinal layer. Considerable cellular debris had been retained within the folds of the larval tissue, and this was undergoing degeneration. Directly adjacent to the larval tissue was a thin layer of rather amorphous material containing pyknotic nuclei and degenerating cells. The latter was surrounded by a thick zone of loose connective tissue, which was separated from the hepatic cells by a zone of varying thickness in which lymphocytes were abundant. The serum of this animal also gave a strongly positive complement-fixation test.\*

It appears that the larva of *E. sibiricensis* is capable of survival and proliferation in the rhesus monkey, much as it is in man. However, it is probable that scolices are never produced. Long-term observations on the course of the infection in the monkey are in progress.

Negative results have been obtained in the attempted infection of mammals of species other than those discussed above, as follows: porcupine, *Erethizon dorsatum myops* Merriam, 2; kangaroo rat, *Dipodomys* sp., 1; pocket gopher, *Thomomys bottae* (Eydoux & Gervais), 1; harvest mouse, *Reithrodontomys megalotis* (Baird), 4; albino rat, *Rattus norvegicus* (Berkenhout), 37 (both young and adult animals used; pooled sera from ten subadult animals gave negative results in the complement-fixation test); albino mouse, *Mus musculus* Linnaeus, 10; domestic swine, 5 (average weight at time of exposure was 25 lb.).

#### ALVEOLAR HYDATID DISEASE IN MAN

The occurrence of alveolar hydatid disease in the Eskimo of St Lawrence Island was not recorded in the literature, and to our knowledge had not been recognized prior to the time of the work reported herein. Medical facilities available to the Alaskan Eskimo have been inadequate. Further, because the disease is unknown in North America, few physicians have more than a text-book knowledge of it. Human infections have likewise not been diagnosed on Bering Island, according to Afanas'ev (1941), who stated: '... up to now *Echinococcus* has not been found in man on the Komandorskii Islands, however this proves nothing because of the difficulty of its diagnosis and insufficiency of medical service on the islands.'

Most of our information on alveolar hydatid disease in the Eskimo has been obtained by indirect means through the use of the Casoni and complement-fixation tests. The application of the latter was made possible through the co-operation of Dr T. B. Magath, who has had much experience with the serologic diagnosis of cystic hydatid disease. Sera collected on St Lawrence Island were sent by air to Minnesota, and the tests were performed in Dr Magath's laboratory.

The Casoni test, using non-specific antigen (dried strobilae of *Dipylidium caninum* (Linnaeus)) of commercial origin, was first applied by us in 1950, when a

\* Thomas *et al.* (1954) reported the larval cestode in one of three shrews collected. Rausch examined 13 shrews on the island during July, 1955, and found three infected.

total of 232 persons was tested, all of whom were 12 years of age or older. Reactions regarded as positive were observed in fifty-six persons. Complement-fixation tests were later performed on selected individuals.

In December 1954 the Casoni test was carried out on a total of 286 Eskimo ranging in age from 8 to more than 70 years. Of these, 260 individuals were tested with specific antigen prepared from larval tissue from an experimentally infected red-backed vole,\* as well as with cystic fluid of human origin. Blood sera were collected from 308 persons for the complement-fixation test. Data on 233 persons who were given the Casoni test (using both human and vole antigens) and the complement-fixation test are summarized in Table 1. The Casoni tests were evaluated by Dr James G. Bridgens and Rausch, 20 min. after the intracutaneous injection of  $\frac{1}{100}$  ml. of antigen. In nearly all cases the maximum reaction developed within this time interval.

Table 1. *Summary of Casoni and complement-fixation tests performed on 233 St Lawrence Island Eskimo in 1954*

No. of individuals tested	Age group (years)	Tests performed								
		Casoni (alveolar antigen)			Casoni (cystic antigen)			Complement fixation*		
		+	?	-	+	?	-	+	?	-
24	10 and under†	2	2	20	1	1	22	0	3	21
77	11-20	16	6	55	3	2	72	9	3	65
45	21-30	16	2	27	10	2	33	3	3	39
29	31-40	14	2	13	4	1	24	6	3	20
30	41-50	17	2	11	10	2	18	10	4	16
14	51-60‡	5	1	8	3	0	11	3	0	11
14	61 and older	8	1	5	6	5	3	4	5	5
233		78	16	139	37	13	183	35	21	177

\* Fifty complement-fixation tests, not included in table, were performed on individuals on whom no skin test was made. These are tabulated as follows: 9 positive, 1 doubtful, and 40 negative.

† Youngest individual (not in table) reacting positively to the complement-fixation test is 9 years old.

‡ Not included here is one individual, aged 54, who gave positive reactions to both alveolar and cystic Casoni tests, and a strong anticomplementary reaction to the complement-fixation test.

Antigen derived from the alveolar larva produced about twice as many positive Casoni reactions as did the antigen of cyst fluid origin (*E. granulosus*). In comparing results of the Casoni and complement-fixation tests, it was found that twenty-six of the thirty-five persons for whom the complement-fixation test was positive also gave a positive Casoni reaction using the alveolar-type antigen. Only seventeen positive Casoni tests for the same thirty-five persons were obtained with the cyst fluid antigen. The Casoni test was negative with both antigens in nine of

\* This was prepared by grinding in a mortar 20 g. of larval tissue in 100 ml. of normal saline, followed by incubation for 4 hr. at 37° C. The filtrate was used without further dilution. This, as well as the cystic fluid, was preserved by the addition of 1:50,000 merthiolate.

the thirty-five persons for whom the complement fixation was positive. A positive Casoni reaction (using the alveolar antigen) was obtained for fifty-two persons for whom the complement-fixation test gave negative or doubtful results.

A positive Casoni reaction with a negative-complement fixation test may be indicative of an infection which has been overcome by the tissue reaction of the host. Magath (1953) reviewed the diagnostic tests for hydatid disease, and concluded that a positive Casoni test may persist for the life of the individual. He stated (p. 223): '... this test cannot be used as a measure as to whether the patient is suffering from a live hydatid cyst, from a suppurative cyst, from a calcified cyst, or from the results of a former infection which is now completely obliterated.' From a review of the literature, Magath concluded that results with the Casoni test range from about 60 to 90 % reliable in indicating past or existing infections. Henschen & Bircher (1945) expressed the opinion that the Casoni test appears to be more dependable than the complement-fixation test in the diagnosis of hydatid disease. It was stated that they, as well as other workers, had observed several positive reactions in the presence of alveolar hydatid disease when fluid from the larval cyst of *E. granulosus* was used as the Casoni antigen.

Regarding the complement fixation, Posselt (1925) did not consider this test well suited to the diagnosis of alveolar hydatid disease. Since alveolar larvae from man are usually sterile and necrotic, he believed that a specific antigen could not be obtained from them. Magath (1953), however, had good results in the diagnosis of cystic hydatid disease, using cyst fluid preserved with merthiolate as the complement-fixation antigen. Positive tests employing cyst fluid antigen were obtained on sera from mammals infected by us with the larval stage of *E. sibiricensis* (confirmed by post-mortem examination). Accurate results were also obtained in man, in so far as we have been able to confirm them by indirect means of diagnosis.

Differential counts were made on blood smears of 242 Eskimo for whom data on Casoni and complement-fixation tests were available. Of these forty-one (17 %) demonstrated a degree of eosinophilia exceeding 5 %. The maximum observed was 27 %. No significant correlation could be made between the occurrence of eosinophilia and other findings indicative of active infections. Both Posselt (1925, p. 596) and Henschen & Bircher (1945, p. 216) concluded that eosinophilia is inconstant and of little diagnostic value for alveolar hydatid disease. We have not observed eosinophilia of the peripheral blood in experimental animals having advanced infections.

In addition to the data on the Eskimo, we have obtained sera from 153 military personnel who spent a year or less on St Lawrence Island. Of this total number, twelve gave positive complement-fixation tests, and ten gave doubtful results. An effort is being made to check periodically those men who have shown positive or questionable reactions, in order to observe any changes in titre. At the time of this writing, second tests have been performed on six persons, as shown in Table 2. Observations on these men will be continued as long as possible, or until negative tests have been obtained. Repeated tests have been made at intervals of 3-6 months. If active alveolar hydatid disease develops in any of these men, it



will be of unusual interest, since the time of exposure is known, and the prepatent period could be determined.

When the larval stage of *E. sibiricensis* is able to persist in the human host, it may be very pathogenic. Years may pass before signs of the disease become apparent and, under conditions existing until recently on St Lawrence Island, diagnosis and treatment were unlikely. Before the time of this work, a few

Table 2. *Results of complement-fixation tests on 153 military personnel*

Positive		Doubtful		Tests repeated (6)		
No.	%	No.	%	2nd positive	2nd negative	2nd-3rd doubtful
12	7.84	10	6.53	1	3	3

Eskimo underwent surgical treatment for the removal of undiagnosed masses in the liver. More recently, two persons have been treated surgically for alveolar hydatid disease at the Tacoma Medical Center, Tacoma, Washington. Detailed information on these patients, with material for study, has been made available to us. In further support of the conclusion that the disease on St Lawrence Island is identical with that in Eurasia, the case histories are summarized here.

(1) I.A., male, age 28 years. First symptoms, reported in January 1949, included epileptiform convulsions which occurred with increasing frequency. The seizures had been preceded by disturbed gait, which became constant. Severe headaches were common and there was progressive disturbance of vision. An intracranial neoplasm was suspected. Craniotomy was performed on 9 November 1950. A mass of increased resistance was removed from deep in the right post-frontal area. This tissue contained many cysts of variable size. Microscopically, there was marked infiltration by lymphocytes and plasmacytes, with perivascular fibrosis, gliosis and necrosis of tissue adjacent to the cysts. The postoperative course was difficult. The operation was followed by moderate paralysis of the left arm and leg; improvement was gradual, and there was a residual weakness of the left arm. The patient was discharged to his home, where he died in July 1951. No autopsy was performed.

(2) M.I., female, age 58 years. In 1950 an enlarging mass was discovered in the epigastrium. Exploratory laparotomy performed in Alaska on 19 March 1951 disclosed a tumour-like mass 12–15 cm. in diameter below the xiphoid process and to the right of the midline. The right lobe of the liver was involved. Treatment consisted of the withdrawal of about 250 c.c. of thick, gelatinous, muco-purulent material by means of a trocar. Streptomycin was introduced into the collapsed cyst, whose opening was closed by a purse-string suture. Recovery was uneventful.

With recurrence of the mass in the epigastrium, the patient was admitted to the Tacoma Medical Center in 1953. Laparotomy was performed on 27 May 1953, and a cyst about 15 cm. in diameter was found in the incisura between the right and left lobes of the liver, on the anterior surface. There were adhesions to the abdominal wall, and the right lobe of the liver was involved. About 500 c.c. of

thick, greenish, purulent material was evacuated, and the cyst was removed *in toto* by dissection. The thick-walled cyst was opened prior to fixation, and was 11 cm. in greatest diameter. The outer surface exhibited irregular convolutions and adherent strips of tissue. The wall of the cyst varied in thickness from 2 to 10 mm., with thicker areas corresponding to nodular elevations on the outer surface. The wall was greyish white in cross-section, with a yellowish, necrotic-appearing membrane on the luminal surface. Calcium deposits were present focally in the wall. Further sectioning of the wall revealed some areas almost cartilaginous in nature. Small cystic areas were present, with cysts, measuring 1 to 2 mm. in diameter, filled with translucent, gelatinous material. Scrapings from a small cyst exhibited laminated membranes consistent with the diagnosis of hydatid disease. No scolices were observed.

Microscopically, confluent or solitary cysts were seen at different levels of the cyst wall (Pl. VIII, figs. 15, 16). The lumina of the cysts were lined by a compact, acellular laminated layer. Adjacent to the latter, away from the lumen, the tissues were fibrosed and somewhat fragmented. This zone merged with the layer of proliferating reticuloendothelial cells in which there were occasional scattered giant cells. Lymphocytic and some neutrophilic infiltrations were noted. In the lumina of cysts, no germinal layer was observed, but there were occasional small protrusions suggestive of scolices. Remnants of liver parenchyma were attached along the outer margins of the cysts. Chronic granulomatous inflammation was extensive throughout all sections examined. Some zones were poorly cellular and had the appearance of being completely hyalinized. At other levels there was reactive fibrosis, and numerous foam cells intermingled with masses of erythrocytes, lymphocytes, eosinophils, and plasma cells. Occasional groups of fat cells were also found within the inflammatory tissue.

Recovery was uneventful. When the patient was examined by Dr Bridgens on 15 December 1954 the liver was not palpable, and the spleen could be felt only upon deep inspiration. All indications were that the infection had been extirpated.

The infection in the second patient was very similar to those reported by European and Russian workers. For comparison, descriptions of two cases are quoted from Semenov (1954). The first of these originated only a few hundred miles west of St Lawrence Island.

1. Case C-vaM. 35 years; 28. vii. 49. Brought by plane from Nizhne-Kolymskii region. An objective investigation turned one's attention to a very large abdomen with a cyst visible to the naked eye in the epigastric region. The cutaneous layers are icteric, with many scratched areas and pyoderms. Palpation shows rock-like solidity of the liver protruding from under the rib arch 12-15 cm. with large protrusions on the surface. The sclerae are icteric. Ascites. Edema of the legs. As concerns heart and lungs, there are no essential changes. Casoni reaction positive.

On 12. ix. the patient was operated on under local anaesthesia. An incision of moderate size was made above the navel and the abdominal cavity was opened. Ascitic fluid of a brownish red colour was exuded under great pressure. The liver was of enormous dimensions as a consequence of the parasitic cyst which had encompassed almost the whole right lobe and partly the left (there were individual nodules about the size of a fist). The liver capsule was preserved only on the periphery of the cyst and in sections of the liver. In consequence of the inoperability of the cyst, the abdominal cavity was completely closed in layers after extraction of pieces of the tissue for histologic investigation. The patient lived for three days

after the operation and on 14. ix. there was the appearance of increased ascites and cachexia and weakening of the heart; she died. At the autopsy, the clinical diagnosis was affirmed.

2. The patient K-v.V.A., 12 years old, entered the surgical section from the city of Olekminsk on 3. vii. 45. Inasmuch as an experimental laparotomy had already been performed on the patient in the regional hospital, an attempt at a radical removal of the parasitic cyst was made. On the 1. viii. 45 day, under ether, the abdominal cavity was opened with a moderate incision from the xiphoid to the navel. Investigation disclosed alveolar echinococcus of the left lobe almost to the size of two fists, clearly visible only from the side of the lower surface of the liver. Puncture of the echinococcus cyst produced a thick matter. The operational field was isolated by shrouds; from the cyst which was of extraordinarily solid consistency was cut an oval piece. There was visible a massive little wall of the thickness of 2 cm.; in the centre of the cyst was disintegration and pus. After removal of the pus and a working over of the cavity with a five per cent formalin, the wall of the parasitic cyst was cut off with separate concentrically widening areas. In such fashion almost the entire cyst was removed, with the exception of one-third of it which was found deep; the latter was removed with a sharp spoon up to the appearance of the liver capsule. As a consequence of the beginning of haemorrhage, the cavity was temporarily tamped up. After stopping of haemorrhage, the remaining unremoved thin peripheral layer of alveolar echinococcus was cut away along with the liver capsule. On the wound of the liver were placed catgut sutures. The incision of the abdominal wall was sewed up in successive layers. In the postoperative period there was noted a sharp falling of heart activity, a collapse. Despite measures taken, the patient died toward morning.

The causative agent of alveolar hydatid disease was first recognized by Virchow (1855) as being the larval stage of a cestode of the genus *Echinococcus*. Following Virchow's observations, the specific identity of the cestode involved has been a matter of considerable controversy. Some investigators have had the opinion that, under certain conditions, the larva of *E. granulosus* develops anomalously and produces the alveolar formation; others have believed that a distinct species of *Echinococcus* is involved. The controversy need not be discussed further here, since it has been reviewed recently in detail by Dew (1953). To our knowledge, alveolar hydatid disease has not been demonstrated experimentally prior to the present work.

Although the larva of *E. sibiricensis* may frequently infect man, it rarely persists long in this host according to available information. It appears that man is an accidental, and altogether unsatisfactory intermediate host for this cestode, and larvae from the human host usually possess the following characteristics which support this conclusion: (1) growth progresses slowly; (2) the bulk of the larval mass is necrotic, with only a thin peripheral layer of viable tissue (specifically in hepatic infections); (3) the germinal layer is usually absent, and scolices are rarely produced. It might be said that man and the larval cestode are mutually pathogenic. The above-mentioned points are discussed separately.

Very rapid growth of the larval cestode is characteristic in hosts which are regarded as the natural ones (Rausch, 1954), and the infective stage is attained in a relatively short time. Rapid development is necessary for successful propagation of the cestode when short-lived animals (as voles) are involved. It is agreed by clinicians familiar with alveolar hydatid disease that human patients may remain asymptomatic for years. This cannot be explained by the fact that most human infections may derive from ingestion of only a few eggs.

The larval mass is largely necrotic in classical human alveolar hydatid disease

involving the liver, and only the cestode tissue in close apposition with the tissue of the host is able to survive. We have not observed necrosis in any experimentally infected voles, irrespective of the size attained by the larval mass or of the degree of damage to the liver in which it occurs. If such larvae were largely necrotic, the number of scolices present would be greatly reduced, and this in turn would affect the reproductive success of the cestode. It is evident that the host-parasite relationship existing between the larval *E. sibiricensis* and certain mammals which it may invade is not always favourable to the cestode, as evidenced by the kind of local tissue reaction evoked. In a favourable relationship, the parasite has become so adapted to the host organism that its presence does not cause a foreign-body-type reaction. Severe tissue reactions alone are indicative of an unnatural parasite-host relationship, and more or less comparable reactions have been observed in the varying lemming, hamster, rabbit, horse, goat and monkey—most of which are able to overcome and destroy the larval cestode. Thus, calcified areas, very dense leucocytic infiltration, numerous giant cells, and marked proliferation of connective tissue are regularly observed in the mammals listed above as unnatural hosts. A pronounced tissue reaction is not characteristic of infections in voles and other highly susceptible mammals.

From a review of the literature and other sources of information, it is evident that larvae in man rarely produce scolices. Virchow (1855) observed scolices, apparently malformed, in the case studied by him. He stated (page 92):

Einzelne Thiere hatten ihre regelmässige, ausgestülpte Form und man unterschied an ihnen den rundlich eiförmigen Hinterleib mit einer, dem früheren Stiel entsprechenden trichterförmigen Einsenkung und den etwas breiteren und grösseren Kopf mit seinen vier Saugnäpfen und der scharf begränzten Mundgegend. Manche dieser Thiere hatten keine Spur eines Hakenkranzes und bei einzelnen, kleineren und blässeren möchte ich in der That glauben, dass sie noch ganz jugendlich waren und überhaupt noch keine Haken besessen hatten. Andere dagegen waren sehr gross und durch reichliche Anhäufung von gelbbraunen und braunrothen Pigmentkörnchen am Mund, den Saugnäpfen und dem Hinterleibe ausgezeichnet, so dass hier wohl ein secundärer Verlust der Haken stattgefunden haben könnte.

Dardel (1927) and Henschen & Bircher (1945) did not succeed in rearing adult cestodes when dogs were fed larval material of human origin. Posselt (1904), however, fed alveolar larval material from man to a recently weaned dog, whose faeces had been examined for cestode eggs, and to whom an anthelmintic had been administered. He later autopsied the dog, and reported successful infection (p. 90): 'Bei demselben wurde zum erstenmale in vollkommen einwandsfreier Weise die *Taenia echinococcus alveolaris* (multilocularis) in zahlreichen Exemplaren gezüchtet.' To our knowledge, the results obtained by Posselt have never been duplicated.

#### THE EPIDEMIOLOGY OF ALVEOLAR HYDATID DISEASE

Human infection is most likely to occur at times when voles and foxes are abundant. Under conditions existing during the period 1950–4, it is difficult to believe that any of the Eskimo could avoid ingesting eggs of *E. sibiricensis*. Both dogs and foxes are important disseminators of the eggs, but their importance changes in relation to a variety of influencing factors.

The Eskimo have direct contact with the arctic foxes during the winter, beginning about 1 December with the opening of the trapping season. After capture, the foxes are brought to the villages or to trapping camps, and all subsequent procedures are carried out in the living quarters. The animals are hung in a warm place to thaw, and are then skinned, usually by the women. During handling, eggs adhering to the fur may be shaken off and scattered about. The foxes are skinned in the Eskimo manner, by cutting around the mouth and withdrawing the body without cutting the skin. In freeing the skin from the bone of the tail, the skinner usually grasps the base of the tail in the teeth, having one hand inside the skin and the other outside. The hides are stretched and dried inside the house, where they are hung near the ceiling for greater warmth. After drying, the skins are worked until soft, and are then cleaned by beating them in fine sand or flour. The skins are sold to the village co-operative store, and are eventually sent to the continental United States for tanning and processing.

Sledge dogs may comprise an important source of human infection. When not being worked, during the summer months, the dogs are poorly fed and will eat voles and other small animals whenever possible. Although dogs are not nearly as adept at capturing voles as are the foxes, they are able to eat them frequently if unrestrained. Dogs which are chained do not often capture any voles since the latter keep to areas grown to vegetation. However, in periods of high population density, such as the summers of 1953 and 1954, the voles move about the villages and commonly are seen running on vegetation-free ground. Under such conditions, they are easily caught by the dogs.

Through custom and because of greater convenience, the dogs are chained near the dwellings. Young dogs, those unfit for work, and occasional strays may be at liberty. In 1954, there was one team of about ten dogs for every two families on the island. The villages are badly contaminated in general, with a concentration of canine and human excrement around the dwellings. There is always a risk of carrying faeces into the houses on footwear and on any implements to which dogs have had access. Harnesses and equipment used in connexion with the dogs are badly soiled, but nevertheless are repaired indoors. In unfavourable weather, dogs about to whelp or dogs in poor condition may be taken into the shelter of the storm-porch where much of the food of the household is stored. During the snow-free time of the year, eggs of *Echinococcus* can be picked up by the dogs' fur and transferred to the hands of persons working with them.

During the working season, the dogs are well fed if food is available. At this time, few voles can be captured by them because of the shelter afforded by the snow cover. In handling the dogs on the trail, gloves are never changed nor are the hands washed afterwards, or before eating, as it is so cold that such sanitary precautions are nearly impossible to observe. Water is obtained only by melting ice or snow, and fuel is not readily located.

It is evident that any dog harbouring *E. sibiricensis* is a threat to persons coming in contact with it. We estimate conservatively that there is an average of one infected dog per team; however, this will vary according to the season of the year and the density of the vole population.

*Studies on the helminth fauna of Alaska*

415

Little is known about the contamination of food and water. Some vegetation is consumed unwashed when the Eskimo are away from the villages. The leaves of *Saxifraga punctata* L. and of *Salix* spp. are commonly eaten, and these are collected in places subject to contamination with the faeces of foxes. Green vegetation is preserved by freezing for use in the home, but it is possible that the cestode eggs are killed if the period of preservation is long enough.

Small ponds and other bodies of water may contain eggs of *Echinococcus* when foxes are abundant, and these might constitute a source of human infection under conditions of travel. We have successfully infected voles with eggs of *E. sibiricensis* kept in pond water at room temperature for 22 days. In the winter, the melting of ice in the home for water, without bringing the water to boiling or at least to a high temperature, might be hazardous. Ice for this purpose is cut and often stored near the house, where it is exposed to contact with excrement of dogs.

The eggs of *E. sibiricensis* are resistant to cold, and remain infective after prolonged exposure to freezing temperatures. Experimentally, we have found that some eggs remained infective after having been frozen at  $-26^{\circ}\text{C}$ . in a mixture of water and intestinal content of foxes for 60 days. Some eggs were still infective among a quantity exposed to temperatures as low as  $-56^{\circ}\text{C}$ . in the laboratory. The eggs of *E. sibiricensis* have been found to survive long periods frozen *in situ* in the carcasses of infected foxes.

Since the immediate village areas are largely free of vegetation, there is also the possibility of contamination of food by eggs in wind-borne dust. Schiller (1954) has shown experimentally that the eggs of *E. sibiricensis* may be transmitted to susceptible mammals by adult blowflies *Phormia regina* (Meigen). Blowflies of other species are numerous on St Lawrence Island, where they breed around the villages in carcasses of dogs and other animals, but it is unknown whether they have any part in the transfer of eggs under natural conditions.

## CONTROL OF ALVEOLAR HYDATID DISEASE

The control of alveolar hydatid disease on St Lawrence Island will depend upon the initiation and enforcement of measures designed to control dogs and improve sanitary conditions.\* Adequate precautions regarding the dogs are most important, since close association of the Eskimo and their sledge dogs is not to be avoided.

All dogs should be chained in areas which are free of vegetation and at a reasonable distance from the dwellings. No dogs should be allowed to run at large, and unwanted animals should be destroyed. The periodic treatment of dogs with an anthelmintic might significantly reduce the number of cestodes which they harbour, although this is doubtful, since the cestodes are so deeply embedded in the mucosa of the intestine. If dogs were appropriately controlled, the trapping of voles around the houses might aid in reducing the number of canine infections.

\* Following our recommendations, regulations prohibiting the export of dogs from St Lawrence Island were put into effect by military authorities in 1951, and by the Alaska Department of Health in March 1953.

The handling of foxes presents many problems. Fox trapping is a basic economic enterprise in which the Eskimo engage, and serious changes cannot be made. Obviously, then, the people must be instructed as to the proper handling of these animals. A special building could be provided for the thawing and skinning so that such work would not be done in the homes.

Interruption of the life cycle of the cestode by eliminating one of its hosts is not feasible. In view of the size of the island, any measure severe enough to kill many voles would be biologically unsound and unworthy of consideration. Since the island is naturally recolonized by foxes annually, control of these animals would be impracticable. Furthermore, the economy of the Eskimo would suffer seriously if the foxes were reduced in numbers.

It is especially important to prevent the introduction of the cestode on the North American continent. This seems altogether possible if regulations already established by the territorial government and military authorities, prohibiting export of any dogs, continue to be enforced.

In so far as malignant infections are concerned, morbidity can be reduced through an enlarged medical service equipped to undertake appropriate measures of diagnosis and treatment. At the present time, surgical intervention as early as possible provides the only adequate treatment of the disease, as has been emphasized by Henschen & Bircher (1945) and by Semenov (1954). The broad experience of Semenov led him to the conclusion that radical resection of the infected hepatic lobe is the only appropriate treatment. He stated (p. 24): '...resection of the liver cannot be done on the diffused form, as well as on the alveolar nodular form if the nodules are distributed throughout the whole liver.' Among forty-two patients upon whom Semenov conducted exploratory laparotomies, the diffuse form was seen in fifteen cases, and nodules in both lobes of the liver were present in twenty-five cases. He concluded that: '...in the presence of alveolar-nodular or the concentrated form if there is observable a lone parasitic cyst a radical operation is successful in almost 3/4 of the patients.' The prognosis is always poor when the disease exists in an advanced form.

#### SUMMARY AND CONCLUSIONS

It is concluded that *E. sibiricensis* is the etiologic agent of alveolar hydatid disease in man. The cestode has a wide distribution in Eurasia, and St Lawrence Island apparently represents the north-easternmost extent of its range. The study of the cestode in Europe has been complicated by the co-existence of *E. granulosus*, which does not occur on St Lawrence Island. Microtine rodents, particularly *Microtus* spp. and *Clethrionomys rutilus*, are the natural intermediate hosts of this cestode, although other species of mammals, including man, are parasitized with varying degrees of success on the part of the larval cestode.

Man is not a favourable host—a view supported by the fact that normal growth and reproduction (i.e. the production of scolices) rarely occur in man, as well as by the comparative study of larval development in various species of experimentally infected animals. Although the influencing factors have not been defined, the larval cestode can become established in some persons, persist, and cause

morbidity or even death. The number of eggs ingested and the physical condition of the host may be important. There is evidence that the larvae are in many cases overcome by the tissue response which they elicit.

Human infection is most likely to occur where cultural and social conditions enforce the close association of man and dog, as on St Lawrence Island and in the northern part of the Yakut Autonomous Republic, eastern Siberia. In such regions, dogs are kept for transportation or for herding, and climatic conditions, lack of education, and poverty make difficult the application of ordinary hygienic procedures. Human infections may also be found in northern Eurasia where trapping of the arctic fox is important economically. Military personnel stationed in such regions should not be permitted to have dogs as pets, and the care of work dogs should be carefully supervised.

In southern Europe and western Russia, dogs harbouring the adult cestodes may unknowingly be kept as pets, or for use with domesticated animals. The same situation would exist if the cestode were introduced into the United States or Canada. The earlier concept that alveolar hydatid disease is caused by *E. granulosus*, or at least by a cestode whose larval stage is found in domesticated animals, is especially misleading, since the slaughter of livestock in modern abattoirs effectively prevents access to infected offal by dogs. Dogs could ingest the larval cestode even in densely populated semi-rural areas if voles are present, so dissemination of information on the epidemiology of the disease will be important. Investigations being carried on by Dr Hans Vogel, Tropeninstitut, Hamburg, will undoubtedly produce the information essential to an understanding of the ecology of the cestode in Europe.\*

In treating patients having alveolar hydatid disease, a favourable prognosis can be made only if there is early diagnosis. The population should be aware of the seriousness of infection, and of its clinical signs. Application of clinical and serologic diagnostic procedures is required, and physicians who may receive patients from regions where the disease is endemic should be adequately instructed. Radical resection of the infected hepatic lobe is apparently the only satisfactory treatment at the present time. The ease with which the life cycle of *E. sibiricensis* can be studied in the laboratory permits investigations which have not been possible with *E. granulosus*. It is especially adaptable to studies on the effect of chemotherapeutic agents on the larval stage.

The writers take this opportunity to express appreciation for the assistance rendered in the course of this work by the following persons: Dr Thomas B. Magath, Mayo Clinic, Rochester, Minnesota, who performed the complement-fixation tests and offered many suggestions; Dr James G. Bridgens, Kansas City General Hospital, Kansas City, Missouri, who rendered valuable assistance in connexion with clinical observations on the St Lawrence Island Eskimo; Dr Francis H. Fay, University of British Columbia, Vancouver, B.C., who provided detailed field observations for the summer of 1953, and made available mammals

\* Since this paper was submitted, a preliminary report has been published by Vogel (*Dtsch. Med. Wschr.* **80**, pp. 931-32, 1955).



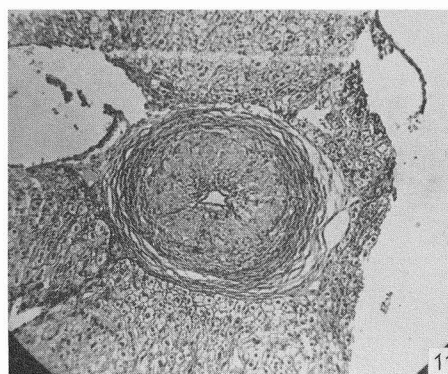
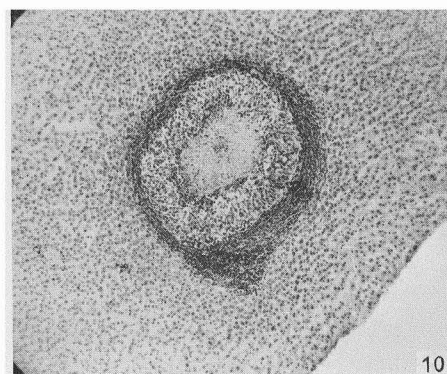
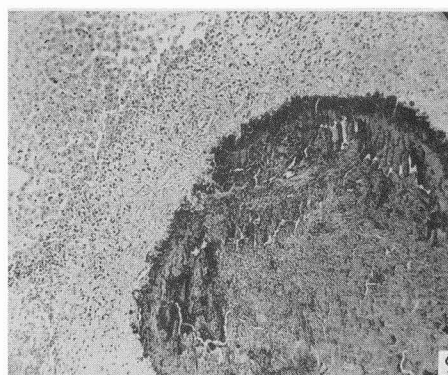
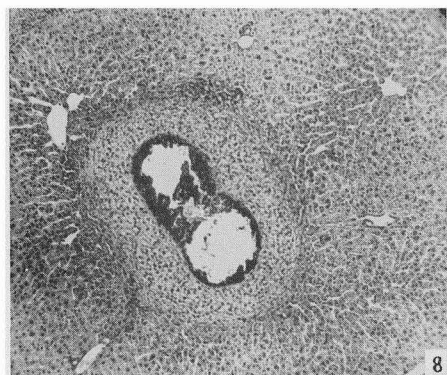
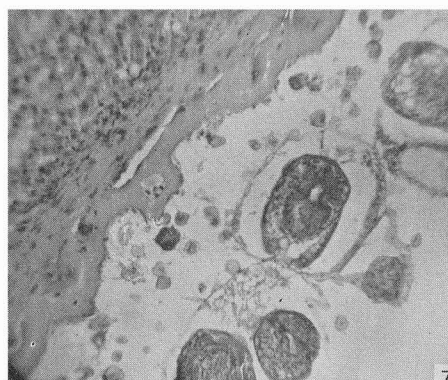
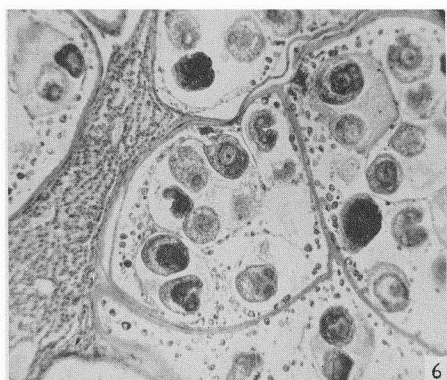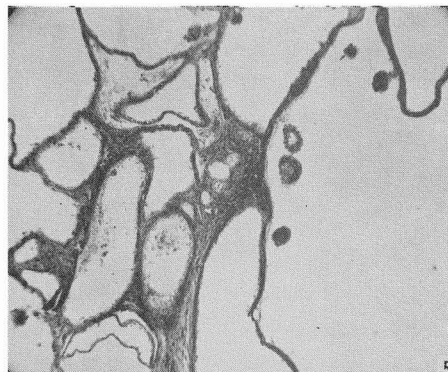
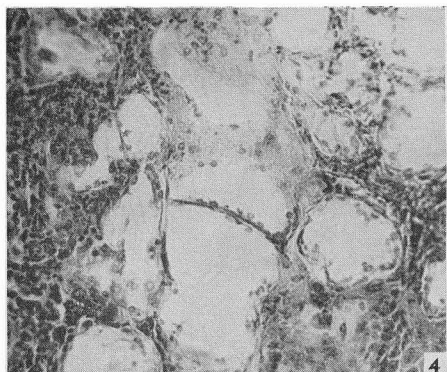
collected on St Lawrence Island; Dr Hans Vogel, Bernhard Nocht-Institut für Schiffs- und Tropenkrankheiten, Hamburg, who made available unpublished data on his investigation of alveolar hydatid disease in Germany; Miss Grace Crosson, R.N., Alaska Department of Health, who assisted whenever possible with work on St Lawrence Island; Mrs I. L. Wallace, Laboratory of Bacteriology of this Center, who rendered technical assistance; and Mrs Reggie V. S. Rausch, of this Center, who prepared all histological materials and figures. Other persons also, not specifically mentioned, are extended our best thanks. Surgical specimens were made available through the co-operation of the Tacoma Medical Center, Tacoma, Washington. The generous co-operation of the Eskimo of St Lawrence Island has done much to make this investigation possible, and we wish especially to acknowledge their contribution.

## REFERENCES

- AFANAS'EV, V. P. (1941). Parazitofauna promyslovykh mlekopitaiushchikh Komandorskikh Ostrovov. *Uchen. Zap., ser. biol. Nauk*, **18**, 93–117.
- BARABASH-NIKIFOROV, I. (1938). Mammals of the Commander Islands and the surrounding sea. *J. Mammal.* **19**, 423–9.
- BARABASH-NIKIFOROV, I. (1943). On the mouse-like rodents (Family Muridae) of the Commander Islands. (In Russian.) *Zool. Zh.* **22**, 53–4.
- DARDEL, G. (1927). Das Blasenwurmleiden in der Schweiz, speziell seine Verbreitung beim Mensch und Vieh und das Verhältnis von *Echinococcus alveolaris* zu *hydatidosus*. *Geographische, experimentelle und klinische Studie...* (mit Vorwort von Prof. A. Posselt), VI, 105 pp. Bern.
- DEW, H. R. (1953). Pleomorphism in hydatid disease. *Arch. int. Hidatid.* **13**, 284–95.
- HENSCHEN, C. & BIRCHER, R. (1945). Zur Epidemiologie, Pathologie und Chirurgie des *Echinococcus alveolaris*. *Bull. schweiz. Akad. med. Wiss.* **1**, 209–24.
- JOHANSEN, H. (1950). Polarraeven på Kommandøerne. *Nat. Verd., Kbh.*, **34**, 37–59.
- MAGATH, T. B. (1953). Diagnostic tests for hydatid disease based on immunologic phenomena. *Arch. int. Hidatid.* **13**, 218–28.
- POSSELT, A. (1904). *Echinococcus alveolaris* (multilocularis) des linken Leberlappens. (Sitzung 28 Nov. 1903, of Wiss. Aerztegesell. Innsbruck.) *Wien. klin. Wschr.* **17**, 89–90.
- POSSELT, A. (1925). Ueber Klinik und Pathologie des Alveolarechinococcus der Leber, seine geographische Verbreitung, insbesondere sein Vorkommen in den Alpenländern, speziell Tirol. *Schweiz. med. Wschr.* **55**, 593–605.
- RAUSCH, R. (1951). Biotic interrelationships of helminth parasitism. *Publ. Hlth Rep., Wash.*, **66**, 928–34.
- RAUSCH, R. (1952). Studies on the helminth fauna of Alaska. XI. Helminth parasites of microtine rodents—taxonomic considerations. *J. Parasit.* **38**, 514–44.
- RAUSCH, R. (1953a). On the land mammals of St Lawrence Island, Alaska. *Murrelet*, **34**, 18–26.
- RAUSCH, R. (1953b). The taxonomic value and variability of certain structures in the cestode genus *Echinococcus* (Rud., 1801) and a review of recognized species. *Thapar Commemoration Vol., University Lucknow*, 318 pp. India: Lucknow.
- RAUSCH, R. (1954). Studies on the helminth fauna of Alaska. XX. The histogenesis of the alveolar larva of *Echinococcus* species. *J. Infect. Dis.* **94**, 178–86.
- RAUSCH, R. & SCHILLER, E. L. (1951). Hydatid disease (Echinococcosis) in Alaska and the importance of rodent intermediate hosts. *Science*, **113**, 57–8.
- RAUSCH, R. & SCHILLER, E. L. (1954). Studies on the helminth fauna of Alaska. XXIV. *Echinococcus sibiricensis* n.sp., from St Lawrence Island. *J. Parasit.* **40**, 659–62.
- SCHILLER, E. L. (1954). Studies on the helminth fauna of Alaska. XIX. An experimental study on blowfly (*Phormia regina*) transmission of hydatid disease. *Exp. Parasit.* **3**, 161–6.
- SEME NOV, V. S. (1954). O rezektsii pecheni po povodu al'veoliarnogo ekhinokokka. *Věstník chirurgii*, **74**, 20–5.

PARASITOLOGY, VOL. 46, NOS. 3 & 4

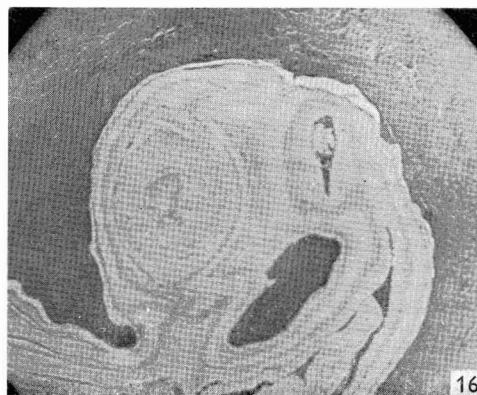
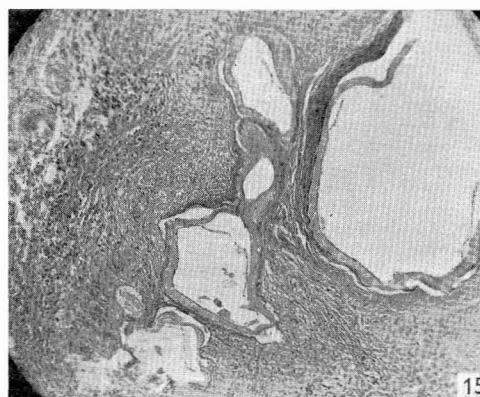
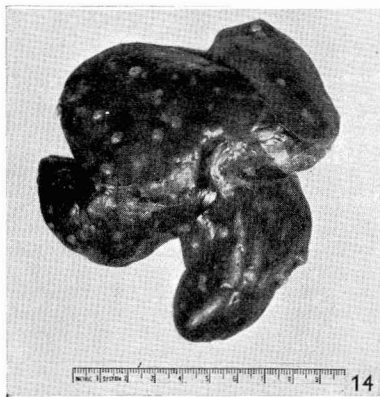
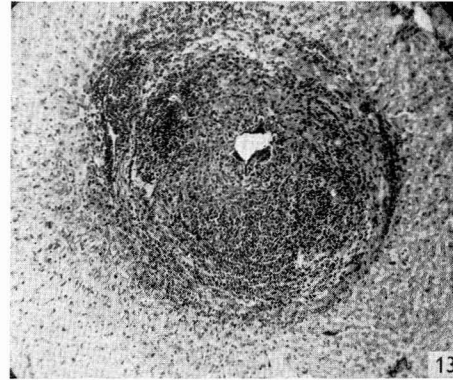
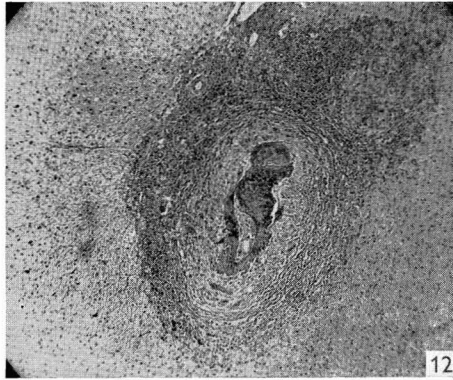PLATE VII



(Facing p. 418)

PARASITOLOGY, VOL. 46, NOS. 3 & 4

PLATE VIII



*Studies on the helminth fauna of Alaska*

419

- SPASSKII, A. A., ROMANOVA, N. P. & NAIDENOVA, N. V. (1951). Novye dannye o faune paraziticheskikh chervei ondatry—*Ondatra zibethica* (L.). *Akad. Nauk SSSR*, **5**, 42–52.
- STEJNEGER, L. (1884). Contributions to the history of the Commander Islands. No. 1. Notes on the natural history, including the descriptions of new cetaceans. *Proc. U.S. Nat. Mus.* **6**, 58–89.
- THOMAS, L. J., BABERO, B. B., GALLICCHIO, V. & LACEY, R. J. (1954). Echinococcosis on St Lawrence Island, Alaska. (Communication.) *Science*, **120**, 1102–3.
- VIRCHOW, R. (1855). Die multiloculäre, ulcerirende Echinokokkengeschwulst der Leber. *Verh. phys.-med. Ges. Würzb.* **6**, 84–95.

EXPLANATION OF PLATES VII AND VIII

PLATE VII. Sections of larval *Echinococcus sibiricensis* in livers of experimentally infected animals

- Fig. 4. Common field vole, 14 days after experimental infection; cells of germinal membrane prominent.  $\times 100$ . (All sections shown were stained with haematoxylin-eosin.)
- Fig. 5. Common field vole, 45 days after experimental infection, showing early scolices.  $\times 50$ .
- Fig. 6. Common field vole, 5 months after experimental infection (see Text-fig. 3).  $\times 100$ .
- Fig. 7. Brown lemming, 5 months after experimental infection; subgerminal membrane strongly developed.  $\times 100$ .
- Fig. 8. Varying lemming, 20 days after experimental infection.  $\times 50$ .
- Fig. 9. Varying lemming, 5 months after experimental infection.  $\times 50$ .
- Fig. 10. Hamster, 10 days after experimental infection.  $\times 50$ .
- Fig. 11. Domestic rabbit, 30 days after experimental infection.  $\times 50$ .

PLATE VIII. Section of larval *Echinococcus sibiricensis* in livers

- Fig. 12. Horse, 45 days after experimental infection.  $\times 50$ .
- Fig. 13. Rhesus monkey, 30 days after experimental infection.  $\times 50$ .
- Fig. 14. Rhesus monkey, 2½ months after experimental infection.
- Fig. 15. Sterile larval vesicles of *E. sibiricensis* in liver of man; natural infection of unknown duration.  $\times 50$ .
- Fig. 16. Area in liver of man (see Fig. 15), showing unusual degree of proliferation of subgerminal layer of larval *E. sibiricensis*.  $\times 50$ .

(MS. received for publication 9. VII. 1955.—Ed.)