

University of Nebraska - Lincoln

DigitalCommons@University of Nebraska - Lincoln

---

USDA National Wildlife Research Center - Staff  
Publications

U.S. Department of Agriculture: Animal and  
Plant Health Inspection Service

---

March 2001

## Development of *Sarcocystis falcatula* in its intermediate host, the Brown-headed Cowbird (*Molothrus ater*)

Shannon L. Luznar  
*University of Florida*

Michael L. Avery  
*USDA, APHIS, Wildlife Services, National Wildlife Research Center, michael.l.avery@aphis.usda.gov*

John B. Dame  
*University of Florida*

Robert J. MacKay  
*University of Florida*

Ellis C. Greiner  
*University of Florida*

Follow this and additional works at: [https://digitalcommons.unl.edu/icwdm\\_usdanwrc](https://digitalcommons.unl.edu/icwdm_usdanwrc)



Part of the [Environmental Sciences Commons](#)

---

Luznar, Shannon L.; Avery, Michael L.; Dame, John B.; MacKay, Robert J.; and Greiner, Ellis C., "Development of *Sarcocystis falcatula* in its intermediate host, the Brown-headed Cowbird (*Molothrus ater*)" (2001). *USDA National Wildlife Research Center - Staff Publications*. 605.  
[https://digitalcommons.unl.edu/icwdm\\_usdanwrc/605](https://digitalcommons.unl.edu/icwdm_usdanwrc/605)

This Article is brought to you for free and open access by the U.S. Department of Agriculture: Animal and Plant Health Inspection Service at DigitalCommons@University of Nebraska - Lincoln. It has been accepted for inclusion in USDA National Wildlife Research Center - Staff Publications by an authorized administrator of DigitalCommons@University of Nebraska - Lincoln.

## Development of *Sarcocystis falcatula* in its intermediate host, the Brown-headed Cowbird (*Molothrus ater*)

Shannon L. Luznar<sup>a</sup>, Michael L. Avery<sup>b</sup>, John B. Dame<sup>a</sup>,  
Robert J. MacKay<sup>c</sup>, Ellis C. Greiner<sup>a,\*</sup>

<sup>a</sup> Department of Pathobiology, College of Veterinary Medicine,  
University of Florida, Gainesville, FL 32611-0880, USA

<sup>b</sup> USDA, APHIS, Wildlife Services, National Wildlife Research Center,  
Florida Field Station, Gainesville, FL, USA

<sup>c</sup> Department of Large Animal Clinical Sciences, College of Veterinary Medicine,  
University of Florida, Gainesville, FL 32611-0360, USA

---

### Abstract

Sporocysts of *Sarcocystis falcatula* obtained from experimentally infected Virginia opossums (*Didelphis virginiana*) were inoculated orally to 60 wild-caught Brown-headed Cowbirds (*Molothrus ater*). Another 30 Brown-headed Cowbirds were not challenged and served as uninfected controls. Two inoculated and one control cowbird were necropsied every 2 weeks and the pectoral and thigh muscles were examined grossly for cyst development. Stained histologic sections of pectoral muscle, thigh muscle, and lung were examined by light microscopy and presence, density, and size of sarcocysts were determined. Sarcocysts were present by 6 weeks post-inoculation (PI) and were still growing at 40 weeks PI. The sarcocysts from birds 40 weeks post-infection were infective to an opossum. The morphology of the sarcocyst wall by transmission electron microscopy substantiated the identification as *S. falcatula*. Lung sections were examined for the presence of schizonts, but were seen only at 2 weeks PI. This evaluation was complicated by the presence of unidentified microfilariae. These birds are migratory and the continued growth and development of muscle cysts would allow them to be a source of infection at both extremes of their geographic range, regardless of which end of the migration at which they were infected. © 2001 Elsevier Science B.V. All rights reserved.

**Keywords:** *Sarcocystis falcatula*; *Molothrus ater*; Sarcocysts

---

\* Corresponding author. Tel.: +1-352-392-4700, ext.: 5861; fax: +1-352-392-9704.  
E-mail address: greinere@mail.vetmed.ufl.edu (E.C. Greiner).

## 1. Introduction

*Sarcocystis falcatula* is a protozoan parasite with an obligatory two host life cycle. It has been found to experimentally infect a wide range of intermediate hosts which includes Psittaciformes, Passeriformes, and Columbiforms. Anseriformes and Galliformes seem to be resistant to infection (Box and Smith, 1982). Natural infections have been documented in a variety of psittacines in captivity (Hillyer et al., 1991). The Brown-headed Cowbird (*Molothrus ater*) (Box and Duszynski, 1979), grackles (*Quiscalus mexicanus*, *Q. quiscula*), English sparrows (*Passer domesticus*), pigeons (*Columba livia*), and canaries (*Serinus canarius*) have been infected by sporocyst inoculation (Duszynski and Box, 1978; Box and Smith, 1982). The definitive host of this avian coccidian was determined to be the Virginia opossum (*Didelphis virginiana*) by Duszynski and Box (1978).

In the opossum, the life cycle includes a phase of sexual reproduction which is followed by sporogony, resulting in the production of sporozoites. This occurs in the intestinal epithelial cells (Box and Duszynski, 1980). The cycle continues when the sporocysts are shed in the feces of an infected opossum. The sporocysts are ingested by the intermediate host and asexual reproduction occurs and results in the formation of schizonts and sarcocysts (Box and Duszynski, 1978). Sarcocysts develop in striated muscles, primarily the leg and pectoral muscles. This protozoan parasite is sustained by an obligate predator–prey relationship. The sporocysts shed by the definitive host are infective only to the intermediate host. The muscle cysts that form in the intermediate host contain bradyzoites which are infective only to the definitive host which ingests the infected muscles.

Little is known about the course of development and duration of persistence of these sarcocysts in the natural intermediate host. It would be valuable to understand more about the life cycle of this parasite, including its development in the natural intermediate host. This type of knowledge will aid our understanding and be applicable to the prevention and treatment of diseases caused by this and related parasites. One such disease is equine protozoal myeloencephalitis (EPM) which is now a prominent neurologic disorder affecting the US horse industry. Initially, evidence indicated that the etiologic agent responsible for EPM was a *Sarcocystis* sp. (Simpson and Mayhew, 1980). This was based upon electron microscopy of schizonts in intact host cells and extracellular spaces. The etiologic agent of EPM was named *Sarcocystis neurona* (Dubey et al., 1991). There is a great deal of similarity of nucleotide sequences between these two species of *Sarcocystis* (Dame et al., 1995). Therefore, the development and persistence of *S. falcatula* may be applicable to *S. neurona*. This study was conducted to determine the longevity of sarcocysts and an indication of the duration of their infectivity.

## 2. Material and methods

### 2.1. Inoculum

Six opossums were wild caught in south central Florida and hand reared. They were fed Brown-headed Cowbirds which were determined to be naturally infected with *S. falcatula*. Sporocysts were collected from the feces of the infected opossums and stored less than

3 months prior to use. Preparation of the sporocysts consisted of placing 1–2 ml of fecal slurry which was determined to have approximately 150–200 sporocysts  $\text{ml}^{-1}$  in a 15 ml tube which was filled with 0.85% NaCl. The tube containing the sporocysts was centrifuged at 1600 rpm for 10 min. The supernatant was discarded and the pellet was washed again with NaCl repeating the former step. The pellet obtained after two washes was resuspended in Sheather's sugar solution and centrifuged as above. Cover slips were examined on 2 of every 12 tubes to insure that an adequate number of sporocysts (200–300) were collected. The uppermost 1 ml was recovered and the coverslip was washed into a 15 ml tube. The collected material containing sporocysts was washed with NaCl (0.85%) and centrifuged as above. The pellet was resuspended in 1 ml of NaCl and placed into a micro-centrifuge tube and centrifuged for 5 min. The pellet was resuspended in 0.1 ml of saline.

## 2.2. Cowbird acquisition and handling

Brown-headed Cowbirds were live trapped near Alachua County, Florida. They were surveyed for sarcocysts in the muscle during necropsy. The birds were skinned and muscles were examined without magnification and under a dissecting microscope ( $25 \times$  total magnification). The sections were cut at  $5 \mu\text{m}$  and were stained with hematoxylin and eosin. When cysts were detected grossly, they were confirmed by histologic examination.

Brown-headed Cowbirds that were to be inoculated with sporocysts were housed at the USDA National Wildlife Research Center, Gainesville, FL. No predators could gain access to the USDA housing. Those cowbirds held in captivity were fed corn mash and water ad lib daily. A group of 60 were inoculated per os with 200–300 sporocysts obtained from opossums previously infected by feeding sarcocysts in cowbird muscles. Cowbirds were inoculated by placing the inoculum into a syringe which had a small catheter tube attached to an 18 gauge needle. The birds drank the solution from the catheter tip when it was presented to the side of the beak. The fluid and sporocysts probably entered the mouth by capillary action. A group of 30 cowbirds was not inoculated and served as uninfected controls. These control birds functioned to screen for naturally infected birds in the general cowbird population.

## 2.3. Necropsy

Every 14 days, 3 birds (1 control and 2 inoculated) were euthanised and necropsied. The carcass was skinned and the pectoral and thigh muscles were examined grossly with a dissecting microscope to detect the presence of sarcocysts. A sample of lung, pectoral, and thigh muscle were collected and fixed in 10% (v/v) buffered formalin for light microscopy. These samples were embedded in paraffin. Sections were cut to a thickness of  $5 \mu\text{m}$  and stained with hematoxylin and eosin (H and E).

## 2.4. Parasite detection and measurements

Pectoral and thigh muscles contained sarcocysts which were measured by the same person using an ocular micrometer. The number of cysts per area of tissue was also determined. All measurements are given in  $\mu\text{m}$ . Lung sections were examined for the presence of schizonts.

### 2.5. Transmission electron microscopy

Representative sarcocysts seen in H and E stained slides were matched with paraffin blocks and the corresponding piece of tissue was cut out of the block. The portion of embedded tissue was deparaffinized with three 20 min xylene washes. The tissue was hydrated with 15 min washes in 100% acetone and a graded series of ethanol (100, 95, 75, 50 and 25%) and washed in phosphate-buffered saline solution (PBS, pH 7.2) for 15 min, before primary fixation in McDowell and Trumps fixative (pH 7.2) for 45 min, after which it was washed twice in PBS. Post-fixation was performed with 1% buffered osmium tetroxide for 45 min followed by PBS wash. After two distilled water washes, the sample was dehydrated in a graded ethanol series followed by 100% acetone. It was then infiltrated in a graded EMBED 812 epoxy resin (EMS, Fort Washington, PA) series for 1 h each and polymerized in 100% EmBed 812 for 2 days at 60°C. Ultrathin sections (70 nm) were collected on 100-mesh copper grids and post-stained with 2% uranyl acetate, followed by Reynold's lead citrate. The sections were examined on a Hitachi H-7000 transmission electron microscope and micrographs were taken on a Gatan Bio Scan Digital Camera with Digital Micrograph 2.5.

### 3. Results

The prevalence of *S. falcatula* in Brown-headed Cowbirds in Alachua County was 4.1% (11/268) in the fall of 1996.

The Brown-headed Cowbirds were necropsied from 2 to 40 weeks post-inoculation (PI). All birds inoculated were determined to be infected at or after 6 weeks PI. Muscle cysts were visible on gross inspection and thin white streaks against the red of the muscles and numerous sarcocysts were seen microscopically. The thigh sarcocysts were measured beginning at 6 weeks PI and the mean cyst size was  $35.4 \mu \times 107.1 \mu$ . They grew to a mean  $168.7 \mu \times 412.4 \mu$  at 40 weeks. The pectoral muscle sarcocysts initially measured were  $31.0 \mu \times 49.0 \mu$  and grew to be at least  $105.0 \mu \times 128.8 \mu$ . Growth continued over the 40-week time period (Figs. 1 and 2). According to this increase in size, the pectoral muscle sarcocysts did not degenerate, at least within the 40 weeks of study. Furthermore, the opossum fed muscles of birds necropsied at 40 weeks PI, began to shed sporocysts 8 days later.

The primary cyst wall of a sarcocyst 40 weeks PI contained evenly spaced, parallel microvillus-like projections that had an uneven thickness in the outer electron dense layer (hobnail appearance) (Fig. 3). Microtubules were obvious in the center of the projections. This sarcocyst was filled mainly with bradyzoites, but some larger cells, somewhat vacuolate and possibly degenerating were seen (=metrocytes?). The bradyzoites (not illustrated) contained numerous micronemes, which were not evident in the large degenerating cells.

One uninoculated control bird had sarcocysts (8 weeks PI) and these were few in number and much larger than those detected in the challenged birds necropsied at the same time.

The lung sections examined for the presence of shizonts contained microfilariae in 75% of the birds. Microfilariae were similar in appearance and size to schizonts and hindered the task of diagnosis. Schizonts were found only in the lung sections of birds necropsied 2 weeks PI.

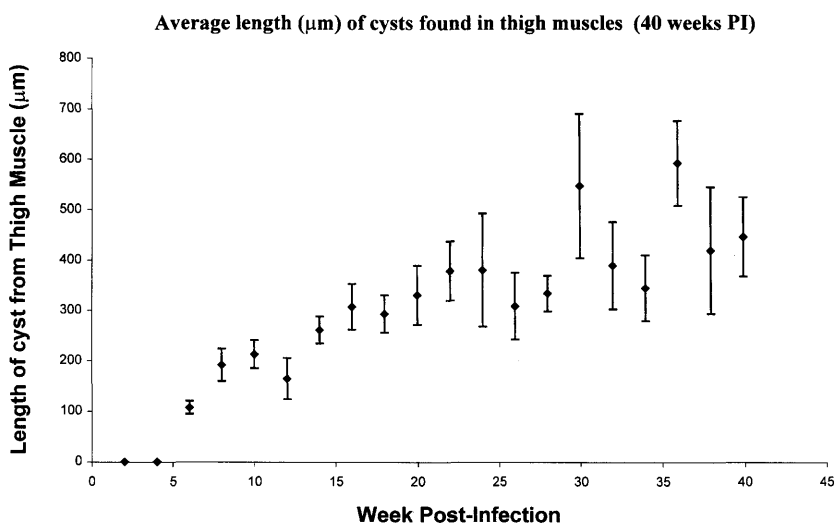


Fig. 1. Average length ( $\mu\text{m}$ ) of sarcocysts found in thigh muscles of experimentally infected cowbirds over a 40-week period. The vertical bars represent standard errors.

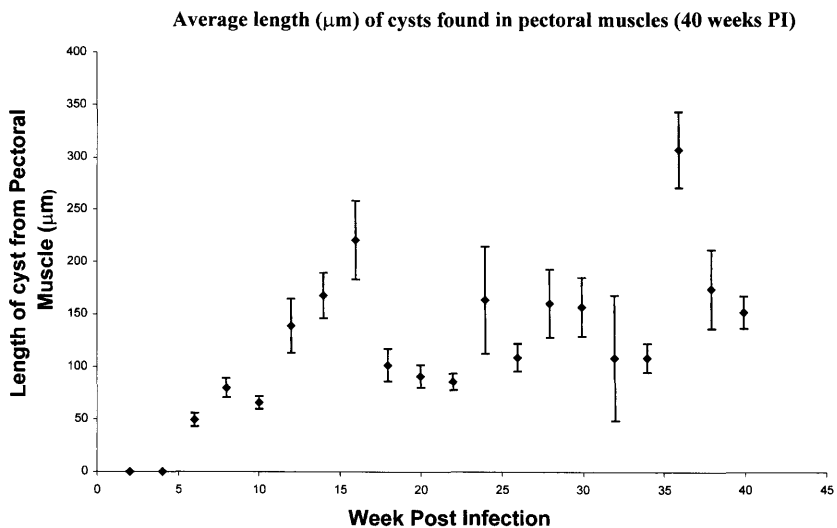


Fig. 2. Average length ( $\mu\text{m}$ ) of sarcocysts found in pectoral muscles of experimentally infected cow birds over a 40-week period. The vertical bars represent standard errors.

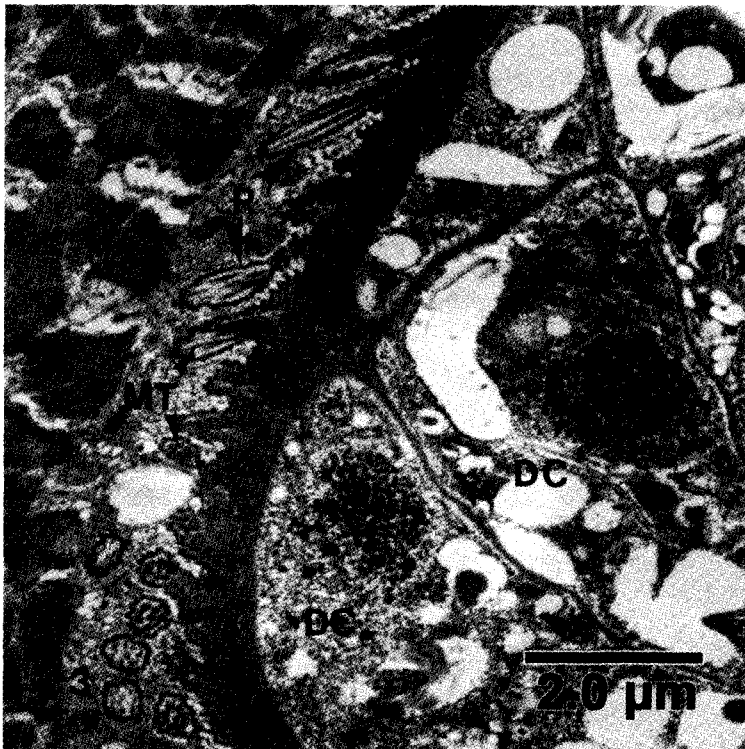


Fig. 3. TEM photomicrograph of a sarcocyst from an experimentally infected Brown-headed Cowbird. Note the hobnail appearance of the projection (P) seen in longitudinal and cross section, the microtubules (MT) within the projections and portions of two large degenerating cells (DC) within the sarcocyst.

#### 4. Discussion

The prevalence of *S. falcatula* in Brown-headed Cowbirds (4.1%) was drastically lower than that found in grackles in Maryland (93%) (Fayer and Kocan, 1971). Whether this varies at each location greatly among years is unknown.

Sarcocysts that developed had a spindle-shaped appearance similar to those described by Box and Duszynski (1978). Sarcocysts were present in both thigh and breast muscles at 6 weeks PI (microscopically and grossly). This differed from the 8 and 28-day developmental period for pectoral and leg muscle sarcocysts, respectively, in budgerigars (Smith et al., 1989). A linear increase in length of the muscle cysts in the thigh muscle occurred (Fig. 1). This finding differs from that found in budgerigars in which the muscle cysts degenerated between 28 and 42 days PI (Smith et al., 1989). An interesting note was that the number of sarcocysts in the legs was much higher than in the breast muscles. This might be a reflection of pectoral muscle sarcocysts degenerating as detected by Neill et al. (1989) in the breast and cardiac muscle of budgerigars. While we did not detect degeneration of sarcocysts at the light microscope level, we might have missed this happening in cowbirds.

The morphology of the sarcocysts was consistent with that illustrated for *S. falcatula* in canaries (Box et al., 1984), in budgerigars (Box et al., 1984; Neill et al., 1989) and in cowbirds (Dame et al., 1995). Even though there were some degenerating larger cells in the sarcocysts, the oldest sarcocysts were still infective as indicated by feeding them to an opossum.

Some of the cowbirds were naturally infected before capture as indicated by a control cowbird which had sarcocysts at 8 weeks PI. Other possibilities of sarcocysts developing in birds prior to capture included two birds that contained cysts that were much larger than others in birds of equivalent time PI. This occurred at 36 weeks PI (Figs. 1 and 2).

In conclusion, sarcocysts of *S. falcatula* remained viable for at least 40 weeks PI and do not degenerate in this time period in the natural intermediate host. This would easily provide a means of infection to opossums at the opposite end of the migratory route of the cowbirds from which it was infected.

### Acknowledgements

The authors would like to thank Kandy Roca and Misty Alserman for care of the Brown-headed Cowbirds. We would also like to thank Sarah Schaack for help with the statistical analysis. We appreciate the assistance of the Electron Microscopy Core Laboratory of the Interdisciplinary Center for Biotechnology Research. This study received financial support from the Parimutual Wagering Trust Fund of the Florida Department of Professional Regulation.

### References

- Box, E.D., Duszynski, D.W., 1978. Experimental transmission of *Sarcocystis* from icterid birds to sparrows and canaries by sporocysts from the opossum. *J. Parasitol.* 64, 682–688.
- Box, E.D., Duszynski, D.W., 1979. Survey for *Sarcocystis* in the Brown-Headed Cowbird (*Molothrus ater*): a comparison of macroscopic, microscopic, and digestion techniques. *J. Wildl. Dis.* 13, 356–359.
- Box, E.D., Duszynski, D.W., 1980. *Sarcocystis* of passerine birds: sexual stages in the opossum (*Didelphis virginiana*). *J. Wildl. Dis.* 16, 209–215.
- Box, E.D., Smith, J.H., 1982. The intermediate host spectrum in a *Sarcocystis* species of birds. *J. Parasitol.* 68, 668–673.
- Box, E.D., Meier, J.L., Smith, J.J., 1984. Description of *Sarcocystis falcatula* (Stile, 1893) a parasite of birds and opossums. *J. Protozool.* 31, 521–524.
- Dame, J.B., Mackay, R.J., Yowell, C.A., Cutler, T.J., Marsh, A., Greiner, E.C., 1995. *Sarcocystis falcatula* from passerine and psittacine birds: synonymy with *Sarcocystis neurona*, agent of equine protozoal myeloencephalitis. *J. Parasitol.* 81, 930–935.
- Dubey, J.P., Davis, S.W., Speer, C.A., Bowman, D.D., deLahunta, A., Granstrom, D.E., Topper, M.J., Hamir, A.N., Cummings, J.F., Suter, M.M., 1991. *Sarcocystis neurona* n. sp. (Protozoa: Apicomplexa), the etiological agent of equine protozoal myeloencephalitis. *J. Parasitol.* 77, 212–218.
- Duszynski, D.W., Box, E.D., 1978. The opossum (*Didelphis virginiana*) as a host for *Sarcocystis debonei* from cowbirds (*Molothrus ater*) and grackles (*Cassidix mexicanus*, *Quiscalus quiscula*). *J. Parasitol.* 64, 326–329.
- Fayer, R., Kocan, R.M., 1971. Prevalence of *Sarcocystis* in grackles in Maryland. *J. Protozool.* 18, 547–548.
- Hillyer, E.V., Anderson, M.P., Greiner, E.C., Atkinson, C.T., Frenkel, J.K., 1991. An outbreak of *Sarcocystis* in a collection of psittacines. *J. Zool. Wildl. Med.* 22, 434–445.



- Neill, P.G., Smith, J.H., Box, E.D., 1989. Pathogenesis of *Sarcocystis falcatula* (Apicomplexa: Sarcocystidae) in the budgerigar (*Melopsittacus undulatus*). IV. Ultrastructure of developing, mature, and degenerating sarcocysts. *J. Protozool.* 36, 430–437.
- Simpson, C.F., Mayhew, I.G., 1980. Evidence for *Sarcocystis* as the etiologic agent of equine protozoal myeloencephalitis. *J. Protozool.* 27, 288–292.
- Smith, J.H., Neill, P.J.G., Box, E.D., 1989. Pathogenesis of *Sarcocystis falcatula* (Apicomplexa: Sarcocystidae) in the budgerigar (*Melopsittacus undulatus*). Pathologic and quantitative parasitologic analysis of extrapulmonary disease. *J. Parasitol.* 75, 270–287.