

University of Nebraska - Lincoln

DigitalCommons@University of Nebraska - Lincoln

---

USDA Wildlife Services - Staff Publications

U.S. Department of Agriculture: Animal and  
Plant Health Inspection Service

---

2011

## Diseases and Parasites

Kurt C. Vercauteren

USDA-APHIS-Wildlife Services, kurt.c.vercauteren@usda.gov

Tyler A. Campbell

USDA-APHIS-Wildlife Services, tcampbell@eastfoundation.net

Follow this and additional works at: [https://digitalcommons.unl.edu/icwdm\\_usdanwrc](https://digitalcommons.unl.edu/icwdm_usdanwrc)



Part of the [Environmental Sciences Commons](#), and the [Life Sciences Commons](#)

---

Vercauteren, Kurt C. and Campbell, Tyler A., "Diseases and Parasites" (2011). *USDA Wildlife Services - Staff Publications*. 1021.

[https://digitalcommons.unl.edu/icwdm\\_usdanwrc/1021](https://digitalcommons.unl.edu/icwdm_usdanwrc/1021)

This Article is brought to you for free and open access by the U.S. Department of Agriculture: Animal and Plant Health Inspection Service at DigitalCommons@University of Nebraska - Lincoln. It has been accepted for inclusion in USDA Wildlife Services - Staff Publications by an authorized administrator of DigitalCommons@University of Nebraska - Lincoln.

## *Diseases and Parasites*

Tyler A. Campbell and Kurt C. VerCauteren

### CONTENTS

|   |     |
|---|-----|
| Introduction.....                           | 220 |
| Viral Diseases.....                         | 221 |
| Hemorrhagic Disease.....                    | 221 |
| Cutaneous Fibromas.....                     | 221 |
| Arboviruses.....                            | 222 |
| Other Viruses.....                          | 223 |
| Bacterial Diseases.....                     | 223 |
| Anthrax.....                                | 223 |
| Dermatophilosis.....                        | 224 |
| Brain Abscesses/Intracranial Abscesses..... | 225 |
| Bovine Tuberculosis.....                    | 225 |
| Johne's Disease/Paratuberculosis.....       | 227 |
| Leptospirosis.....                          | 228 |
| Salmonella.....                             | 228 |
| Lyme Disease.....                           | 229 |
| Rickettsial Diseases.....                   | 230 |
| Anaplasmosis.....                           | 230 |
| Chronic Wasting Disease.....                | 232 |
| Parasites.....                              | 234 |
| Protozoa.....                               | 234 |
| Toxoplasmosis.....                          | 234 |
| Babesiosis.....                             | 234 |
| Theileriosis.....                           | 234 |
| Trematodes.....                             | 235 |
| Liver Fluke.....                            | 235 |
| Nematodes.....                              | 235 |
| Large Lungworm.....                         | 235 |
| Large Stomach Worm.....                     | 236 |
| Meningeal Worm.....                         | 236 |
| Arterial Worm.....                          | 237 |
| Abdominal Worm.....                         | 238 |
| Cestodes.....                               | 238 |
| Larval Tapeworm.....                        | 238 |
| Arthropods.....                             | 238 |
| Ticks.....                                  | 238 |
| Ear Mites.....                              | 238 |
| Demodectic Mange.....                       | 240 |
| Other Common Arthropods.....                | 240 |
| Conclusions.....                            | 240 |
| References.....                             | 240 |

## Introduction

Wildlife biologists have long pursued understanding the ecology of diseases and parasites impacting white-tailed deer (e.g., see Whitlock, 1939), an important field of study because they can detrimentally affect deer populations, other wildlife, livestock, and humans (Davidson et al., 1981). Diseases and parasites of white-tailed deer, perhaps more than any other North American large mammal species, have received much attention in the literature and complete treatises have been devoted to the subject (e.g., see Davidson et al., 1981). In the last 20 years it has become necessary for wildlife biologists to incorporate disease concerns into the management of white-tailed deer (Figure 7.1). For example, at the federal level the United States Department of Agriculture (USDA), Animal and Plant Health Inspection Service is working to manage white-tailed deer diseases, some with implications for livestock health, including bluetongue (BT), bovine tuberculosis, cattle fever ticks, chronic wasting disease (CWD), and Johne's disease. Much of our knowledge stems from the exhaustive work with white-tailed deer diseases and parasites performed at the Southeastern Cooperative Wildlife Disease Study at the University of Georgia over nearly six decades (e.g., see Hayes et al., 1958). Recent advances in our understanding of the ecology of white-tailed deer diseases and parasites have also been made by state and federal agencies, and university scientists.

Numerous diseases and parasites cause morbidity and mortality in white-tailed deer. Altered deer behavior and reproductive success have also been noted (Matschke et al., 1984). White-tailed deer management programs should consider the significance of diseases and parasites early during the planning phases and throughout program implementation. Specifically, white-tailed deer biologists and managers would benefit by familiarizing themselves with the common infections and parasitic diseases of deer, including viruses, bacteria, infectious prions, and parasites. Herein, the purpose is to provide a brief synopsis of these diseases and parasites and the chapter is organized into primary headings of: viral diseases, bacterial diseases, rickettsial diseases, CWD, and parasites. For a more detailed account of many of these infectious and parasitic agents readers should peruse Davidson et al. (1981), Samuel et al. (2001), and Williams and Barker (2001). For an easy-to-use and practical field guide for many white-tailed deer diseases and parasites, readers should see Davidson (2006). Furthermore, this chapter does not consider the morbidity and mortality factors of toxicosis, environmental contaminants, trauma, and weather-related phenomenon.



**FIGURE 7.1** Personnel from the Michigan Department of Natural Resources and U.S. Department of Agriculture's Animal and Plant Health Inspection Service conducting necropsy on white-tailed deer under moderate biosecurity conditions. (Photo by Michigan Department of Natural Resources and Environment. With permission.)

## Viral Diseases

### Hemorrhagic Disease

Hemorrhagic disease (HD) in white-tailed deer populations is caused by orbiviruses, which occur in the family Reoviridae and are mostly double-stranded RNA viruses that are vector-borne (Roy, 1996). Of the >120 viral serotypes classified within 14 serogroups, only epizootic hemorrhagic disease (EHD) and BT viruses are associated with large-scale morbidity and mortality in white-tailed deer (Howerth et al., 2001). Two serotypes of EHD and six serotypes of BT occur in the United States, and all but BT serotype 2 (BT-2) have caused outbreaks of HD in white-tailed deer (Davidson, 2006; Murphy et al., 2006).

The clinical signs of HD are similar for both EHD and BT infections; however, there is much variability among deer populations and individuals may display chronic to peracute symptoms (Davidson, 2006). Although not completely understood, variation in clinical signs is likely related to differences in virus virulence (Howerth et al., 2001), innate host resistance (Gaydos et al., 2002b), cross-protection immunity (Gaydos et al., 2002a), and acquisition of maternal antibodies (Gaydos et al., 2002c). Furthermore, HD can be a slow and progressive (chronic form) disease resulting in changing clinical signs within infected individuals. In general, deer may exhibit depression, emaciation, facial swelling, fever, lameness, loss of appetite, reduced activity, and respiratory complications associated with HD (Howerth et al., 2001).

HD lesions are also variable and follow characterizations of being peracute, acute, and chronic. In the peracute form, animals often die rapidly and exhibit edema of the conjunctiva, head, lungs, neck, and tongue (Davidson, 2006). In the classic acute form of HD, peracute lesions often exist plus animals may display congestion or hemorrhages in the heart, intestines, and rumen, and necrosis on the dental pad, omasum, rumen, and tongue (Howerth et al., 2001). In addition to the above, deer displaying the chronic form of HD may have cracked or irregular hooves and loss of rumen papillae.

Wildlife hosts for HD include white-tailed deer and mule deer (Nettles and Stallkuecht, 1992). However, HD has been detected in pronghorn, bighorn sheep, bison, elk, and mountain goats (Howerth et al., 2001). Livestock hosts include cattle and sheep. Cattle are vulnerable to both EHD and BT viruses, but only rarely exhibit clinical signs. Sheep are not susceptible to EHD virus, but BT viruses may cause severe morbidity and mortality (Davidson, 2006).

Numerous serologic tests for antibodies to HD viruses exist, including agar gel immunodiffusion, serum neutralization, and competitive enzyme-linked immunosorbent assays (Howerth et al., 2001). These tests may be used to confirm activity of viruses in deer populations or to determine probable cause of lesions. Molecular techniques may also be used in diagnostics, including reverse transcriptase polymerase chain reaction (PCR) (Shad et al., 1997). A suspected diagnosis can be determined with the presence of gross lesions, but confirmed diagnoses require virus isolation from morbid or dead deer (Davidson, 2006).

HD is transmitted by several species of *Culicoides* midges (Gibbs and Greiner, 1989). Although viruses associated with BT are primarily vectored by *C. sonorensis*, other species are important for transmission to white-tailed deer (Howerth et al., 2001; Davidson, 2006). Seasonal peaks in HD occur in late summer and early fall and correspond with life cycles of their vectors (Davidson, 2006). Lesions of chronic forms of HD may be detected into winter (Howerth et al., 2001).

Of viral diseases, HD is the most important agent impacting white-tailed deer herds (Nettles and Stallkuecht, 1992). Nonetheless, population-level effects are not well documented (Fischer et al., 1995; Flacke et al., 2004; Gaydos et al., 2004). Risk factors associated with HD outbreaks in white-tailed deer populations are not clear and therefore management prescriptions for this disease have been elusive. Furthermore, funding for HD research has been limited in part because the disease is not zoonotic and human disease has not been reported with either EHD or BT viruses.

### Cutaneous Fibromas

Fibromas and papillomas are hairless tumors or warts infecting white-tailed deer and other mammals that are caused by papillomaviruses. These double-stranded DNA viruses (Watson and Littlefield, 1960) are comprised of a nonenveloped icosahedral capsid structure 50–55 nm in diameter (Pfister, 1987).





**FIGURE 7.2** Cutaneous fibromas on a white-tailed deer. (Photo by D. G. Hewitt. With permission.)

There are >125 papillomaviruses that infect >50 mammalian species, including six that have been found on Cervidae (Sundberg et al., 1997).

Fibromas infecting white-tailed deer are cutaneous and occur on the surface of the skin (Figure 7.2). Deer infected with fibromas seldom develop clinical disease. However, deer with heavy tumor loads may suffer from exhaustion and incapacitation due to tumors interfering with vision, respiration, food ingestion, and locomotion (Sundberg et al., 2001). Cutaneous fibromas are self-limiting and lesions normally regress, a process related to the development of antibodies and immunity (Ghim et al., 2000). Population-level impacts to white-tailed deer do not occur (Davidson, 2006).

Cutaneous fibromas may be found at any location on white-tailed deer and are usually smooth, but they may also be convoluted and resemble the head of a cauliflower (Davidson, 2006). Fibromas are commonly black, but may also be gray or white in color (Sundberg et al., 2001). The abundance and size of fibromas vary with severity of infection, but fibromas ranging from 1 to 10 cm in diameter are common.

Papillomaviruses infect species-specific mammalian hosts (Sundberg et al., 1997). Under natural conditions, the papillomaviruses that infect white-tailed deer are believed to only infect deer. However, experimental inoculation studies have demonstrated a white-tailed deer papillomavirus infection within hamsters (Koller and Olson, 1972). Cross-species transmission has not been demonstrated under natural conditions.

With a considerable amount of certainty, cutaneous fibromas can be diagnosed from gross observation of lesions (Sundberg et al., 2001). Histological determination is considered confirmatory and can be performed on tumor biopsies preserved in 10% buffered formalin (Davidson, 2006). Additional tests can be conducted using monoclonal and polyclonal antibodies to determine evidence of productive infections and to type papillomas through immunohistochemistry (Lim et al., 1990; Sundberg et al., 1996; Jensen et al., 1997).

Historically, sparring male white-tailed deer were hypothesized to spread cutaneous fibromas through direct contact with lesions (Friend, 1967). While infection via contact has not been verified, papillomavirus infections are believed to be transmitted from deer to deer by insect vectors and direct contact with abrasive fomites (Davidson, 2006).

More than 80 human papillomaviruses are known to exist (Sundberg et al., 1997). However, because papillomaviruses are specific to particular mammalian hosts, cutaneous fibromas from white-tailed deer are not infectious to humans. Furthermore, fibromas are only skin-deep and once skinned, harvested animals are suitable for consumption (Sundberg et al., 2001).

## **Arboviruses**

Several arboviruses (arthropod-borne viruses), which replicate in blood-feeding arthropods such as mosquitoes, have been found in white-tailed deer (Yuill and Seymour, 2001). For example, West Nile

virus was the cause of death in a white-tailed deer in Georgia (Miller et al., 2005) and eastern equine encephalitis infection within white-tailed deer has been found in Michigan (Schmitt et al., 2007) and Georgia (Tate et al., 2005). However, with the exception of vesicular stomatitis (VS), these arboviruses have not been determined to impact deer populations and are considered insignificant (Forrester, 1992). Lesions associated with VS include vesicles (or blisters) on the skin of the feet or mouth indistinguishable from lesions associated with foot-and-mouth disease (FMD). Because FMD is a highly contagious foreign animal disease, it is important to report any deer found with fluid-filled blisters on the mouth, tongue, muzzle, teats, and feet to animal health authorities and to not move the animal or carcass from the site (Davidson, 2006).

## Other Viruses

White-tailed deer have been found with common cattle viruses including bovine viral diarrhea virus (Passler et al., 2007, 2009; Ridpath et al., 2007; Chase et al., 2008), malignant catarrhal fever (Forrester, 1992), and infectious bovine rhinotracheitis (Cantu et al., 2008). Under normal circumstances these viruses are not believed to significantly impact white-tailed deer populations. Other viruses that may infect white-tailed deer are rabies (Davidson, 2006), pseudorabies (Forrester, 1992), and parainfluenza virus (Forrester, 1992).

---

## Bacterial Diseases

### Anthrax

Anthrax is a highly lethal disease caused by the bacterium *Bacillus anthracis*, which belongs to the family Bacillaceae. *B. anthracis* is rod shaped and usually surrounded by a capsule. It forms spores and produces toxin. The vegetative form of this bacterium is susceptible to environmental degradation, while spores are very resistant and capable of surviving almost indefinitely under favorable conditions ( $200 \pm 50$  years) (de Vos, 2003). Anthrax spores are found on every continent except for Antarctica.

Depending on how *B. anthracis* enters the body of the host, the bacterium can cause cutaneous, respiratory, or gastrointestinal infections. The clinical disease is short in duration, sometimes resulting in sudden death of infected individuals. Clinical signs have not been reported in deer (Davidson and Nettles, 1997) though numerous in other animals, including dehydration, scouring, constipation, grinding teeth (Buxton and Barlow, 1994), fever, rapidly progressing debility, disorientation, respiratory distress (Cormack Gates et al., 2001), apoplectic seizures, depression, staggering gait (Van Ness, 1981), and swelling of the face, throat, and neck (de Vos, 2003). Infected individuals may also produce bloody discharges from orifices (Buxton and Barlow, 1994; Mackintosh et al., 2002) and subcutaneous edematous areas (Van Ness, 1981). Death can occur shortly after onset of clinical signs and several animals may die in close succession.

Animals with anthrax, a septicemic disease, may develop edema, hemorrhage, and necrotic lesions (de Vos, 2003). Sero-sanguinous fluid may be observed exuding from the nostrils and copious amounts of fluid may be present in the body cavity (Kellogg et al., 1970; Mackintosh et al., 2002). The blood is generally thick and dark, clots poorly, and flows freely from cut surfaces of infected carcasses (Cormack Gates et al., 2001).

Anthrax is most prevalent in wild and domestic mammalian herbivores, although birds and carnivores may also contract the disease (de Vos, 2003). Some mammalian carnivores and avian scavengers are resistant to the disease and act as carriers of *B. anthracis* spores (Cormack Gates et al., 2001). The bacteria can infect and be lethal to humans.

Anthrax is diagnosed by isolating *B. anthracis* from stained blood films (Buxton and Barlow, 1994; Mackintosh et al., 2002). Spores can easily be isolated from blood in the last few hours before death to one hour after (Cormack Gates et al., 2001). Because a carcass suspected to be infected with anthrax should not be opened, swabbings of mouth, nares, and anus can be used to diagnose the disease (Cormack Gates et al., 2001).



Anthrax epidemics in herbivores generally occur by ingesting food or water contaminated with *B. anthracis* spores (Choquette, 1970). Seasonally, these epidemics typically occur during dry summers following periods of heavy rain. These rain events promote runoff and areas of standing water accumulate *B. anthracis* spores. The dry weather that follows concentrates spores even more in these depressions, creating highly contaminated areas (Cormack Gates et al., 2001). Transmission can occur via cutaneous, respiratory, or gastrointestinal infections. Insect vectors, such as house flies and other arthropods, including biting flies, mosquitoes, and ticks may also transmit the disease (de Vos, 2003). Scavengers and predators may also disseminate the disease by feeding on and dismembering infected carcasses and spreading pathogens across the landscape (Choquette, 1970; de Vos, 2003).

Anthrax outbreaks in livestock can be controlled and even eradicated through quarantines and vaccinations, but applying these measures to free-ranging wildlife is currently impossible (Hugh-Jones and de Vos, 2002). A key to preventing or limiting new outbreaks is reducing soil contamination with *B. anthracis* spores; unfortunately, no current management practices to do so exist (Cormack Gates et al., 2001). Reducing animal densities in endemic areas will not prevent anthrax from occurring, but might limit the number of individuals exposed and thereby lessen mortality (Van Ness, 1981). In the event of an outbreak, easy to erect temporary fencing or other means to prevent infected animals from leaving the outbreak area and contacting other animals should be considered.

Anthrax is highly lethal in humans when left untreated. There are effective antibiotic therapies to treat the disease, but only when initiated immediately (Van Ness, 1981). Humans may become infected via inhalation, ingestion, or cutaneous exposure. Handling infected animals or infected animal products are common routes of human infection (Choquette, 1970; Van Ness, 1981). Early detection and treatment is critical in regulating incidence of the disease in humans (Choquette, 1970).

## Dermatophilosis

Dermatophilosis is a skin disease caused by the bacterium *Dermatophilus congolensis*, of the family Dermatophilaceae. Dermatophilosis is distributed worldwide and is most common in ruminants (Salkin et al., 1983), but is most pronounced in tropical and subtropical climates (Roscoe et al., 1975). These bacteria are aerobic, Gram-positive, and nonacid-fast (Salkin and Gordon, 1981).

Clinical signs include areas of hair loss, thick scabs, emaciation (Leighton, 2001), a decline in overall physical activity, and potentially death (Salkin and Gordon, 1981). In white-tailed deer, fawns have been reported as more adversely affected than adults (Salkin and Gordon, 1981). Typical lesions consist of raised, matted hair tufts, held stiffly by an enveloping crust of shed epidermis and exudates (Leighton, 2001). These lesions or encrustations may become detached revealing pus and a red, inflamed dermis that bleeds (Leighton, 2001). Severe hair loss may also result and lesions may be found all over the affected animal, especially around the eyes, ears, and muzzle.

*D. congolensis* has a wide host range and is found in many parts of the world. Domestic animals are affected most frequently by the disease, but it also occurs in wild animals and humans (Salkin and Gordon, 1981). In North American wild animals in particular, the disease has been found in white-tailed deer, raccoons, woodchucks, striped skunks (Salkin et al., 1983), mule deer (Williams et al., 1984), rabbits, and rodents (Richard, 1981).

Presumptive diagnosis of *D. congolensis* depends on observations of gross lesions on infected animals and is verified by microscopic examinations of stained smears or histologic sections of scabs (Leighton, 2001). Under magnification, two parallel rows of Gram-positive bacteria form a hypha-like array (Leighton, 2001). The best place to collect bacteria needed for microscopic examination is the moist undersurface of freshly removed, uncontaminated scabs.

*D. congolensis* transmission may occur from direct contact or insect vectors (Salkin et al., 1983). Lesions or scabs on infected individuals contain *D. congolensis* bacteria and contact with them may be a route for direct disease transmission. Infected scabs may also fall off individuals and contaminate the environment, but the bacterium cannot persist for long periods outside a suitable host (Leighton, 2001). Insect vectors that have been implicated in transmitting the disease include mosquitoes, mange mites, ticks, and biting and nonbiting flies (Salkin and Gordon, 1981). Moisture facilitates release of the motile zoospore phase of the bacterium, thereby enhancing transmission (Williams et al., 1984).

Animals with *D. congolensis* can be treated successfully with antibiotics. Free-ranging wildlife may become a reservoir for the disease and potentially transmit dermatophilosis to domestic livestock and humans (Salkin and Gordon, 1981). In white-tailed deer it has been reported as self-limiting but may exhibit spontaneous remissions (Salkin and Gordon, 1981). Controlling biting insects is believed to reduce the disease in animal populations (Leighton, 2001).

Dermatophilosis is a contagious, zoonotic disease and human cases are usually associated with handling diseased animals. Lesions are typically found on hands and feet in humans (Hyslop, 1980). Infected humans usually heal with minimal treatment (Hyslop, 1980). When handling diseased animals, gloves and protective coveralls should be worn to prevent infection.

### Brain Abscesses/Intracranial Abscesses

Brain abscesses are bacterial infections in the skull and brain. Although numerous genera of bacteria have been isolated, *Arcanobacterium pyogenes* is the primary bacteria found in brain abscesses of white-tailed deer (Davidson and Nettles, 1997; Baumann et al., 2001). *A. pyogenes* is a pyogenic, Gram-positive bacterium (Sneath et al., 1986).

Clinical signs include lack of coordination and fear, blindness, weakness, profound depression, emaciation, circling, single instances of torticollis, bilateral horizontal nystagmus, lameness, fever, and anorexia (Davidson et al., 1990). Lack of fear may result in wild animals walking toward humans and allowing handling or displaying the apparent desire to be handled (Debbie, 1965).

As bacterial infection develops in the brain a membrane forms around the area and a mass or lesion develops. The mass may vary in size and be filled with a creamy purulent material or pus (Debbie, 1965; Davidson and Nettles, 1997). Swelling and inflammation intensifies in response to infection. Signs of brain abscesses may also be evident by examination of skulls of infected individuals, often revealing erosion or pitting of cranial bones (Davidson et al., 1990). In white-tailed deer, lesions are often associated with antler pedicels of adult males (Davidson et al., 1990; Davidson and Nettles, 1997).

Brain abscesses occur in many species of mammals (Davidson et al., 1990), though rather infrequently in white-tailed deer (Davidson and Nettles, 1997; Baumann et al., 2001). When found in white-tailed deer, they have a strong bias toward adult males and incidence of the disease is seasonal, most likely due to velvet shedding, antler casting (Davidson and Nettles, 1997; Baumann et al., 2001), or a result of trauma associated with fighting with other males during the rut. Diagnosis includes opening brain cases to reveal the presence of abscesses or, if only skeletal remains are found, erosion or pitting of cranial bones (Davidson et al., 1990; Davidson and Nettles, 1997; Baumann et al., 2001; Karns et al., 2009).

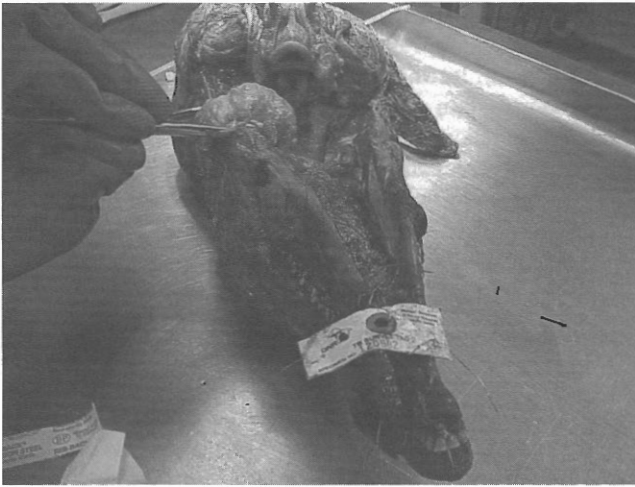It is not known whether brain abscesses can be transmitted between animals by direct contact (Davidson and Nettles, 1997). *A. pyogenes*, the primary bacteria found in brain abscesses of white-tailed deer, has been found in the nasopharyngeal mucosa of male deer suggesting that the direct contact of sparring males could transmit the disease among individuals (Karns et al., 2009).

Low prevalence rate in white-tailed deer suggests that overall this disease is not an important natural mortality source (Baumann et al., 2001). However, strong bias toward antlered males may affect management efforts to produce older-age males (Davidson and Nettles, 1997; Baumann et al., 2001).

### Bovine Tuberculosis

Tuberculosis is a chronic, zoonotic bacterial disease found primarily in cattle, although it has a broad host range (Palmer et al., 2000). The causative agent is *Mycobacterium bovis*, a nonsporulating, nonmotile, Gram-positive bacteria (Clifton-Hadley et al., 2001). Clinical signs of *M. bovis* infection may become apparent in weeks or take several years (Clifton-Hadley et al., 2001; de Lisle et al., 2002). Clinical signs include weight loss, swollen lymph nodes, discharging lymph node abscesses (Figure 7.3), coughing, and exercise intolerance (de Lisle et al., 2002; Mackintosh et al., 2002). Bovine tuberculosis is typically characterized by the formation of granulomas (Fitzgerald et al., 2000; de Lisle et al., 2002; Mackintosh et al., 2002). Tuberculosis granulomas have been observed in lungs, lymph nodes, and pericardium of white-tailed deer (Schmitt et al., 1997; O'Brien et al., 2001; de Lisle et al., 2002).





**FIGURE 7.3** White-tailed deer head with swollen lymph node and abscesses. (Photo by Michigan Department of Natural Resources and Environment. With permission.)

White-tailed deer are the primary maintenance host of the disease in North America. Other wildlife species that can horizontally transmit *M. bovis* infection include brush-tailed possum, European badger, bison, and African buffalo (de Lisle et al., 2002). North American elk, red deer, fallow deer, Arabian oryx, dromedary camels, llamas, alpacas, and Asiatic water buffalo are other wildlife species that have been diagnosed with *M. bovis* (Hunter, 1996; Isaza, 2003). Additionally, coyotes can serve as sentinels for the disease in the environment (VerCauteren et al., 2008b).

Macroscopic examination of suspect tuberculosis lesions is frequently used to presumptively diagnose *M. bovis* infection postmortem (Figure 7.4) (Clifton-Hadley et al., 2001; de Lisle et al., 2002; Mackintosh et al., 2002). Histopathologic examination of suspect tuberculosis lesions and bacterial culture are the primary means used to diagnose *M. bovis* infection (de Lisle et al., 2002; Mackintosh et al., 2002). Another diagnostic test for deer includes a composite immune cell and antibody test (Mackintosh et al., 2002).



**FIGURE 7.4** Tissue collection from white-tailed deer for presumptive diagnosis. (Photo by Minnesota Department of Natural Resources. With permission.)

Tuberculosis can be spread by either oral or respiratory routes (Mackintosh et al., 2002; Palmer et al., 2002). Routes of infection include contact with contaminated feed, mutual grooming, and inhaling infected droplets of fluid from the respiratory tract of infected individuals or the environment (Schmitt et al., 1997; Mackintosh et al., 2002; Palmer et al., 2004).

The presence of bovine tuberculosis in deer and subsequent transmission to cattle can severely impact local cattle industries. Restricting supplemental feeding and baiting of white-tailed deer is thought to reduce transmission of *M. bovis* bacteria (Schmitt et al., 1997; Palmer et al., 2001, 2004; O'Brien et al., 2002). Increasing harvest of deer to reduce densities and therefore the potential for disease transmission has also been practiced (O'Brien et al., 2006). The use of fencing, livestock protection of dogs, and specialized frightening devices can serve to reduce deer contact with cattle and feed meant for cattle (VerCauteren et al., 2006, 2008a; Seward et al., 2007).

*M. bovis* in humans is most commonly associated with consumption of raw, unpasteurized milk products (Isaza, 2003). Tuberculosis transmission from white-tailed deer to humans through consumption of infected meat, field dressing, or inhaling droplets from infected deer is unlikely, but can occur (Wilkins et al., 2003; de la Rua-Domenech, 2006).

### Johne's Disease/Paratuberculosis

Johne's disease, also known as paratuberculosis, is a contagious, chronic, and often fatal infection that primarily affects small intestines of ruminants (Stabel, 1998; Manning, 2001). Johne's disease is caused by *Mycobacterium paratuberculosis* and is found worldwide. The bacterium is resistant to low pH, high temperature, and chemical agents, which leads to persistence in the environment (Manning, 2001).

Clinical symptoms include diarrhea, weight loss, decreased milk production, inappetence, and emaciation (Rosen, 1981; Stabel, 1998; Manning, 2001). Progression of the disease may be more rapid in deer than cattle (Williams, 2001). Typical gross lesions include thickening of intestinal walls in the posterior ileum and colon and enlargement of adjacent lymph nodes (Rosen, 1981; Manning, 2001; Isaza, 2003). Lesions in deer may not always be present and the intestinal wall can appear normal or only slightly edematous (Williams, 2001).

Johne's disease has been reported in domestic (e.g., cattle, goats, and sheep) and wild and captive ruminants (e.g., axis deer, fallow deer, red deer, reindeer, roe deer, sika deer, white-tailed deer, elk, moose, bison, aoudad, mouflon, and bighorn sheep) (Soltys et al., 1967; Libke and Walton, 1975; Davidson and Nettles, 1997; Manning, 2001).

There are many tests that will diagnose Johne's disease, each with their own advantages and disadvantages; but there is no single test that will diagnose all stages of the disease and subclinical carriers (Williams, 2001). The disease can be diagnosed from observing clinical signs, culture, immunological tests, or polymerase chain reaction (Williams, 2001).

*M. paratuberculosis* is predominately spread by ingesting food or water contaminated with infected feces (Mackintosh et al., 2002). Offspring may also become infected by ingesting contaminated milk (Williams, 2001; Mackintosh et al., 2002). Fecal shedding of *M. paratuberculosis* by apparently healthy animals may occur unknowingly for years and serve as a primary source of transmission (Williams and Barker, 2001).

With the exception of a few local populations, Johne's disease infrequently occurs in wild ruminants in North America (Williams, 2001) and white-tailed deer are not a major reservoir for the disease (Davidson and Nettles, 1997; Sleeman et al., 2009). Conversely, cattle producers incur large economic losses from Johne's disease and prevalence rates of 7–10% have been reported (Davidson and Nettles, 1997). Management of the disease may include minimizing contact between infected and uninfected individuals, moving or relocating individuals from only *M. paratuberculosis*-free herds or areas, and testing for *M. paratuberculosis* as part of a herd-health monitoring plan (Williams, 2001). Even though there are similarities between Johne's disease and Crohn's disease, a debilitating chronic inflammatory bowel disease found in people, no records exist of Johne's disease being transmitted to humans (Van Kruiningen, 2001).

## Leptospirosis

Leptospirosis is caused by the spirochetal bacterium *Leptospira interrogans* (Bolin, 2003). These spirochete bacteria or leptospires are slender, Gram-negative aerobes, actively motile, and distributed worldwide (Roth, 1970; Bolin, 2003). There are 184 serovarieties or "serovars" of *Leptospira* belonging to 20 serogroups (Shotts, 1981). Naturally infected white-tailed deer rarely exhibit clinical leptospirosis signs (Davidson and Nettles, 1997). White-tailed deer experimentally inoculated subcutaneously with leptospirosis also showed no obvious clinical signs (Reid, 1994), but deer experimentally infected with serovariety *L. interrogans pomona* developed nephritis, hepatitis, and hemorrhages (Shotts, 1981). Hemorrhages, liver enlargement, edema, congestion in lungs, and hematuria were observed in cervids with leptospiral antibodies (Mackintosh et al., 2002).

Leptospirosis is a worldwide disease that can infect humans and many wild and domestic animals (Mackintosh et al., 2002). Different serovars are associated with particular host species, which are then important reservoirs of the disease (Bolin, 2003). Common wild and domestic animal maintenance hosts include raccoons, opossums, skunks, rats, mice, cattle, dogs, swine, and horses (Bolin, 2003). Diagnosis of leptospirosis is difficult and tests can be separated into those designed to detect antibodies and those designed to detect leptospires (Bolin, 2003). Examining body fluids and tissues with microscopy and fluorescent antibody techniques will provide confirmation of disease existence (Mackintosh et al., 2002).

Direct or indirect contact with infected urine, placental fluids, or milk will transmit leptospirosis (Bolin, 2003). Leptospiral organisms can survive outside the host for several months if protected from sunlight and conditions are damp and temperate (Mackintosh et al., 2002; Bolin, 2003). Vaccination can reduce the risk of exposure to leptospirosis (Mackintosh et al., 2002). If an animal is showing clinical signs attributable to *Leptospira*, appropriate treatment may be ampicillin and tetracyclines (Reid, 1994). Limited information suggests that white-tailed deer do not play a major role in the maintenance and spread of leptospirosis (Trainer et al., 1963; Shotts, 1981; Goyal et al., 1992). Leptospirosis is rarely found in white-tailed deer and risk of contracting the disease from deer is low (Shotts, 1981).

## Salmonella

Bacteria of the family Enterobacteriaceae and genus *Salmonella* are small nonspore-forming facultative Gram-negative rods that cause enteric or systemic infection. They are ubiquitous and highly adaptable, infecting a variety of vertebrates with little host preference. *Salmonella* bacteria can be responsible for both human and animal illness, most commonly manifesting as gastroenteritis. In certain *Salmonella* infections, for example, typhoid fever, systemic infections may also occur (Robinson, 1981). *Salmonella* bacteria have been generally classified into three species: *S. typhi*, *S. choleraesuis*, and *S. enteritidis*. The first two consist of single serotype, whereas the latter consists of more than 2400 serotypes (Ketz-Riley, 2003).

In deer, salmonellosis most commonly occurs in fawns. Clinical salmonellosis may manifest as primary enteritis and colitis, generalized infection (septicemia), or abortion (Clarke and Gyles, 1993). The disease occurs in all forms from peracute to chronic. Mild salmonellosis is characterized by mild gastroenteritis with vomiting and diarrhea. Diarrheic feces are often yellowish gray, spotted with blood, and have a foul odor (Davidson and Nettles, 1997). Anorexia, lethargy, fever, polydipsia, depression, recumbency, opisthotonos, and dehydration can occur (Mackintosh et al., 2002).

Gross lesions are not pronounced though edema may occur in mesenteric lymph nodes (Davidson and Nettles, 1997). In septicemic cases widespread hemorrhage on serous membranes, enlargement of the spleen and lymph nodes, and edema and congestion of organs such as the lung may be present. Microscopic lesions can include microvascular thrombosis in any tissue, necrosis in liver, spleen, and lymph nodes, and focal granulomas in various organs (Mörner, 2001).

Many *Salmonella* serotypes have been isolated from a wide variety of mammals and other vertebrates. Animals can be carriers of the bacteria and not have the disease salmonellosis. There is no evidence that deer serve as a reservoir for *Salmonella* (Robinson, 1981).



With living animals, culture of fresh fecal material is the most commonly used diagnostic method (Ketz-Riley, 2003). At necropsy, culture of fresh mesenteric lymph nodes has been the most consistent tissue for diagnostic confirmation (Robinson, 1981). Transmission of *Salmonella* occurs fecal orally, primarily via ingestion of contaminated food and water or through direct contact with infected and shedding animals (e.g., Ketz-Riley, 2003). The bacteria can be persistent in the environment and outbreaks are sometimes associated with riparian areas and periodic flooding. Deer are not considered to disseminate *Salmonella* to livestock.

*Salmonella* infections can cause significant mortality, morbidity, and economic losses among domestic animals (Robinson, 1981). Control of *Salmonella* infection in the wild is not feasible. To the extent that environmental contamination with sewage sludge, manure, or effluent from slaughterhouses contribute to the occurrence of *Salmonella* in wildlife (Murray, 1991), improved sanitation is probably the best way to reduce occurrence among wild mammals (Mörner, 2001).

In humans, *Salmonella* infections usually result in temporary gastrointestinal infection caused by contaminated food or drink. Cases of human salmonellosis have not been attributed to infected deer, but there is no reason to doubt that infections could be acquired from clinically affected deer (Robinson, 1981). Persons handling living or dead deer should practice common-sense sanitation.

## Lyme Disease

Lyme disease is a zoonotic, tick-borne disease caused by the spirochetal bacterium, *Borrelia burgdorferi* (Brown and Burgess, 2001). *B. burgdorferi* bacteria are Gram-negative and 10–30  $\mu\text{m}$  long (Shapiro and Gerber, 2000). White-tailed deer and other wildlife species typically do not exhibit clinical signs or lesions when infected with *B. burgdorferi* (Brown and Burgess, 2001). However, many species of mammals, birds, and reptiles play a role in maintaining the wildlife-tick cycle (Davidson and Nettle, 1997). White-tailed deer are primary hosts of adult black-legged deer ticks (*Ixodes scapularis*), but are not important reservoirs for the disease (Lane et al., 1991; Brown and Burgess, 2001). The role that white-tailed deer appear to play is maintaining and transporting infected ticks (Lane et al., 1991).

Lyme disease diagnosis in wildlife is problematic because the disease has little impact on reservoir species (Brown and Burgess, 2001). Clinical signs mimic other diseases and should not be used solely to diagnose infection with *B. burgdorferi* (Brown and Burgess, 2001). Various serologic tests (e.g., IFA, ELISA, and Western blots) have been used for detecting *B. burgdorferi* in wildlife, humans, and domestic animals (Brown and Burgess, 2001).

In eastern and midwestern United States, black-legged deer ticks are the vectors that transmit *B. burgdorferi* (Shapiro and Gerber, 2000). In western United States, western black-legged deer ticks (*I. pacificus*) transmit the disease (Shapiro and Gerber, 2000). The most likely tick stage during which transmission of Lyme disease occurs is the nymph stage (Shapiro and Gerber, 2000). It seems logical that if hosts of deer-ticks were removed from an area, then deer-tick numbers and potential for Lyme disease transmission would be reduced. Studies investigating this disease management approach on islands or other geographically isolated areas provide evidence that reducing deer densities does reduce numbers of host-seeking *I. scapularis* (Telford et al., 1988; Wilson et al., 1990; Jordan et al., 2007). Others have reported that reducing deer densities had no effect on nymph tick abundance and that deer densities would have to be reduced to very low numbers to impact disease transmission risk (Jordan et al., 2007). Scientists with the USDA, Agricultural Research Services have developed a passive topical treatment device to apply acaricide for controlling ticks feeding on white-tailed deer, called the “4-Poster” (Figure 7.5) (Pound et al., 2000). Throughout the northeastern United States, the “4-Poster” device has reduced the number of Ixodidae ticks infecting deer, and has been suggested as a tool to help control Lyme disease (Figure 7.6) (Carroll and Kramer, 2003; Carroll et al., 2009; Gatewood Hoen et al., 2009; Miller et al., 2009; Schulze et al., 2009).

For humans, Lyme disease is the most common vector-borne illness in the United States (Shapiro and Gerber, 2000). Typical early symptoms include fever, headache, fatigue, and a characteristic skin rash. Later phases of the disease may mimic other conditions, including rheumatoid arthritis, Bell’s palsy, and neurologic impairment (Brown and Burgess, 2001).



**FIGURE 7.5** White-tailed deer feeding from a passive topical treatment device that applies acaricide for controlling ticks called a “4-Poster.” (Photo by U.S. Department of Agriculture’s Agricultural Research Service.)



**FIGURE 7.6** Biologists examining acaricide-impregnated rollers for signs of wear at a heavily used “4-Poster” in the northeastern United States. (Photo by U.S. Department of Agriculture’s Agricultural Research Service.)

---

## Rickettsial Diseases

### Anaplasmosis

Anaplasmosis is a vector-borne, infectious, noncontagious disease caused by rickettsia belonging to the family Anaplasmataceae, genus *Anaplasma* (Kuttler, 1981; Davidson and Goff, 2001). Bacteria that cause the disease are Gram-negative and nonacid-fast (Davidson and Goff, 2001). Anaplasmosis causes

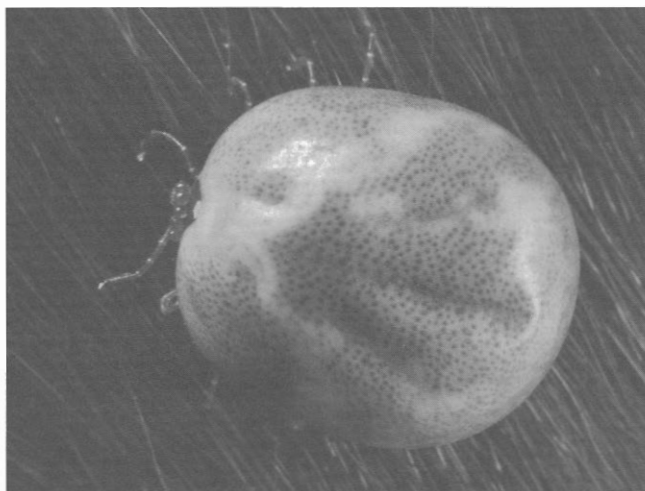destruction of red blood cells and is a worldwide disease of cattle, sheep, goats, and wild ruminants (Davidson and Goff, 2001). The *Anaplasma* genus was recently expanded to include three species that infect ruminants: *Anaplasma marginale* (cattle and deer), *Anaplasma ovis* (sheep, deer, and goats), and *Anaplasma centrale* (a less pathogenic organism) (Kocan et al., 2003).

Anaplasmosis is characterized by anemia as erythrocytes are parasitized and destroyed (Howe, 1981). As more red blood cells become infected, animals may develop rapid breathing, weakness (Kuttler, 1981), depression, inappetence, pale mucous membranes, rapid pulse, dehydration, thirst, and constipation (Howe, 1981). Most members of the deer family do not show clinical signs of anaplasmosis, even though they are susceptible to infection (Howe, 1981; Davidson and Nettles, 1997). Lesions are consistent with animals suffering from anemia and include thin watery blood, pale mucous membranes, enlargement of the spleen, liver, and gallbladder, generalized lymphadenopathy, and petechial hemorrhages in the endocardium (Howe, 1981; Kuttler, 1981).

In North American ruminants, where suitable vectors exist, anaplasmosis has been documented in wild white-tailed deer, mule deer, black-tailed deer, elk, bighorn sheep, and pronghorn antelope. Until recently, experimentally infecting nonruminant species with *Anaplasma* organisms was unsuccessful. The human anaplasmosis variant, *A. phagocytophilum* is now recognized to infect some rodent and shrew species, suggesting that these small mammals may also be important reservoirs of the disease (Woldehiwet, 2006).

Methods for diagnosis of anaplasmosis differ among animals with acute disease symptoms and symptoms from chronic or latent infections (Davidson and Goff, 2001). Animals with acute disease symptoms can be confirmed by microscopic examination of stained blood films, accompanied by serologic or molecular investigations (Davidson and Goff, 2001). Serologic demonstration of antibodies, with confirmation by animal subinoculation or molecular methods, is typically used for diagnosing anaplasmosis in wild ruminants with chronic or latent infections (Davidson and Goff, 2001). Molecular diagnostic procedures are used to detect anaplasmosis DNA in ticks and vertebrae hosts (Eriks et al., 1989; Kieser et al., 1990).

Ticks are the natural biologic vector capable of transmitting anaplasmosis; biting insects are capable of mechanically transmitting the disease, though less efficiently (Davidson and Goff, 2001). Numerous species of ticks (including members of the genera *Boophilus*, *Hyalomma*, *Amblyomma*, *Rhipicephalus*, *Dermacentor*, *Ixodes*, *Argas*, and *Haemophysalis*) have been shown to transmit anaplasmosis (Figure 7.7) (Kuttler, 1981). Transmission of the disease through biting insects must occur quickly in order for the infectious agent to remain viable on insect mouth parts (Davidson and Goff, 2001). Whether the disease becomes established in wild or domestic populations depends on the presence of suitable vectors in



**FIGURE 7.7** Dorsal view of an engorged female lone star tick. (*Amblyomma americanum*; photo by U.S. Centers for Disease Control and Prevention.)



the area. Infected blood on surgical instruments and hypodermic needles can also transmit the disease (Kuttler, 1981).

Management of anaplasmosis can be controversial in areas where wildlife species known to carry the disease overlap with domestic livestock range. Cattle can be extremely susceptible to anaplasmosis, with mortality exceeding 50% (Kuttler, 1981). Wild ruminants, primarily black-tailed and mule deer, are considered asymptomatic carriers in western North America (Kuttler, 1981). Management of the disease in free-ranging wild ruminants is often logistically impossible. Furthermore, removing wild ruminants that are known carriers is seldom a consideration because they rarely display clinical signs of infection (Howe, 1981).

The three *Anaplasma* species that infect ruminants, *A. marginale*, *A. ovis*, and *A. centrale* do not affect humans (Davidson and Goff, 2001). Human anaplasmosis, caused by the bacteria *A. phagocytophilum*, can be transmitted to humans by the bite of deer ticks and western black-legged ticks.

---

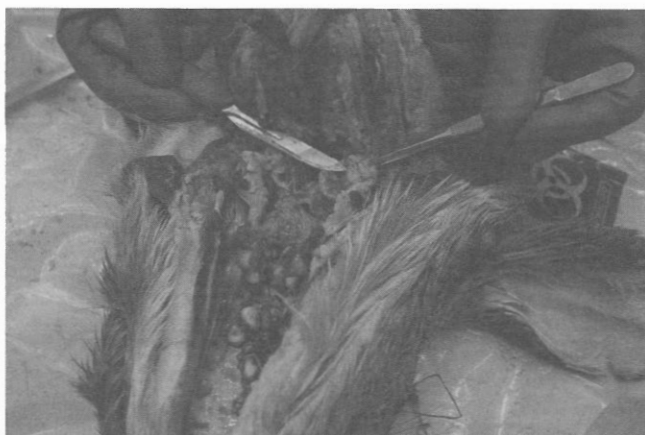## Chronic Wasting Disease

Chronic wasting disease is a transmissible spongiform encephalopathy (TSE), a group of neurological diseases that include bovine spongiform encephalopathy, sheep scrapie, transmissible mink encephalopathy, and Creutzfeldt–Jakob disease in humans. The causative agents of TSEs are thought to be proteinaceous infectious agents called prions. Prions are abnormal, protease-resistant forms of cellular proteins coded for and normally synthesized in the central nervous system and lymphoid tissues (Williams and Miller, 2002). The accumulation of prion leads to neurodegeneration and ultimately death (Sigurdson, 2008).

Clinical signs of CWD are unspecific and subtle in early disease and become detectable a year to just days prior to death, with most infected animals surviving three to four months following the onset of clinical disease (Williams et al., 2001). The primary clinical signs of animals with CWD include weight loss that progresses to emaciation; excessive salivation; abnormal behavior, including loss of fear of human beings; and mild ataxia (Spraker, 2003). Animals often carry their head and ears low and may walk in repetitive patterns, appear depressed, and rouse easily. As the disease progresses, many affected animals display polydipsia and polyuria, increased salivation with resultant drooling, as well as lack of coordination, posterior ataxia, fine-head tremors, and a wide-based stance. Esophageal dilation, hyperexcitability, and syncope are occasionally observed. Death is inevitable (Williams and Miller, 2002).

Primary gross lesions in advanced cases of CWD include weight loss, emaciation, and loss of abdominal and subcutaneous adipose tissue. Adipose tissue behind the eye, around the spinal cord, within the bone marrow and joints, within the renal pelvis, and around the coronary vessels undergoes serous atrophy. Adrenal gland enlargement may be noted. Aspiration pneumonia is common (Spraker, 2003). Carcasses may be in poor nutritional state or emaciated, but may be in fair condition if the animal died of aspiration pneumonia or after only a short clinical course. Primary histological lesions are limited to the nervous system and are typical of spongiform encephalopathies. The lesions are characterized by a spongiform degeneration of the neuropil, vacuolar degeneration of neurons with neuronal loss, and mild astrocytosis. Lymphoid depletion of the tonsils, lymph nodes, and spleen may occur in terminal stages (Figure 7.8). Histopathological examination can be used to confirm secondary gross lesions, such as bronchiopneumonia, gastric ulceration and peritonitis, hypertrophy of the adrenal cortex, and serous atrophy of fat (Spraker, 2003).

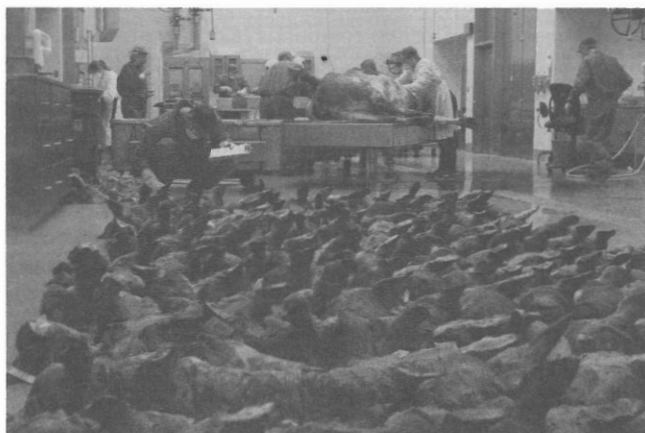Naturally occurring cases of CWD have been documented in white-tailed deer, mule deer, elk, and moose. Concern exists regarding potential transmission or adaptation to other species of wildlife and domestic livestock. Clinical diagnosis of CWD relies on the appearance of the aforementioned symptoms. Confirmatory diagnosis is by identification of abnormal prion protein in lymphoid and brain tissues by immunohistochemistry and by the appearance of spongiform changes on histopathological examination of brain tissues. Monoclonal antibodies specific for the prion protein are effective on fresh and formalin-fixed tissues and allow the detection of CWD. Biopsies of tonsil and rectal mucosa are being evaluated and used in some cases for antemortem-CWD surveillance (Spraker et al., 2006; Wolfe et al., 2007).



**FIGURE 7.8** Inspection of white-tailed deer head for lymphoid depletion. (Photo by Michigan Department of Natural Resources and Environment. With permission.)

Although mechanisms are not completely understood, transmission of CWD occurs directly through contact with infected individuals and indirectly through contact with environments and fomites that have been contaminated by excretions of infected individuals prior to death and by their carcasses following death (e.g., Miller et al., 2004; Mathiason et al., 2006; Haley et al., 2009). Prions remain infectious in soil for over two years, suggesting that soil may serve as a reservoir for CWD prions (Seidel et al., 2007). Although interspecies transmission likely occurs within the Cervidae, CWD has not been transmitted by oral inoculation to species outside this family.

The presence of CWD in captive and free-ranging populations of white-tailed deer and other cervids is a serious management problem. There is no known treatment for animals affected with CWD, and it is considered 100% fatal once clinical signs develop. Eradication from free-ranging deer is unlikely due to CWD's long incubation period, subtle early clinical signs, extremely resistant infectious agent, environmental contamination, and multiple modes of transmission (e.g., Williams and Miller, 2002; Spraker, 2003; Sigurdson, 2008). Active surveillance aids in determining the distribution and prevalence of CWD and can be used to elucidate changes over time (Figure 7.9). Localized population reduction, regulating translocation of deer, and banning baiting and feeding have all been attempted to slow down the spread of CWD.



**FIGURE 7.9** White-tailed deer heads waiting evaluation and testing during active surveillance activities for CWD. (Photo by Michigan Department of Natural Resources and Environment. With permission.)

No cases of human disease have been associated with CWD and there appears to be a robust species barrier. As CWD and other TSEs are incompletely understood, though, hunters harvesting deer in endemic areas should consider having carcasses tested, and, as with other diseases, it is not advisable to consume meat from infected deer. Additionally, common sense measures should be employed when handling and processing carcasses from endemic areas.

---

## Parasites

### Protozoa

#### Toxoplasmosis

*Toxoplasma gondii*, which has felids as definitive hosts and has many mammals as intermediate hosts, is the causative agent of toxoplasmosis (Dubey and Odening, 2001). This protozoa normally parasitizes hosts, including white-tailed deer (Lindsay et al., 1991), without causing clinical signs, although experimentally infected animals display diarrhea, weakness, and lethargy (Davidson, 2006). Lesions of toxoplasmosis in deer may include enlarged heart and lymph nodes, congestion of ocular vessels, abomasum, lungs, and spleen, and hemorrhages within the myocardium and internal abdominal wall (Davidson, 2006). Definitive diagnosis is conducted through histological, biological, and/or serological methods (Dubey and Odening, 2001). Transmission of *T. gondii* oocysts to deer occurs through the fecal (from felids)–oral route via environmental exposure (Davidson, 2006). Morbidity and mortality among deer due to toxoplasmosis are rare, however, seroprevalence rates are high (30–60%; Lindsay et al., 1991; Brillhart et al., 1994; Humphreys et al., 1995; Vanek et al., 1996). This highlights the importance of either freezing or thoroughly cooking venison because toxoplasmosis can negatively and severely impact human health if exposed.

#### Babesiosis

The causative agents of babesiosis are obligate intraerythrocytic protozoan parasites in the genus *Babesia* (Kocan and Waldrup, 2001). White-tailed deer are most commonly infected with *B. odocoilei*, which has been found in Texas, New Mexico, Oklahoma, Virginia, and Florida (Spindler et al., 1958; Emerson and Wright, 1968; Perry et al., 1985; Waldrup et al., 1989b), and is vectored by the deer tick (*I. scapularis*) (Waldrup et al., 1990). Numerous other ixodid ticks transmit *Babesia* spp., such as the southern cattle tick (*Rhipicephalus [Boophilus] microplus*) and the cattle tick (*Rhipicephalus [Boophilus] annulatus*), which are both one-host ticks (Kocan and Waldrup, 2001). Both of these tick species have been found on white-tailed deer (Cooksey et al., 1989; Cantu et al., 2007). Other species susceptible to *B. odocoilei* are elk, reindeer, caribou, desert bighorn sheep, and muskoxen (Schoelkopf et al., 2005). Clinical signs and mortality for free-ranging deer infected with *Babesia* spp. are rare; however, mortality is high for immunocompromised deer under experimental conditions (Kocan and Waldrup, 2001). Definitive diagnosis in species that are more susceptible to babesiosis than deer involves microscopically demonstrating the agent in whole blood (Kocan and Waldrup, 2001). *Babesia* spp. that infect white-tailed deer are not infectious to humans. However, given that bovine babesiosis (*B. bovis* and *B. bigemina*) has recently been demonstrated in white-tailed deer in northern Mexico (Cantu et al., 2007), there is great concern among livestock producers and government agencies about the role deer might play in the event these diseases were reintroduced into the United States (Figure 7.10).

#### Theileriosis

White-tailed deer may be infected with *Theileria cervi*, an intraerythrocytic protozoan parasite and the causative agent of theileriosis (Kreier et al., 1962). Clinical signs of *T. cervi* infecting free-ranging white-tailed deer are extremely rare and may include only mild-to-nonapparent anemia (Kocan and Waldrup, 2001). However, fever, anemia, emaciation, pale membranes, and overall debilitation has been observed in cases where *T. cervi* infection is concurrent with severe infestations of lone star ticks (*A. americanum*) in fawns (Barker et al., 1973; Kocan and Waldrup, 2001; Yabsley et al., 2005). In North America, *T. cervi*





**FIGURE 7.10** Inspection of wild-caught white-tailed deer for cattle fever ticks (*Rhipicephalus* [*Boophilus*] spp.) that carry bovine babesiosis within the southern Texas border region. (Photo by U.S. Department of Agriculture's Animal and Plant Health Inspection Service.)

has been found in white-tailed deer, mule deer, sika deer, fallow deer, and elk (Davidson et al., 1985; Waldrup et al., 1989a) in regions with lone star ticks, its only known vector. Diagnosis is based on identification of intraerythrocytic piroplasms (Kocan and Waldrup, 2001). *T. cervi* does not infect humans and poses a minimal threat to white-tailed deer populations.

## Trematodes

### Liver Fluke

*Fascioloides magna* is the scientific name for liver flukes, which are also known as giant liver flukes, large American liver flukes, or deer flukes (Pybus, 2001). In white-tailed deer and other definitive hosts clinical signs of disease are uncommon. Liver fibrosis may occur in severe *F. magna* infestations (Davidson, 2006). In aberrant hosts, depression, lethargy, anorexia, and weight loss are common just prior to death (Foreyt, 1992, 1996). Lesions associated with liver fluke infestation are fibrous capsules in liver tissues. These capsules commonly contain  $\geq 2$  adult flukes. In aberrant hosts, lesions may involve severe liver damage including hemorrhage, necrosis, inflammation, and diffuse fibrosis (Foreyt and Leathers, 1980). Definitive hosts of *F. magna* are white-tailed deer, elk, caribou, black-tailed deer, mule deer, red deer, and fallow deer (Pybus, 2001). Dead-end hosts of *F. magna* are moose, sika deer, sambar, cattle, bison, yak, horse, swine, collared peccary, and llama (Pybus, 2001). Aberrant hosts of *F. magna* are domestic sheep, domestic goat, chamois, bighorn sheep, mouflon, and roe deer. Diagnosis of liver flukes is through identification of reddish-brown trematodes ( $8 \times 3$  cm) encapsulated in the liver (Pybus, 2001). The life cycle of *F. magna* is complex and involves snail intermediate hosts and deer definitive hosts that obtain metacercariae through consumption of vegetation (Pybus, 2001). Care should be taken when translocating elk, red deer, white-tailed deer, and fallow deer from enzootic to nonenzootic areas (Pybus, 2001). Anthelmintic treatment should occur in these situations as well as at game farms and where sheep and deer congregate (Davidson, 2006). Eating venison from animals with liver flukes poses no threat to human health (Davidson, 2006).

## Nematodes

### Large Lungworm

The large lungworm found in white-tailed deer is *Dictyocaulus viviparus*. Deer infected with *D. viviparus* rarely display clinical signs (Davidson, 2006). However, deer that are severely infected are often

weak, underweight, and undergoing respiratory distress (Munro, 1988). Deer experiencing lungworm pneumonia are usually fawns, malnourished, and infected with high levels of other parasites (Bergstrom, 1975). As the name implies, lesions associated with large lungworm infection occur in the respiratory tract and may include excessive foamy mucous in air passages, bronchopneumonia, and lungs coated with fibrin (Anderson and Prestwood, 1981). *D. viviparus* have been found in numerous other wild and domestic ruminants, including mule deer, elk, moose, cattle, sheep, and goats (Anderson and Prestwood, 1981). Large lungworm infection can be diagnosed through identification of these up to 3.8 cm long white nematodes in the trachea and bronchi. Live animal tests are performed through microscopic examination of feces for larvae. The life cycle of *D. viviparus* is direct and deer obtain larvae while feeding on vegetation (Mason, 1985). Large lungworms present no human health risks. However, *D. viviparus* infections are a significant source of deer mortality on properties where deer densities exceed nutritional carrying capacity. As such, and particularly on properties where deer co-mingle with livestock, biologists should seek to maintain deer densities below carrying capacity (Davidson, 2006).

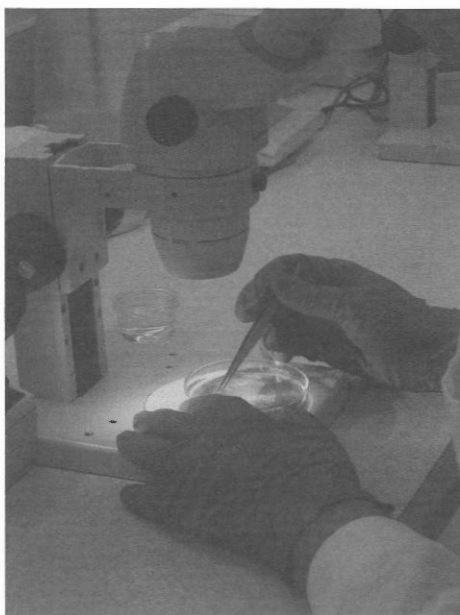### Large Stomach Worm

The scientific name for large stomach worm or barber pole worm is *Haemonchus contortus*. These gastrointestinal nematodes are characterized by a well-developed synlophes, prominent buccal tooth, and well-developed copulatory bursa in males (Hoberg et al., 2001). Most deer serve as hosts of the large stomach worm without demonstrating signs of disease (Davidson, 2006). In fact, prevalence rates approximate 100% in parts of the coastal plain of the southeastern United States (Prestwood and Pursglove, 1981). At high *H. contortus* intensities, haemonchosis may occur, which may result in death (Hoberg et al., 2001). Deer experiencing haemonchosis are usually fawns, weak, anemic, underweight, malnourished, and are often infected with many other parasites (Prestwood and Kellogg, 1971; Davidson et al., 1980; Forrester, 1992). Lesions associated with haemonchosis are accumulation of fluid in the submandibular region and pale mucous membranes and organs due to blood loss (Foreyt and Trainer, 1970; Prestwood and Purslove, 1981). *H. contortus* have been found in most wild and domestic ruminants occurring in North America (Davidson, 2006). Definitive diagnosis of haemonchosis using fecal analysis is challenging because eggs of *Haemonchus* are indistinguishable from other trichostrongylids (Sommer, 1996). However, the presence of large numbers of *H. contortus* in young animals that are weak and emaciated is presumptive evidence (Figure 7.11). Also, molecular markers have been used to partition trichostrongylids into species (Zarlenga et al., 1994; Lichtenfels et al., 1997). The life cycle of *H. contortus* is direct and deer obtain larvae while feeding on vegetation (Davidson, 2006).

Large stomach worms pose no human health risk. The occurrence of haemonchosis in white-tailed deer herds is indicative of populations that exceed nutritional carrying capacity (Davidson, 2006). Similar to other severe nematode infections, biologists should seek to maintain deer densities below carrying capacity to promote healthy herds of deer and other co-occurring ruminants (Davidson, 2006).

### Meningeal Worm

The long-lived meningeal worm (*Parelaphostrongylus tenuis*) is common across the range of white-tailed deer, with the possible exception of the coastal plain region of the southeastern United States (Comer et al., 1991; Duffy et al., 2002). For example, recent reports have demonstrated *P. tenuis* within cervids in Saskatchewan, Manitoba, North Dakota (Wasel et al., 2003), Kentucky (Larkin et al., 2003), Michigan (Bender et al., 2005), and South Dakota (Jacques and Jenks, 2004). White-tailed deer infected with meningeal worms only rarely display clinical signs of disease (Lankester, 2001). In cases of massive infestations, white-tailed deer may show neurological signs, including partial paralysis, loss of motor function, or circling (Prestwood, 1970). *P. tenuis* infections within other native cervids cause devastating morbidity and mortality (Lankester, 2001). Lesions in white-tailed deer with clinical disease are inflammation of the cranial meninges, small (~1 mm) red spots scattered widely across the surface of lungs, and occasionally mild pneumonia (Lankester, 2001; Davidson, 2006). Definitive hosts for meningeal worms are white-tailed deer. Clinical disease is near certain when *P. tenuis* enters other native cervids, some exotic ungulates, and domestic sheep (Lankester, 2001; Davidson, 2006). To diagnose meningeal worm



**FIGURE 7.11** Personnel collecting large stomach worms (*Haemonchus contortus*) from a diluted sample of white-tailed deer fawn abomasal contents. (Photo by U.S. Department of Agriculture's Animal and Plant Health Inspection Service.)

infestation, adult worms must be identified from the central nervous system, which requires animals to be euthanized (Carreno and Lankester, 1993; Davidson, 2006). Efforts are being made to develop molecular diagnostic tools (Gajadhar et al., 2000). The life cycle of *P. tenuis* is complex and involves terrestrial mollusks as intermediate hosts and deer as definitive hosts that obtain infective third-stage larvae through inadvertent consumption of mollusks (Lankester, 2001). Meningeal worms present no human health risks. However, *P. tenuis* is a significant threat to all native cervids in North America other than white-tailed deer (Samuel et al., 1992; Lankester, 2001). Natural resource managers and biologists undertaking cervid translocation activities should consider and take preventative measures to prevent meningeal worm introductions into susceptible herds (Davidson, 2006).

### Arterial Worm

As their common name implies, arterial worms (*Elaeophora schneideri*) reside in the arteries of cervids, including white-tailed deer (Pence, 1991). Arterial worms may cause elaeophorosis, within their hosts. The clinical signs of elaeophorosis in white-tailed deer are oral food compaction and associated facial swelling (Couvillion et al., 1986). White-tailed deer with only a few worms often present no gross lesions. However, with clinical disease, lesions may include coronary obstruction, plaque-like lesions on internal lining of carotids, and thickening of vessel walls (Anderson, 2001). Death may also occur (Titche et al., 1979). Natural hosts for *E. schneideri* are mule deer (Hibler et al., 1969), black-tailed deer (Weinmann et al., 1973), white-tailed deer (Prestwood and Ridgeway, 1972), elk (Hibler and Adcock, 1971), moose (Madden et al., 1991), domestic barbary sheep (Pence and Grey, 1981), and sika deer (Robinson et al., 1978), primarily in western North America (Anderson, 2001).

When white-tailed deer are seen with food compaction, elaeophorosis should be strongly suspected (Davidson, 2006). Confirmation of elaeophorosis is through identification of *E. schneideri* within arteries (Davidson, 2006) or through skin biopsy (Hibler and Adcock, 1971). Arterial worms pose no threat to human health. The life cycles of *E. schneideri* are indirect and require horseflies of the genera *Hybomitra* and *Tabanus* as intermediate hosts and for transmission to definitive hosts (Anderson, 2001). Population-level impacts of elaeophorosis in white-tailed deer have not been documented. However, because elaeophorosis is more often observed in older animals, management aimed at increasing the herd age-structure may also increase the occurrence of disease (Davidson, 2006).



### Abdominal Worm

*Setaria yehi* is a large filarial worm, also known as the abdominal worm, often occurring in the abdominal and thoracic cavities of white-tailed deer (Forrester, 1992). The abdominal worm does not cause clinical disease in its hosts, which include most native cervids from North America and sambar deer (Davidson et al., 1987; Davidson, 2006). However, hunters may discover live or postmortem adult worms encysted on the surface of organs while eviscerating deer. Furthermore, infected deer often have mild fibrinous peritonitis (Prestwood and Pursglove, 1977). The life cycle of *S. yehi* is indirect and it uses mosquitoes as intermediate hosts and biological vectors for transmission back to deer (Forrester, 1992). Abdominal worms pose no human, wildlife, or livestock health risks. However, hunters who notice *S. yehi* may communicate concerns or questions to biologists and managers (Davidson, 2006).

### Cestodes

#### Larval Tapeworm

White-tailed deer serve as intermediate hosts for several tapeworms, the most common being *Taenia hydatigena*. In white-tailed deer and other intermediate hosts, no clinical signs are reported (Jones and Pybus, 2001). Lesions in white-tailed deer are rare and include bladder-like larvae on or in visceral organs, such as liver tissue (Davidson, 2006). Given the global distribution of *T. hydatigena*, the dominant definitive and intermediate hosts vary by region (Jones and Pybus, 2001). Recent reports document larval *T. hydatigena* in white-tailed deer in Ontario (Addison et al., 1988), Alberta (Pybus, 1990), Ohio (Schurr et al., 1988), and Florida (Forrester and Rausch, 1990). In white-tailed deer, diagnosis is through identification of *T. hydatigena* larvae in tissues. The life cycle of *T. hydatigena* is indirect and involves herbivores as intermediate hosts and carnivores as definitive hosts (Jones and Pybus, 2001). Larval tapeworms present no human, wildlife, or livestock health risks. As with the abdominal worm, hunters who find larval tapeworms in tissues may communicate concerns or questions to biologists and managers (Davidson, 2006).

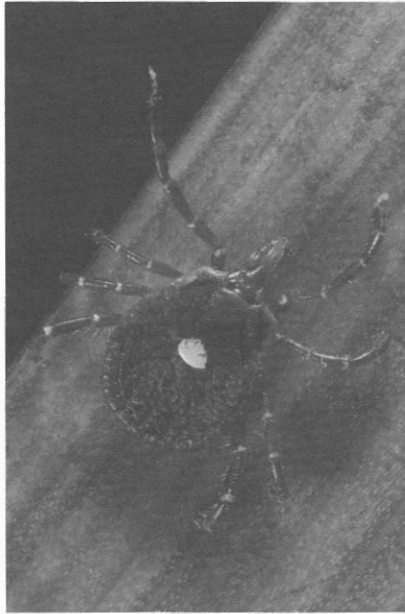
### Arthropods

#### Ticks

Without question, ticks are the most significant ectoparasite of wild mammals, including white-tailed deer, because of their ability to harbor and transmit pathogens (Strickland et al., 1981; Forrester, 1992). The most common ticks that infect white-tailed deer are hard ticks of the genera *Amblyomma* (Figure 7.12), *Ixodes* (Figure 7.13), and *Dermacentor* (Davidson, 2006). Ticks of the genera *Boophilus* were once abundant across the range of white-tailed deer; however, with the exception of a small eradication zone in southern Texas, they are now eradicated from the United States (Allan, 2001b). Most deer with ticks show no signs of disease and often those that do are malnourished and have high internal parasite loads (Davidson, 2006). Massive tick infestations may result in local irritation at the site of feeding, blood loss, secondary infections, and mortality (Allan, 2001b). Fawns with heavy infestations may experience blindness and death (Davidson, 2006). Ticks commonly found on white-tailed deer also infect livestock and other wildlife. Diagnosis is through identification of ticks on the skin (Allan, 2001b). Ticks of the genera *Amblyomma*, *Ixodes*, and *Dermacentor* are all three-host ticks, requiring a blood meal from a different host to complete each life stage (i.e., larva, nymph, adult; Allan, 2001b). Several species of ticks that infect white-tailed deer will coinfect humans and may function as vectors of diseases (Davidson, 2006).

#### Ear Mites

White-tailed deer may be infected with ear mites (*Psoroptes cuniculi*). Clinical signs of ear mite infestation are circling, incoordination, scratching or shaking of the head, and secondary bacterial infections inside the ear (Scott et al., 2000). Lesions associated with severe ear mite infections include thick, firm debris in the external ear canal (Scott et al., 2000). In addition to white-tailed deer, ear mites have been



**FIGURE 7.12** Dorsal view of an adult female lone star tick (*Amblyomma americanum*). (Photo by U.S. Centers for Disease Control and Prevention.)

found in mule deer, domestic rabbits, and goats (Davidson, 2006). Infestations by ear mites are diagnosed through acquisition and identification of *P. cuniculi* from ears (Davidson, 2006). Ear mites mature from eggs, to larvae, to adults on white-tailed deer, with transmission from deer-to-deer via direct contact (Scott et al., 2000). Ear mites pose no human health risks and are not considered overtly pathogenic to white-tailed deer unless heavily infested (Davidson, 2006).



**FIGURE 7.13** Dorsal view of an adult female western black-legged tick (*Ixodes pacificus*). (Photo by U.S. Centers for Disease Control and Prevention.)

### Demodectic Mange

White-tailed deer have been reported with demodectic mange or demodicidosis, which is caused by the mange mite *Demodex odocoilei*, in Oklahoma, Georgia, Virginia, South Dakota, and Texas (Kellogg et al., 1971; Carpenter et al., 1972; Jacques et al., 2001; Turner and Cano, 2008). Clinical signs and lesions in infested white-tailed deer usually do not develop (Davidson, 2006). With severe infestations, hair loss with thickening of the skin and secondary bacterial infections may develop (Desch and Nutting, 1974). *Demodex* is taxonomically complex because of similarities within the genera (Turner and Cano, 2008). However, *D. odocoilei* have only been found on white-tailed deer (Davidson, 2006). An infestation with demodectic mange is diagnosed through acquisition and identification of *D. odocoilei* from pustular lesions on skin. (Scott et al., 2000). *D. odocoilei* mature from eggs, to larvae, to adults on white-tailed deer, with transmission from deer-to-deer via direct contact or contact with areas used by infected animals (Scott et al., 2000; Davidson, 2006). Demodectic mange presents no human health risks and is not considered a problem for managers of white-tailed deer (Davidson, 2006).

### Other Common Arthropods

Nasal bots (*Cephenemyia* spp.), louse flies (*Lipoptena* spp. and *Neolipoptena* spp.), and lice (sucking lice, *Solenopotes binipilosus*; chewing lice, *Tricholipeurus lipeuroides* and *T. parallelus*) are commonly found on white-tailed deer throughout their range (Colwell et al., 2008). Clinical signs and lesions for nasal bots, louse flies, and lice have not been reported (Allan, 2001a; Durden, 2001; Colwell, 2001). The above-mentioned ectoparasites only occur on white-tailed deer and other cervids (Davidson, 2006). Nasal bots, louse flies, and lice are diagnosed through recovery and identification of ectoparasites in the oral cavity (larvae), skin, and in the axillary and inguinal regions with little hair, respectively (Allan, 2001a; Colwell, 2001; Durden, 2001). Nasal bots, louse flies, and lice pose no threat to human health and safety (Davidson 2006).

---

### Conclusions

Several recommendations can be made related to white-tailed deer diseases and parasites. First, it would behoove white-tailed deer biologists and managers to become knowledgeable in the above-mentioned diseases and parasites. This, in part, is needed in distinguishing potentially harmful diseases to humans, other wildlife, and livestock from those which are benign. For example, hunters that encounter white-tailed deer displaying unusual behavior or who observe parasites on or in their harvested animal frequently have questions related to the safety of handling carcasses or consuming venison. Second, it would be wise for biologists and managers who handle large numbers of animals and carcasses to forge partnerships with disease diagnostic laboratories, such as the Southeastern Cooperative Wildlife Disease Study at the University of Georgia or other university, state, or federal wildlife health laboratories. Such collaborations will facilitate appropriate sample collection, storage, and transport, ensure rapid and accurate diagnoses, and enable reliable information exchange. Lastly, biologists and managers considering translocation of cervids should follow the guidelines of Corn and Nettles (2001) to minimize the threat of introducing high-risk ectoparasites and infectious diseases, which are often spread through contact. These guidelines include evaluating the health status of source populations, quarantines, physical examination and diagnostic testing, restrictions on translocation of animals from certain geographic areas or populations, and prophylactic treatment (Corn and Nettles, 2001).

### REFERENCES

- Addison, E. M. J., J. Hoeve, D. G. Joachim, and D. J. McLachlin. 1988. *Fascioloides magna* (Trematoda) and (Cestoda) from white-tailed deer. *Canadian Journal of Zoology* 66:1359–1364.
- Allan, S. A. 2001a. Biting flies (Class Insecta: Order Diptera). In *Parasitic Diseases of Wild Mammals* (2nd edition), eds. W. M. Samuel, M. J. Pybus, and A. A. Kocan, 18–45. Ames, IA: Iowa State Press.



- Allan, S. A. 2001b. Ticks (Class Arachnida: Order Acarina). In *Parasitic Diseases of Wild Mammals* (2nd edition), eds. W. M. Samuel, M. J. Pybus, and A. A. Kocan, 72–106. Ames, IA: Iowa State Press.
- Anderson, R. C. 2001. Filarioid nematodes. In *Parasitic Diseases of Wild Mammals* (2nd edition), ed. W. M. Samuel, M. J. Pybus, and A. A. Kocan, 342–356. Ames, IA: Iowa State Press.
- Anderson, R. C. and A. K. Prestwood. 1981. Lungworms. In *Diseases and Parasites of White-tailed Deer*, eds. W. R. Davidson, F. A. Hayes, V. F. Nettles, and F. E. Kellogg, 266–317. Tallahassee, FL: Tall Timbers Research Station.
- Barker, R. W., A. L. Hoch, R. G. Buckner, and J. A. Hair. 1973. Hematological changes in white-tailed deer fawns, *Odocoileus virginianus*, infested with *Theileria* infected lone star ticks. *Journal of Parasitology* 59:1091–1098.
- Baumann, C. D., W. R. Davidson, D. E. Roscoe, and K. Beheler-Amass. 2001. Intracranial abscessation in white-tailed deer of North America. *Journal of Wildlife Diseases* 37:661–670.
- Bender, L. C., S. M. Schmitt, E. Carlson, J. B. Haufler, and D. E. Beyer, Jr. 2005. Mortality of Rocky Mountain elk in Michigan due to meningeal worm. *Journal of Wildlife Diseases* 41:134–140.
- Bergstrom, R. C. 1975. Prevalence of *Dictyocaulus viviparus* infection in Rocky Mountain elk in Teton County, Wyoming. *Journal of Wildlife Diseases* 11:40–44.
- Bolin, C. A. 2003. Leptospirosis. In *Zoo and Wild Animal Medicine* (5th edition), eds. M. E. Fowler and R. E. Miller, 699–702. St. Louis, MO: Elsevier Science.
- Brillhart, D. B., L. B. Fox, J. P. Dubey, and S. J. Upton. 1994. Seroprevalence of *Toxoplasma gondii* in wild mammals in Kansas. *Journal of the Helminthological Society of Washington* 61:117–121.
- Brown, R. N. and E. C. Burgess. 2001. Lyme Borreliosis. In *Infectious Diseases of Wild Mammals* (3rd edition), eds. E. S. Williams and I. K. Barker, 435–454. Ames, IA: Iowa State University Press.
- Buxton, D. and R. M. Barlow. 1994. Cardiovascular system: Anthrax. In *Management and Diseases of Deer* (2nd edition), eds. T. L. Alexander and D. Buxton, 151–152. London: The Veterinary Deer Society.
- Cantu, A., J. A. Ortega-S., J. Mosqueda, Z. Garcia-Vazquez, S. E. Henke, and J. E. George. 2007. Immunologic and molecular identification of *Babesia bovis* and *Babesia bigemina* in free-ranging white-tailed deer in northern Mexico. *Journal of Wildlife Diseases* 43:504–507.
- Cantu, A., J. A. Ortega-S., J. Mosqueda, Z. Garcia-Vazquez, S. E. Henke, and J. E. George. 2008. Prevalence of infectious agents in free-ranging white-tailed deer in northeastern Mexico. *Journal of Wildlife Diseases* 44:1002–1007.
- Carpenter, J. W., J. C. Freeny, and C. S. Patton. 1972. Occurrence of *Demodex* Owen 1843 on a white-tailed deer from Oklahoma. *Journal of Wildlife Diseases* 8:112–114.
- Carreno, R. A. and M. W. Lankester. 1993. Additional information on the morphology of the Elaphostrongylinae (Nematoda: Protostrongylidae) of North American Cervidae. *Canadian Journal of Zoology* 71:592–600.
- Carroll, J. F. and M. Kramer. 2003. Winter activity of *Ixodes scapularis* (Acari: Ixodidae) and the operation of deer-targeted tick control devices in Maryland. *Journal of Medical Entomology* 40:238–244.
- Carroll, J. F., J. M. Pound, J. A. Miller, and M. Kramer. 2009. Sustained control of Gibson Island, Maryland, populations of *Ixodes scapularis* and *Amblyomma americanum* (Acari: Ixodidae) by community-administered 4-Poster deer self-treatment bait stations. *Vector-Borne and Zoonotic Diseases* 9:417–421.
- Chase, C. C. L., L. J. Braun, P. Leslie-Steen, T. Graham, D. Miskimins, and J. F. Ridpath. 2008. Bovine viral diarrhea virus multiorgan infection in two white-tailed deer in southeastern South Dakota. *Journal of Wildlife Diseases* 44:753–759.
- Choquette, L. P. E. 1970. Anthrax. In *Infectious Diseases of Wild Mammals*, eds. J. W. Davis, L. H. Karstad, and D. O. Trainer, 256–266. Ames, IA: Iowa State University Press.
- Clark, R. C. and C. L. Gyles. 1993. Salmonella. In *Pathogenesis of Bacterial Infections in Animals* (2nd edition), eds. C. L. Gyles and C. O. Thoen, 133–153. Iowa, IA: Iowa State University Press.
- Clifton-Hadley, R. S., C. M. Sauter-Louis, I. W. Lugton, R. Jackson, P. A. Durr, and J. W. Wilesmith. 2001. *Mycobacterium bovis* infections. In *Infectious Diseases of Wild Mammals* (3rd edition), eds. E. S. Williams and I. K. Barker, 340–361. Ames, IA: Iowa State University Press.
- Colwell, D. D. 2001. Bot flies and warble flies (Order Diptera: Family Oestridae). In *Parasitic Diseases of Wild Mammals* (2nd edition), eds. W. M. Samuel, M. J. Pybus, and A. A. Kocan, 46–71. Ames, IA: Iowa State Press.
- Colwell, D. D., D. Gray, K. Morton, and M. Pybus. 2008. Nasal bots and lice from white-tailed deer in southern Alberta, Canada. *Journal of Wildlife Diseases* 44:687–692.

- Comer, J. A., W. R. Davidson, A. K. Prestwood, and V. F. Nettles. 1991. An update on the distribution of *Parelaphostrongylus tenuis* in the southeastern United States. *Journal of Wildlife Diseases* 27:348–354.
- Cooksey, L. M., R. B. Davey, E. H. Ahrens, and J. E. George. 1989. Suitability of white-tailed deer as hosts for cattle fever ticks (Acari: Ixodidae). *Journal of Medical Entomology* 26:155–158.
- Cormack Gates, C., B. Elkin, and D. Dragon. 2001. Anthrax. In *Infectious Diseases of Wild Mammals* (3rd edition), eds. E. S. Williams, and I. K. Barker, 396–412. Ames, IA: Iowa State University Press.
- Corn, J. L. and V. F. Nettles. 2001. Health protocol for translocation of free-ranging elk. *Journal of Wildlife Diseases* 37:413–426.
- Couvillion, C. E., V. F. Nettles, C. A. Rawlings, and R. L. Joyner. 1986. Elaeophorosis in white-tailed deer: Pathology of the natural disease and its relation to oral food impactions. *Journal of Wildlife Diseases* 22:214–223.
- Davidson, W. R. 2006. *Field Manual of Wildlife Diseases in the Southeastern United States* (3rd edition). Athens, GA: Southeastern Cooperative Wildlife Disease Study.
- Davidson, W. R., J. L. Blue, L. B. Flynn, S. M. Shea, R. L. Marchinton, and J. A. Lewis. 1987. Parasites, diseases and health status of sympatric populations of sambar deer and white-tailed deer in Florida. *Journal of Wildlife Diseases* 23:267–272.
- Davidson, W. R., J. M. Crum, J. L. Blue, D. W. Sharp, and J. H. Phillips. 1985. Parasites, diseases and health status of sympatric populations of fallow deer and white-tailed deer in Kentucky. *Journal of Wildlife Diseases* 21:153–159.
- Davidson, W. R. and W. L. Goff. 2001. Anaplasmosis. In *Infectious Diseases of Wild Mammals* (3rd edition), eds. E. S. Williams and I. K. Barker, 455–462. Ames, IA: Iowa State University Press.
- Davidson, W. R., F. A. Hayes, V. F. Nettles, and F. E. Kellogg. 1981. *Diseases and Parasites of White-tailed Deer*. Tallahassee, FL: Tall Timbers Research Station.
- Davidson, W. R., M. B. McGhee, V. F. Nettles, and L. C. Chapell. 1980. Haemonchosis in white-tailed deer in the southeastern United States. *Journal of Wildlife Diseases* 16:499–508.
- Davidson, W. R. and V. F. Nettles. 1997. *Field Manual of Wildlife Diseases in the Southeastern United States* (2nd edition). Athens, GA: Southeastern Cooperative Wildlife Disease Study.
- Davidson, W. R., V. F. Nettles, L. E. Hayes, E. W. Howerth, and C. E. Couvillion. 1990. Epidemiologic features of an intracranial abscessation/suppurative meningoencephalitis complex in white-tailed deer. *Journal of Wildlife Diseases* 26:460–467.
- Debbie, J. G. 1965. Brain abscess in a white-tailed deer (*Odocoileus virginianus*). *Bulletin of the Wildlife Disease Association* 1:3–4.
- de la Rua-Domenech, R. 2006. Human *Mycobacterium bovis* infection in the United Kingdom: Incidence, risks, control measures and review of the zoonotic aspects of bovine tuberculosis. *Tuberculosis* 86:77–109.
- de Lisle, G. W., R. G. Bengis, S. M. Schmitt, and D. J. O'Brien. 2002. Tuberculosis in free-ranging wildlife: Detection, diagnosis and management. *Revue Scientifique Et Technique* 21:317–334.
- Desch, C. E. and W. B. Nutting. 1974. *Demodex odocoilei* from the white-tailed deer, *Odocoileus virginianus*. *Canadian Journal of Zoology* 52:785–789.
- de Vos, V. 2003. Anthrax. In *Zoo and Wild Animal Medicine* (5th edition), eds. M. E. Fowler and R. E. Miller, 696–699. St. Louis, MO: Elsevier Science.
- Dubey, J. P. and K. Odening. 2001. Toxoplasmosis and related infections. In *Parasitic Diseases of Wild Mammals* (2nd edition), eds. W. M. Samuel, M. J. Pybus, and A. A. Kocan, 478–519. Ames, IA: Iowa State Press.
- Duffy, M. S., T. A. Greaves, N. J. Keppie, and M. D. B. Burt. 2002. Meningeal worm is a long-lived parasitic nematode in white-tailed deer. *Journal of Wildlife Diseases* 38:448–452.
- Durden, L. A. 2001. Lice (Phthiraptera). In *Parasitic Diseases of Wild Mammals* (2nd edition), eds. W. M. Samuel, M. J. Pybus, and A. A. Kocan, 3–17. Ames, IA: Iowa State Press.
- Emerson, H. R. and W. T. Wright. 1968. Isolation of a *Babesia* in white-tailed deer. *Bulletin of the Wildlife Disease Association* 4:142–143.
- Eriks, I. S., G. H. Palmer, T. C. McGuire, D. R. Allred and A. F. Barbet. 1989. Detection and quantitation of *Anaplasma marginale* in carrier cattle by using a nucleic acid probe. *Journal of Clinical Microbiology* 27:279–284.
- Fischer, J. R., L. P. Hanson, J. R. Turk, M. A. Miller, W. H. Fales, and H. S. Gosser. 1995. An epizootic of hemorrhagic disease in white-tailed deer (*Odocoileus virginianus*) in Missouri: Necropsy findings and population impact. *Journal of Wildlife Diseases* 31:30–36.



- Fitzgerald S. D., J. B. Kaneene, K. L. Butler et al. 2000. Comparison of postmortem techniques for the detection of *Mycobacterium bovis* in white-tailed deer (*Odocoileus virginianus*). *Journal of Veterinary Diagnostic Investigation* 12:322–327.
- Flacke, G. L., M. J. Yabsley, B. A. Hanson, and D. E. Stallknecht. 2004. Hemorrhagic disease in Kansas: Enzootic stability meets epizootic disease. *Journal of Wildlife Diseases* 40:288–293.
- Foreyt, W. J. 1992. Experimental *Fascioloides magna* infections of mule deer (*Odocoileus hemionus hemionus*). *Journal of Wildlife Diseases* 28:183–187.
- Foreyt, W. J. 1996. Susceptibility of bighorn sheep (*Ovis canadensis*) to experimentally induced *Fascioloides magna* infections. *Journal of Wildlife Diseases* 32:556–559.
- Foreyt, W. J. and C. W. Leathers. 1980. Experimental infection of domestic goats with *Fascioloides magna*. *American Journal of Veterinary Research* 41:883–884.
- Foreyt, W. J. and D. O. Trainer. 1970. Seasonal parasitism changes in two populations of white-tailed deer in Wisconsin. *Journal of Wildlife Management* 44:758–764.
- Forrester, D. J. 1992. *Parasites and Diseases of Wild Mammals in Florida*. Gainesville, FL: University Press of Florida.
- Forrester, D. J. and R. L. Rausch. 1990. Cysticerci (Cestoda: Taeniidae) from white-tailed deer, *Odocoileus virginianus*, in southern Florida. *Journal of Parasitology* 76:583–585.
- Friend, M. 1967. Skin tumors in New York deer. *Bulletin of the Wildlife Disease Association* 3:102–104.
- Gajadhar, A., T. Steeves-Gurnsey, J. Kendall, M. Lankester, and M. Steen. 2000. Differentiation of dorsal-spined elaphostrongyline larvae by polymerase chain reaction amplification of ITS-2 rDNA. *Journal of Wildlife Diseases* 36:713–723.
- Gatewood Hoen, A., L. G. Rollend, M. A. Papero, J. F. Carroll, T. J. Daniels, T. N. Mather, T. L. Schulze, K. C. Stafford, III, and D. Fish. 2009. Effects of tick control by acaricide self-treatment of white-tailed deer on host-seeking tick infection prevalence and entomologic risk for *Ixodes scapularis*-borne pathogens. *Vector-Borne and Zoonotic Diseases* 9:431–438.
- Gaydos, J. K., J. M. Crum, W. R. Davidson, S. S. Cross, S. F. Owen, and D. E. Stallknecht. 2004. Epizootiology of an epizootic hemorrhagic disease outbreak in West Virginia. *Journal of Wildlife Diseases* 40:383–393.
- Gaydos, J. K., W. R. Davidson, F. Elvinger, E. W. Howerth, M. Murphy, and D. E. Stallknecht. 2002a. Cross-protection between epizootic hemorrhagic disease virus serotypes 1 and 2 in white-tailed deer. *Journal of Wildlife Diseases* 38:720–728.
- Gaydos, J. K., W. R. Davidson, F. Elvinger, D. G. Mead, E. W. Howerth, and D. E. Stallknecht. 2002b. Innate resistance to epizootic hemorrhagic disease in white-tailed deer. *Journal of Wildlife Diseases* 38:713–719.
- Gaydos, J. K., D. E. Stallknecht, D. Kavanaugh, R. J. Olson, and E. R. Fuchs. 2002c. Dynamics of maternal antibodies to hemorrhagic disease viruses (Reoviridae: Orbivirus) in white-tailed deer. *Journal of Wildlife Diseases* 38:253–257.
- Ghim, S. J., J. Newsome, J. Bell, J. P. Sundberg, R. Schlegel, and A. B. Jensen. 2000. Spontaneous regressing oral papillomas induce systemic antibodies that neutralize canine oral papillomavirus. *Experimental and Molecular Pathology* 68:147–151.
- Gibbs, E. P. J. and E. C. Greiner. 1989. Bluetongue and epizootic hemorrhagic disease. In *The Arboviruses: Epidemiology and Ecology* (Vol. 2), ed. T. P. Monath, 39–70. Boca Raton, FL: CRC Press.
- Goyal, S. M., L. D. Mech, and M. E. Nelson. 1992. Prevalence of antibody titers to *Leptospira* spp. in Minnesota white-tailed deer. *Journal of Wildlife Diseases* 28:445–448.
- Haley, N. J., D. M. Seelig, M. D. Zabel, and E. A. Hoover. 2009. Detection of CWD prions in urine and saliva of deer by transgenic mouse bioassay. *PLoS One* 4:e4848.
- Hayes, F. A., W. E. Greer, and S. B. Shotts. 1958. A progress report from the Southeastern Cooperative Deer Disease Study. *Transactions of the North American Wildlife Conference* 23:133–136.
- Hibler, C. P. and J. L. Adcock. 1971. Elaeophorosis. In *Parasitic Diseases of Wild Mammals*, eds. J. W. Davis and R. C. Anderson, 263–278. Ames, IA: Iowa State Press.
- Hibler, C. P., J. L. Adcock, R. W. Davis, and Y. Z. Adbelbaki. 1969. Elaeophorosis in deer and elk in the Gila National Forest, New Mexico. *Bulletin of the Wildlife Disease Association* 5:27–30.
- Hoberg, E. P., A. A. Kocan, and L. G. Rickard. 2001. Gastrointestinal strongyles in wild ruminants. In *Parasitic Diseases of Wild Mammals* (2nd edition), eds. W. M. Samuel, M. J. Pybus, and A. A. Kocan, 193–227. Ames, IA: Iowa State Press.
- Howe, D. L. 1981. Anaplasmosis. In *Infectious Diseases of Wild Mammals* (2nd edition), eds. J. W. Davis, L. H. Karstad, and D. O. Trainer, 407–414. Ames, IA: Iowa State University Press.



- Howerth, E. W., D. E. Stallknecht, and P. D. Kirkland. 2001. Bluetongue, epizootic hemorrhagic disease and other orbivirus-related diseases. In *Infectious Diseases of Wild Mammals* (3rd edition), eds. E. S. Williams and I. K. Barker, 77–97. Ames, IA: Iowa State University Press.
- Hugh-Jones, M. E. and V. de Vos. 2002. Anthrax and wildlife. *Revue Scientifique Et Technique* 21:358–383.
- Humphreys, J. G., R. L. Stewart, and J. P. Dubey. 1995. Prevalance of *Toxoplasma gondii* antibodies in sera of hunter-killed white-tailed deer in Pennsylvania. *American Journal of Veterinary Research* 56:172–173.
- Hunter, D. L. 1996. Tuberculosis in free-ranging, semi free-ranging and captive cervids. *Revue Scientifique Et Technique* 15:171–181.
- Hyslop, N. S. T. G. 1980. Dermatophilosis (Streptothricosis) in animals and man. *Comparative Immunology, Microbiology and Infectious Diseases* 2:389–404.
- Isaza, R. 2003. Tuberculosis in all taxa. In *Zoo and Wild Animal Medicine* (5th edition), eds. M. E. Fowler and R. E. Miller, 689–696. St. Louis, MO: Elsevier Science.
- Jacques, C. N. and J. A. Jenks. 2004. Distribution of meningeal worm (*Parelaphostrongylus tenuis*) in South Dakota. *Journal of Wildlife Diseases* 40:133–136.
- Jacques, C. N., J. A. Jenks, M. B. Hildreth, R. J. Schauer, and D. D. Johnson. 2001. Demodicosis in a white-tailed deer (*Odocoileus virginianus*) in South Dakota. *Prairie Naturalist* 33:221–226.
- Jenson, A. B., M. C. Jenson, L. Cowser, S. J. Ghim, and J. P. Sundberg. 1997. Multiplicity of uses of monoclonal antibodies that define papillomavirus linear immunodominant epitopes. *Immunologic Research* 16:115–119.
- Jones, A. and M. J. Pybus. 2001. Taeniasis and echinococcosis. In *Parasitic Diseases of Wild Mammals* (2nd edition), eds. W. M. Samuel, M. J. Pybus, and A. A. Kocan, 150–192. Ames, IA: Iowa State Press.
- Jordan, R. A., T. L. Schulze, and M. B. Jahn. 2007. Effects of reduced deer density on the abundance of *Ixodes scapularis* (Acari: Ixodidae) and Lyme disease incidence in a northern New Jersey endemic area. *Journal of Medical Entomology* 44:752–757.
- Karns, G. R., R. A. Lancia, C. S. de Perno, M. C. Conner, and M. K. Stoskopf. 2009. Intracranial abscessation as a natural mortality factor for adult male white-tailed deer (*Odocoileus virginianus*) in Kent County, Maryland, USA. *Journal of Wildlife Diseases* 45:196–200.
- Kellogg, F. E., T. P. Kistner, R. K. Strickland, and R. R. Gerrish. 1971. Arthropod parasites collected from white-tailed deer. *Journal of Medical Entomology* 8:495–498.
- Kellogg, F. E., A. K. Prestwood, and R. E. Noble. 1970. Anthrax epizootic in white-tailed deer. *Journal of Wildlife Diseases* 6:226–228.
- Ketz-Riley, C. J. 2003. Salmonellosis and shigellosis. In *Zoo and Wild Animal Medicine* (5th edition), eds. M. E. Fowler and R. E. Miller, 686–689. St. Louis, MO: Elsevier Science.
- Kieser, S. T., I. S. Eriks, and G. H. Palmer. 1990. Cyclic rickettsia during persistent *Anaplasma marginale* infection in cattle. *Infection and Immunity* 58:1117–1119.
- Kocan, K. M., J. de la Fuentes, A. A. Guglielmone, and R. D. Melendez. 2003. Antigens and alternatives for control of *Anaplasma marginale* infection in cattle. *Clinical Microbiology Reviews* 16:698–712.
- Kocan, A. A. and K. A. Waldrup. 2001. Piroplasms (*Theileria* spp., *Cytauxzoon* spp., and *Babesia* spp.). In *Parasitic Diseases of Wild Mammals* (2nd edition), eds. W. M. Samuel, M. J. Pybus, and A. A. Kocan, 524–536. Ames, IA: Iowa State Press.
- Koller, L. D. and C. Olson. 1972. Attempted transmission of warts from man, cattle, and horses and of deer fibroma to selected hosts. *Journal of Investigative Dermatology* 58:366–368.
- Kreier, J. P., M. Ristic, and A. M. Watrach. 1962. *Theileria* sp. in a deer in the United States. *American Journal of Veterinary Research* 23:657–662.
- Kuttler, K. L. 1981. Anaplasmosis. In *Diseases and Parasites of White-tailed Deer*, eds. W. R. Davidson, F. A. Hayes, V. F. Nettles, and F. E. Kellogg, 126–135. Tallahassee, FL: Tall Timbers Research Station.
- Lane, R. S., J. Piesman, and W. Burgdorfer. 1991. Lyme Borreliosis: Relation of its causative agent to its vectors and hosts in North America and Europe. *Annual Review of Entomology* 36:587–609.
- Lankester, M. W. 2001. Extrapulmonary lungworms of cervids. In *Parasitic Diseases of Wild Mammals* (2nd edition), eds. W. M. Samuel, M. J. Pybus, and A. A. Kocan, 228–278. Ames, IA: Iowa State Press.
- Larkin, J. L., K. J. Alexy, D. C. Bolin et al. 2003. Meningeal worm in a reintroduced elk population in Kentucky. *Journal of Wildlife Diseases* 39:588–592.
- Leighton, F. A. 2001. Dermatophilosis. In *Infectious Diseases of Wild Mammals* (3rd edition), eds. E. S. Williams and I. K. Barker, 489–491. Ames, IA: Iowa State University Press.

- Libke, K. G. and A. M. Walton. 1975. Presumptive paratuberculosis in a Virginia white-tailed deer. *Journal of Wildlife Diseases* 11:552–553.
- Lichtenfels, J. R., E. P. Hoberg, and D. S. Zarlenga. 1997. Systematics of gastrointestinal nematodes of domestic ruminants: Advances 1992–1995, and proposals for future research. *Veterinary Parasitology* 72:225–245.
- Lim, P. S., A. B. Jenson, L. Cowser et al. 1990. Distribution and specific identification of papillomavirus major capsid protein epitopes by immunocytochemistry and epitope scanning of synthetic peptides. *Journal of Infectious Diseases* 162:1263–1269.
- Lindsay, D. S., B. L. Blagburn, J. P. Dubey, and W. H. Mason. 1991. Prevalence and isolation of *Toxoplasma gondii* from white-tailed deer in Alabama. *Journal of Parasitology* 77:62–64.
- Mackintosh, C., J. C. Haigh, and F. Griffin. 2002. Bacterial diseases of farmed deer and bison. *Revue Scientifique Et Technique* 21:249–263.
- Madden, D. J., T. R. Spraker, and W. J. Adrian. 1991. *Elaeophora schneideri* in moose (*Alces alces*) from Colorado. *Journal of Wildlife Diseases* 27:340–341.
- Manning, E. J. B. 2001. *Mycobacterium avium* subspecies *Paratuberculosis*: A review of current knowledge. *Journal of Zoo and Wildlife Medicine* 32:293–304.
- Mason, P. C. 1985. Biology and control of the lungworm *Dictyocaulus viviparus* in farmed red deer in New Zealand. *Royal Society of New Zealand Bulletin* 22:119–121.
- Mathiason C. K., J. G. Powers, S. J. Dahmes et al. 2006. Infectious prions in the saliva and blood of deer with chronic wasting disease. *Science* 314:133–136.
- Matschke, G. H., K. A. Fagerstone, R. F. Harlow et al. 1984. Population influences. In *White-tailed Deer Ecology and Management*, ed. L. K. Halls, 169–188. Harrisburg, PA: Stackpole Books.
- Miller, D. L., Z. A. Radi, C. Baldwin, and D. Ingram. 2005. Fatal West Nile virus infection in a white-tailed deer (*Odocoileus virginianus*). *Journal of Wildlife Diseases* 41:246–249.
- Miller, M. W., E. S. Williams, N. T. Hobbs, and L. L. Wolfe. 2004. Environmental sources of prion transmission in mule deer. *Emerging Infectious Diseases* 10:1003–1006.
- Miller, N. J., W. A. Thomas, and T. N. Mather. 2009. Evaluating a deer-targeted Acaricide applicator for area-wide suppression of blacklegged ticks, *Ixodes scapularis* (Acari: Ixodidae), in Rhode Island. *Vector-Borne and Zoonotic Diseases* 9:401–406.
- Mörner, T. 2001. Salmonellosis. In *Infectious Diseases of Wild Mammals* (3rd edition), eds. E. S. Williams and I. K. Barker, 505–507. Ames, IA: Iowa State University Press.
- Munro, R. 1988. Pulmonary parasites: Pathology and control. In *Management and Health of Farmed Deer*, ed. H. W. Reid, 27–42. Norwell, MA: Kluwer Academic Publishers.
- Murphy, M. D., B. A. Hanson, E. W. Howerth, and D. E. Stallknecht. 2006. Molecular characterization of epizootic hemorrhagic disease virus serotype 1 associated with a 1999 epizootic in white-tailed deer in the eastern United States. *Journal of Wildlife Diseases* 42:616–624.
- Murray, C. J. 1991. Salmonellae in the environment. *Revue Scientifique Et Technique* 10:765–785.
- Nettles, V. F. and D. E. Stallknecht. 1992. History and progress in the study of hemorrhagic disease of deer. *Transactions of the North American Wildlife and Natural Resources Conference* 57:499–516.
- O'Brien, D. J., S. D. Fitzgerald, T. J. Lyon et al. 2001. Tuberculous lesions in free-ranging white-tailed deer in Michigan. *Journal of Wildlife Diseases* 37:608–613.
- O'Brien, D. J., S. M. Schmitt, J. S. Fierke et al. 2002. Epidemiology of *Mycobacterium bovis* in free-ranging white-tailed deer, Michigan, USA, 1995–2000. *Preventative Veterinary Medicine* 54:47–63.
- O'Brien D. J., S. M. Schmitt, S. D. Fitzgerald, D. E. Berry, G. J. Hickling. 2006. Managing the wildlife reservoir of *Mycobacterium bovis*: The Michigan, USA, experience. *Veterinary Microbiology* 112:313–323.
- Palmer, M. V., W. R. Waters, and D. L. Whipple. 2002. Aerosol exposure of white-tailed deer (*Odocoileus virginianus*) to *Mycobacterium bovis*. *Journal of Wildlife Diseases* 39:817–823.
- Palmer, M. V., W. R. Waters, and D. L. Whipple. 2004. Shared feed as a means of deer-to-deer transmission of *Mycobacterium bovis*. *Journal of Wildlife Diseases* 40:87–91.
- Palmer, M. V., D. L. Whipple, J. B. Payeur et al. 2000. Naturally occurring tuberculosis in white-tailed deer. *Journal of the American Veterinary Medical Association* 216:1921–1924.
- Palmer, M. V., D. L. Whipple, and W. R. Waters. 2001. Experimental deer-to-deer transmission of *Mycobacterium bovis*. *American Journal of Veterinary Research* 62:692–696.
- Passler, T., P. H. Walz, S. S. Ditchkoff et al. 2009. Cohabitation of pregnant white-tailed deer and cattle persistently infected with bovine viral diarrhea virus results in persistently infected fawns. *Veterinary Microbiology* 134:262–267.

- Passler, T., P. H. Walz, S. S. Ditchkoff, M. D. Givens, H. S. Maxwell, and K. V. Brock. 2007. Experimental persistent infection with bovine viral diarrhea virus in white-tailed deer. *Veterinary Microbiology* 122:350–356.
- Pence, D. B. 1991. Elaeophorosis in wild ruminants. *Bulletin of the Society for Vector Ecology* 16:149–160.
- Pence, D. B. and G. G. Gray. 1981. Elaeophorosis in Barbary sheep and mule deer from the Texas panhandle. *Journal of Wildlife Diseases* 17:49–56.
- Perry, B. D., D. K. Nickols, and E. S. Cullon. 1985. *Babesia odocoilei* Emerson and Wright, 1970, in white-tailed deer, *Odocoileus virginianus*, in Virginia. *Journal of Wildlife Diseases* 21:149–152.
- Pfister, H. 1987. Papillomaviruses: General description, taxonomy, and classification. In *The Papovaviridae* (volume 2), eds. N. P. Salzman and P. M. Howley, 1–38. New York, NY: Plenum Press.
- Pound, J. M., J. A. Miller, J. E. George, and C. A. Lemeilleur. 2000. The '4-Poster' passive topical treatment device to apply acaricide for controlling ticks (Acari: Ixodidae) feeding on white-tailed deer. *Journal of Medical Entomology* 37:588–594.
- Prestwood, A. K. 1970. Neurologic disease in a white-tailed deer massively infected with meningeal worm (*Pneumostrongylus tenuis*). *Journal of Wildlife Diseases* 6:84–86.
- Prestwood, A. K. and F. E. Kellogg. 1971. Naturally occurring haemonchosis in a white-tailed deer. *Journal of Wildlife Diseases* 7:133–134.
- Prestwood, A. K. and S. R. Pursglove. 1977. Prevalence and distribution of *Setaria yehi* in southeastern white-tailed deer. *Journal of the American Veterinary Medical Association* 171:933–935.
- Prestwood, A. K. and S. R. Pursglove. 1981. Gastrointestinal nematodes. In *Diseases and Parasites of White-tailed Deer*, eds. W. R. Davidson, F. A. Hayes, V. F. Nettles, and F. E. Kellogg, 318–349. Tallahassee, FL: Tall Timbers Research Station.
- Prestwood, A. K. and T. R. Ridgeway. 1972. Elaeophorosis in white-tailed deer of the southeastern USA: Case report and distribution. *Journal of Wildlife Diseases* 8:233–236.
- Pybus, M. J. 1990. Survey of hepatic and pulmonary helminths of wild cervids in Alberta, Canada. *Journal of Wildlife Diseases* 26:453–459.
- Pybus, M. J. 2001. Liver flukes. In *Parasitic Diseases of Wild Mammals* (2nd edition), eds. W. M. Samuel, M. J. Pybus, and A. A. Kocan, 121–149. Ames, IA: Iowa State Press.
- Reid, H. W. 1994. Leptospirosis. In *Management and Diseases of Deer* (2nd edition), eds. T. L. Alexander and D. Buxton, 143–144. London: The Veterinary Deer Society.
- Richard, J. L. 1981. Dermatophilosis. In *Infectious Diseases of Wild Mammals*, eds. J. W. Davis, L. H. Karstad, and D. O. Trainer, 339–346. Ames, IA: Iowa State University Press.
- Ridpath, J. F., C. S. Mark, C. C. L. Chase, A. C. Ridpath, and J. D. Neill. 2007. Febrile response and decrease in circulating lymphocytes following acute infection of white-tailed deer fawns with either a BVDV1 or a BVDV2 strain. *Journal of Wildlife Diseases* 43:653–659.
- Robinson, R. M. 1981. Salmonellosis. In *Diseases and Parasites of White-tailed Deer*, eds. W. R. Davidson, F. A. Hayes, V. F. Nettles, and F. E. Kellogg, 155–160. Tallahassee, FL: Tall Timbers Research Station.
- Robinson, R. M., L. P. Jones, T. J. Galvin, and G. M. Harwell. 1978. Elaeophorosis in sika deer in Texas. *Journal of Wildlife Diseases* 14:137–141.
- Roscoe, D. E., R. C. Lund, M. A. Gordon, and I. F. Salkin. 1975. Spontaneous dermatophilosis in twin white-tailed deer fawns. *Journal of Wildlife Diseases* 11:398–401.
- Rosen, R. N. 1981. Miscellaneous bacterial and mycotic diseases. In *Diseases and Parasites of White-tailed Deer*, eds. W. R. Davidson, F. A. Hayes, V. F. Nettles, and F. E. Kellogg, 175–192. Tallahassee, FL: Tall Timbers Research Station.
- Roth, E. E. 1970. Leptospirosis. In *Infectious Diseases of Wild Mammals*, eds. J. W. Davis, L. H. Karstad, and D. O. Trainer, 293–303. Ames, IA: Iowa State University Press.
- Roy, P. 1996. Orbiviruses and their replication. In *Fields Virology* (3rd edition), eds. B. N. Fields, D. M. Knipe, and P. M. Howley, 1709–1734. Philadelphia, PA: Lippincott-Raven.
- Salkin, I. F. and M. A. Gordon. 1981. Dermatophilosis. In *Diseases and Parasites of White-tailed Deer*, eds. W. R. Davidson, F. A. Hayes, V. F. Nettles, and F. E. Kellogg, 168–173. Tallahassee, FL: Tall Timbers Research Station.
- Salkin, I. F., M. A. Gordon, and W. B. Stone. 1983. Cutaneous granules associated with dermatophilosis in a white-tailed deer. *Journal of Wildlife Diseases* 19:361–363.
- Samuel, W. M., M. J. Pybus, and A. A. Kocan. 2001. *Parasitic Diseases of Wild Mammals* (2nd edition). Ames, IA: Iowa State Press.



- Samuel, W. M., M. J. Pybus, D. A. Welch, and C. J. Wilke. 1992. Elk as a potential host for meningeal worm: Implications for transmission. *Journal of Wildlife Management* 56:629–639.
- Schmitt, S. M., T. M. Cooley, S. D. Fitzgerald et al. 2007. An outbreak of eastern equine encephalitis virus in free-ranging white-tailed deer in Michigan. *Journal of Wildlife Diseases* 43:635–644.
- Schmitt, S. M., S. D. Fitzgerald, T. M. Cooley et al. 1997. Bovine tuberculosis in free-ranging white-tailed deer from Michigan. *Journal of Wildlife Diseases* 33:749–758.
- Schoelkopf, L., C. E. Hutchinson, K. G. Bendele et al. 2005. New ruminant hosts and wider geographic range identified for *Babesia odocoilei* (Emerson and Wright 1970). *Journal of Wildlife Diseases* 41:683–690.
- Schulze, T. L., R. A. Jordan, R. W. Hung, and C. J. Schulze. 2009. Effectiveness of the 4-Poster passive topical treatment device in the control of *Ixodes scapularis* and *Amblyomma americanum* (Acari: Ixodidae) in New Jersey. *Vector-Borne and Zoonotic Diseases* 9:389–400.
- Schurr, K., F. Rabalais, and W. Terwilliger. 1988. *Cysticercus tenuicollis*: A new state record for Ohio. *Ohio Journal of Science* 88:104–105.
- Scott, D. W., W. H. Miller, and C. E. Griffin. 2000. *Muller and Kirk's Small Animal Dermatology* (6th edition). Philadelphia, PA: Elsevier.
- Seidel, B., A. Thomzig, A. Buschmann et al. 2007. Scrapie agent (Strain 263K) can transmit disease via the oral route after persistence in soil over years. *PLoS One* 5:1–8.
- Seward, N. W., G. E. Phillips, J. F. Duquette, and K. C. VerCauteren. 2007. A frightening device for deterring deer from cattle feed. *Journal of Wildlife Management* 71:271–276.
- Shad, G., W. C. Wilson, J. O. Meacham, and J. F. Evermann. 1997. Bluetongue virus isolation detection: A safer reverse-transcriptase polymerase chain reaction for prediction of viremia in sheep. *Journal of Veterinary Diagnostic Investigation* 9:118–124.
- Shapiro, E.D. and M. A. Gerber. 2000. Lyme disease. *Clinical Infectious Diseases* 31:533–542.
- Shotts, E. B. 1981. Leptospirosis. In *Diseases and Parasites of White-tailed Deer*, eds. W. R. Davidson, F. A. Hayes, V. F. Nettles, and F. E. Kellogg, 138–147. Tallahassee, FL: Tall Timbers Research Station.
- Sigurdson, C. J. 2008. A prion disease of cervids: Chronic wasting disease. *Veterinary Research* 39:41. <http://www.vetres.org>
- Sleeman, J. M., E. J. B. Manning, J. H. Rohm et al. 2009. Johne's disease in a free-ranging white-tailed deer from Virginia and subsequent surveillance for *Mycobacterium avium* subspecies *paratuberculosis*. *Journal of Wildlife Diseases* 45:201–206.
- Sneath, P. H., N. S. Mair, and M. E. Sharpe. 1986. *Bergey's Manual of Systematic Bacteriology* (Vol. 2). Baltimore, MD: Williams & Wilkins.
- Soltys, M. A., C. E. Andress and A. L. Fletch. 1967. Johne's disease in a moose (*Alces alces*). *Bulletin of the Wildlife Disease Association* 3:183–184.
- Sommer, C. 1996. Digital image analysis and identification of eggs from bovine parasitic nematodes. *Journal of Helminthology* 70:143–151.
- Spindler, L. A., R. W. Allen, L. S. Diamond, and J. C. Lotz. 1958. *Babesia* in white-tailed deer. *Journal of Protozoology* 5:8.
- Spraker, T. R. 2003. Spongiform encephalopathy. In *Zoo and Wild Animal Medicine* (5th edition), eds. M. E. Fowler and R. E. Miller, 741–745. St. Louis, MO: Elsevier Science.
- Spraker, T. R., T. L. Gidlewski, A. Balachandran, K. C. VerCauteren, L. Creekmore, and R. D. Munger. 2006. Detection of PrPCWD in postmortem rectal lymphoid tissues in Rocky Mountain elk (*Cervus elaphus nelsoni*) infected with chronic wasting disease. *Journal of Veterinary Diagnostic Investigation* 18:553–557.
- Stabel, J. R. 1998. Johne's disease: A hidden threat. *Journal of Dairy Science* 81:283–288.
- Strickland, R. K., R. R. Gerrish, and J. S. Smith. 1981. Arthropods. In *Diseases and Parasites of White-tailed Deer*, eds. W. R. Davidson, F. A. Hayes, V. F. Nettles, and F. E. Kellogg, 363–389. Tallahassee, FL: Tall Timbers Research Station.
- Sundberg, J. P., S. J. Ghim, M. Van Ranst, and A. B. Jenson. 1997. Nonhuman papillomaviruses: Host range, pathology, epitope conservation, and new vaccine approaches. In *Spontaneous Animal Tumors: A Survey*, eds. L. Rossi, R. Richardson, and J. Harshbarger, 33–40. Milan: Press Point di Abbiategrasso.
- Sundberg, J. P., M. Van Ranst, R. D. Burk, and A. B. Janson. 1996. The nonhuman (animal) papillomaviruses: Host range, epitope conservation, and molecular diversity. In *Human Papillomavirus Infections in Dermatology and Venereology*, eds. G. Gross and G. von Krogh, 47–68. Boca Raton, FL: CRC Press.

- Sundberg, J. P., M. Van Ranst, and A. B. Jensen. 2001. Papillomavirus infections. In *Infectious Diseases of Wild Mammals* (3rd edition), eds. E. S. Williams and I. K. Barker, 223–231. Ames, IA: Iowa State University Press.
- Tate, C. M., E. W. Howerth, D. E. Stallknecht, A. B. Allison, J. R. Fischer, and D. G. Mead. 2005. Eastern equine encephalitis in free-ranging white-tailed deer (*Odocoileus virginianus*). *Journal of Wildlife Diseases* 41:241–245.
- Telford, S. R. III, T. N. Mather, S. I. Moore, M. L. Wilson, and A. Spielman. 1988. Incompetence of deer as reservoirs of the Lyme disease spirochete. *American Journal of Tropical Medicine and Hygiene* 39:105–109.
- Titche, A. R., A. K. Prestwood, and C. P. Hibler. 1979. Experimental infections of white-tailed deer with *Elaeophora schneideri*. *Journal of Wildlife Diseases* 15:273–280.
- Trainer, D. O., R. P. Hanson, E. P. Pope, and E. A. Carlbrey. 1963. The role of deer in the epizootiology of leptospirosis in Wisconsin. *American Journal of Veterinary Research* 24:159–167.
- Turner, J. C. and J. Cano. 2008. Demodectic mange in a white-tailed deer from Walker County, Texas. *Journal of Medical Entomology* 45:572–575.
- Vanek, J. A., J. P. Dubey, P. Thulliez, M. R. Riggs, and B. E. Stromberg. 1996. Prevalence of *Toxoplasma gondii* antibodies in hunter-killed white-tailed deer (*Odocoileus virginianus*) in four regions of Minnesota. *Journal of Parasitology* 82:41–44.
- Van Kruiningen, H. 2001. Lack of support for a common etiology in Johne's disease of animals and Crohn's disease in humans. *Inflammatory Bowel Diseases* 5:183–191.
- Van Ness, G. B. 1981. Anthrax. In *Diseases and Parasites of White-tailed Deer*, eds. W. R. Davidson, F. A. Hayes, V. F. Nettles, and F. E. Kellogg, 161–167. Tallahassee, FL: Tall Timbers Research Station.
- VerCauteren, K. C., T. C. Atwood, T. J. DeLiberto et al. 2008b. Sentinel-based surveillance of coyotes to detect bovine tuberculosis, Michigan. *Emerging Infectious Diseases* 14:1862–1869.
- VerCauteren, K. C., M. J. Lavelle, and S. E. Hygnstrom. 2006. Fences and deer-damage management: A review of designs and efficacy. *Wildlife Society Bulletin* 34:191–200.
- VerCauteren, K. C., M. J. Lavelle, and G. E. Phillips. 2008a. Livestock protection dogs for deterring deer from cattle and feed. *Journal of Wildlife Management* 72:1443–1448.
- Waldrup, K., A. E. Collisson, S. E. Bentsen, C. K. Winkler, and G. G. Wagner. 1989a. Prevalence of erythrocytic protozoa and serologic reactivity to selected pathogens in deer in Texas. *Preventive Veterinary Medicine* 7:49–58.
- Waldrup, K., A. A. Kocan, R. W. Barker, and G. G. Wagner. 1990. Transmission of *Babesia odocoilei* in white-tailed deer (*Odocoileus virginianus*) by *Ixodes scapularis* (Acari: Ixodidae). *Journal of Wildlife Diseases* 26:390–391.
- Waldrup, K., A. A. Kocan, T. Quereshi, D. S. Davis, D. Baggett, and G. G. Wagner. 1989b. Serologic prevalence and isolation of *Babesia odocoilei* among white-tailed deer (*Odocoileus virginianus*) in Texas and Oklahoma. *Journal of Wildlife Diseases* 25:194–201.
- Wasel, S. M., W. M. Samuel, and V. Crichton. 2003. Distribution and ecology of meningeal worm, *Parelaphostrongylus tenuis* (Nematoda), in northcentral North America. *Journal of Wildlife Diseases* 39:338–346.
- Watson, J. D. and J. W. Littlefield. 1960. Some properties of DNA from Shope papillomavirus. *Journal of Molecular Biology* 2:161–165.
- Weinmann, C. J., J. R. Anderson, W. M. Longhurst, and G. Connolly. 1973. Filarial worms of Columbian black-tailed deer in California. 1. Observations in the vertebrate host. *Journal of Wildlife Diseases* 9:213–220.
- Whitlock, S. C. 1939. The prevalence of disease and parasites of white-tailed deer. *Transactions of the North American Wildlife Conference* 4:244–249.
- Wilkins, M. J., P. C. Bartlett, B. Frawley, D. J. O'Brien, C. E. Miller, and M. L. Boulton. 2003. *Mycobacterium bovis* (bovine TB) exposure as a recreational risk for hunters: Results of a Michigan hunter survey, 2001. *The International Journal of Tuberculosis and Lung Disease* 7:1001–1009.
- Williams, E. S. 2001. Paratuberculosis and other mycobacterial diseases. In *Infectious Diseases of Wild Mammals* (3rd edition), eds. E. S. Williams and I. K. Barker, 361–371. Ames, IA: Iowa State University Press.
- Williams, E. S. and I. K. Barker. 2001. *Infectious Diseases of Wild Mammals* (3rd edition). Ames, IA: Iowa State Press.

- Williams, E. S., J. K. Kirkwood, and M. W. Miller. 2001. Transmissible spongiform encephalopathies. In *Infectious Diseases of Wild Mammals* (3rd edition), eds. E. S. Williams and I. K. Barker, 392–301. Ames, IA: Iowa State University Press.
- Williams, E. S. and M. W. Miller. 2002. Chronic wasting disease in deer and elk in North America. *Revue Scientifique Et Technique* 21:305–316.
- Williams, E. S., A. C. Pier, and R. W. Wilson. 1984. Dermatophilosis in a mule deer, *Odocoileus hemionus* (Rafinesque), from Wyoming. *Journal of Wildlife Diseases* 20:236–238.
- Wilson, M. L., A. M. Ducey, T. S. Litwin, T. A. Gavin, and A. Spielman. 1990. Microgeographic distribution of immature *Ixodes dammini* ticks correlated with that of deer. *Medical and Veterinary Entomology* 4:151–159.
- Woldehiwet, Z. 2006. *Anaplasma phagocytophilum* in ruminants in Europe. *Annals of the New York Academy of Sciences* 1078:446–460.
- Wolfe, L. L., T. R. Spraker, L. Gonzalez et al. 2007. PrPCWD in rectal lymphoid tissue of deer (*Odocoileus* spp.). *Journal of General Virology* 88:2078–2082.
- Yabsley, M. J., T. C. Quick, and S. E. Little. 2005. Theileriosis in a white-tailed deer (*Odocoileus virginianus*) fawn. *Journal of Wildlife Diseases* 41:806–809.
- Yuill, T. M. and C. Seymour. 2001. Arbovirus infections. In *Infectious Diseases of Wild Mammals* (3rd edition), eds. E. S. Williams and I. K. Barker, 98–118. Ames, IA: Iowa State University Press.
- Zarlenga, D. S., F. Stringfellow, M. Nobary, and J. R. Lichtenfels. 1994. Cloning and characterizations of ribosomal RNA genes from 3 species of *Haemonchus* (Nematoda: Trichostronglyoidea) and identification of PCR primers for rapid differentiation. *Experimental Parasitology* 78:28–36.