

University of Nebraska - Lincoln

DigitalCommons@University of Nebraska - Lincoln

USDA National Wildlife Research Center - Staff
Publications

U.S. Department of Agriculture: Animal and Plant
Health Inspection Service

2014

Effects of GonaCon Immunocontraceptive Vaccine in Free-Ranging Female Rocky Mountain elk (*Cervus elaphus nelsoni*)

Jenny G. Powers

Biological Resource Management Division, National Park Service, Fort Collins, CO

Ryan J. Monello

Biological Resource Management Division, National Park Service, Fort Collins, CO

Margaret A. Wild

Biological Resource Management Division, National Park Service, Fort Collins, CO

Terry R. Spraker

Colorado State University

James P. Gionfriddo

United States Department of Agriculture, Animal and Plant Health Inspection Service, National Wildlife Research Center, Fort Collins, CO

See next page for additional authors

Follow this and additional works at: http://digitalcommons.unl.edu/icwdm_usdanwrc



Part of the [Life Sciences Commons](#)

Powers, Jenny G.; Monello, Ryan J.; Wild, Margaret A.; Spraker, Terry R.; Gionfriddo, James P.; Nett, Terry M.; and Baker, Dan L., "Effects of GonaCon Immunocontraceptive Vaccine in Free-Ranging Female Rocky Mountain elk (*Cervus elaphus nelsoni*)" (2014). *USDA National Wildlife Research Center - Staff Publications*. 1715. http://digitalcommons.unl.edu/icwdm_usdanwrc/1715

This Article is brought to you for free and open access by the U.S. Department of Agriculture: Animal and Plant Health Inspection Service at DigitalCommons@University of Nebraska - Lincoln. It has been accepted for inclusion in USDA National Wildlife Research Center - Staff Publications by an authorized administrator of DigitalCommons@University of Nebraska - Lincoln.

Authors

Jenny G. Powers, Ryan J. Monello, Margaret A. Wild, Terry R. Spraker, James P. Gionfriddo, Terry M. Nett,
and Dan L. Baker



Tools and Technology

Effects of GonaCon Immunocontraceptive Vaccine in Free-Ranging Female Rocky Mountain elk (*Cervus elaphus nelsoni*)

JENNY G. POWERS,¹ *Biological Resource Management Division, National Park Service, 1201 Oakridge Drive 200, Fort Collins, CO 80525, USA*

RYAN J. MONELLO, *Biological Resource Management Division, National Park Service, 1201 Oakridge Drive 200, Fort Collins, CO 80525, USA*

MARGARET A. WILD, *Biological Resource Management Division, National Park Service, 1201 Oakridge Drive 200, Fort Collins, CO 80525, USA*

TERRY R. SPRAKER, *Colorado State University, Veterinary Diagnostic Laboratory, 300 W Drake Road, Fort Collins, CO 80523, USA*

JAMES P. GIONFRIDDO,² *United States Department of Agriculture, Animal and Plant Health Inspection Service, National Wildlife Research Center, 4101 LaPorte Avenue, Fort Collins, CO 80525, USA*

TERRY M. NETT, *Animal Reproduction and Biotechnology Laboratory, Colorado State University, Fort Collins, CO 80523, USA*

DAN L. BAKER, *Animal Reproduction and Biotechnology Laboratory, Colorado State University, Fort Collins, CO 80523, USA*

ABSTRACT Duration of efficacy and prevalence of side-effects associated with GonaCon Immunocontraceptive Vaccine (GonaCon) in free-ranging female elk (*Cervus elaphus*) are unknown. In January 2008, we captured 120 mature female elk in Rocky Mountain National Park (CO, USA), determined pregnancy status, and randomly assigned them to treated ($n = 60$; 1.5 mL of GonaCon) or control ($n = 60$; 1.5 mL of saline) groups. During the following 3 winters we recaptured, collected blood for antibody concentrations, and euthanized 10–20 elk in each group. At necropsy, we determined pregnancy and collected tissues from organs associated with the hypothalamic–pituitary–gonadal axis. We relocated injection sites, collected muscle tissue, and performed bacterial culture when inflammation was present. Proportion of pregnant elk among control females ranged from 0.75 to 0.90. Proportion pregnant after treatment with GonaCon was 0.00 (95% CI = 0.0–0.22) in year 1, 0.31 (CI = 0.09–0.61) in year 2, and 0.65 (CI = 0.41–0.85) in year 3. Antibody concentrations were higher in non-pregnant than pregnant treated females. We found no antemortem evidence of lameness or swelling at the injection site; however, at necropsy all treated females had pyogranulomatous inflammation at the injection site. We observed no consistent changes within the hypothalamic–pituitary–gonadal axis. We conclude that GonaCon is effective at reducing pregnancy for 1–2 years post-vaccination and is strongly associated with sterile inflammation at the site of injection. Similar to other species, the vaccine is less effective in elk under free-ranging conditions than those in a captive environment. © 2014 The Wildlife Society.

KEY WORDS *Cervus elaphus*, elk, GonaCon, gonadotropin releasing hormone, immunocontraception, wildlife fertility control.

Rocky Mountain elk (*Cervus elaphus nelsoni*) are resilient, adaptable members of the cervid family. Much like white-tailed deer (*Odocoileus virginianus*), they thrive in a variety of habitats including the wildland–urban interface. When elk become locally overabundant, this plasticity can lead to a variety of human–wildlife conflicts and collateral effects, which may be ecological, sociological, or political in scope (Thompson and Henderson 1998). Fertility control is one method, among a suite of management tools, which may assist in mitigating these conflicts (Bradford and Hobbs 2008).

The idea and science of wildlife fertility control is not new. For >4 decades practitioners have investigated the efficacy and practicality of manipulating wildlife reproduction using a variety of methods in a wide range of species (Fagerstone et al. 2010); however, for a multitude of ecological and socio-political reasons, wildlife contraception has not been widely adopted as a means for population management (reviewed in Powers 2011). Recently, extended-duration immunocontraception using the self-antigen, gonadotropin releasing hormone (GnRH) has overcome some of the barriers to successful application of a fertility control agent.

Gonadotropin-releasing hormone is a small protein hormone naturally secreted in a variable pulsatile fashion from the hypothalamus (Clarke and Cummins 1982). It controls the reproductive hormone cascade that eventually results in signaling at the gonad and ovulation in females (Hazum and Conn 1988). A single vaccination against GnRH, using GonaCon Immunocontraceptive Vaccine

Received: 28 May 2013; Accepted: 11 January 2014

Published: 13 May 2014

¹E-mail: jenny_powers@nps.gov

²Present address: 15317 Red Canyon Ranch Road, Loveland, CO 80538, USA

(GonaCon; National Wildlife Research Center, Fort Collins, CO, USA; Miller et al. 2008), has been found to diminish endocrine and ovarian function within the hypothalamic–pituitary–gonadal axis in captive female elk (Powers et al. 2011). Presumably through immunoneutralization, antibodies directed against GnRH prevent or reduce GnRH stimulation at the anterior pituitary, reduce gonadotropin release, and prevent ovulation. As antibodies wane, females tend to return to fertility (Curtis et al. 2008, Gionfriddo et al. 2011a, Powers et al. 2011).

Extended infertility (≥ 3 yr) using GonaCon has been demonstrated in captive female elk (Killian et al. 2009, Powers et al. 2011); however, efficacy is unknown under free-ranging conditions. Vaccination of free-ranging white-tailed deer revealed shorter duration of efficacy and a higher apparent incidence of negative side-effects, such as injection-site abscesses, than in captive deer (Curtis et al. 2008; Miller et al. 2008; Gionfriddo et al. 2009, 2011a, b). The objective of this study was to determine the efficacy of GonaCon to reduce fertility in free-ranging female elk. We also sought to document and describe potential side-effects associated with vaccination.

STUDY AREA

This study was conducted in conjunction with, and used the same animals as, those described by Monello et al. (2013). We captured elk on their winter range within Rocky Mountain National Park, Colorado, USA. Elk primarily wintered in the eastern portion of the park and adjacent Estes Valley, which included the Town of Estes Park, Colorado (40°22'44"N, 105°32'36"W), between 2,500 m and 2,800 m in elevation (previously described in Conner et al. [2007] and Monello et al. [2013]).

Elk are seasonally polyestrous and breed during periods of decreasing day length. In North America, the peak of breeding season occurs between mid-September and mid-October and calving occurs from late May to early June after a gestation period of approximately 255 days (Haigh and Hudson 1993). Elk are monotonous, nearly always giving birth to a single calf; twinning is exceptionally rare (Haigh and Hudson 1993). Intrinsic pregnancy rates during 2003–2004 in this elk population were previously estimated to be between 0.82 and 1.0 (Conner et al. 2007), which was similar to rates reported for other free-ranging elk (Cook et al. 2004, Sargeant and Oehler 2007). This population was also habituated to the presence of humans; thus, ground-darting on foot and from vehicles was a feasible and effective method of capture.

MATERIALS AND METHODS

Animals and Treatment

This study was approved by the Colorado State University Institutional Animal Care and Use Committee (no. 07-231-01) and was conducted in conjunction with adaptive management practices described in the Rocky Mountain National Park Elk and Vegetation Management Plan (National Park Service 2007). During January 2008, we opportunistically selected and captured 120 mature adult (>2

yr) female elk using chemical immobilization and dart delivery [detailed capture methods are described in Monello et al. (2013)]. At the time of capture, we determined pregnancy status using transrectal palpation (Greer and Hawkins 1967, Hein et al. 1991), estimated body condition (1–5 scale; Cook et al. 2001a, b; Conner et al. 2007), and collected 10 mL whole blood via jugular venipuncture (BD Vacutainer SST; Becton Dickinson and Co., Franklin Lakes, NJ).

We randomly allocated animals into 2 groups: treated and control. We vaccinated treated females ($n=60$) with GonaCon (1.5 mg GnRH conjugate + adjuvant; 1.5 mL), and control females ($n=60$) received physiologic saline (0.9% NaCl; 1.5 mL). While the animal was in sternal recumbency, we placed injections mid-way between the tuber ischii of the caudal ischium and greater trochanter of the femur using a hand-held luer-lock syringe and 18-gauge, 3.8-cm needle. To facilitate injection-site relocation at necropsy, we measured (cm) and recorded the distance from the greater trochanter to the injection site.

GonaCon was prepared as previously described (Miller et al. 2008). The vaccine contained multiple synthetic copies of GnRH coupled to a large immunogenic carrier protein (Blue Carrier; Biosonda, Santiago, Chile) that was combined with a water-in-oil adjuvant containing killed *Mycobacterium avium* ssp. *avium* (AdjuVac, National Wildlife Research Center).

We fitted all experimental elk with very high-frequency radiocollars (Advanced Telemetry Systems, Isanti, MN) marked with individually identifiable black alphanumeric codes on colored background (blue for saline—control, yellow for GonaCon—treated; Conner et al. 2007). Color codes were employed to avoid confusion when later culling the animals and to prevent hunters from consuming treated animals if they were harvested outside of the park. We administered long-acting penicillin (6 million IU, SQ; DuraPen; Duravet, Blue Springs, MO) to mitigate potential infection associated with capture. Once all samples were collected, we reversed the effects of immobilizing agents (as described in Monello et al. [2013]).

Reproduction

We confirmed pregnancy status in January 2008 using serum pregnancy-specific protein-B assays from blood collected at the time of capture (Huang et al. 2000). During the following 3 winters (Dec–Jan), we recaptured and euthanized treated and control elk (2008–2009 = 10 treated, 10 control; 2009–2010 = 13 treated, 12 control; 2010–2011 = 20 treated, 14 control). Additionally, one GonaCon treated elk was euthanized in April 2009 due to unrelated circumstances and her pregnancy status was included in the data set. Pregnancy in euthanized elk was determined by direct inspection of the uterus at necropsy. Capture and sampling protocols were the same as above except that we euthanized each animal using pentobarbital sodium and phenytoin sodium (45 mL IV; Euthasol; Virbac AH, Inc., Fort Worth, TX). We transported carcasses to the Colorado State University Veterinary Diagnostic Laboratory and performed complete necropsies. Prior to transport, we

removed collars so the pathologist did not know treatment status at the time of necropsy. We estimated the age of each elk by removing a single central incisor at necropsy and submitting it for dental cementum annuli analysis (Matson Laboratory LLC, Milltown, MT; Hamlin et al. 2000).

Antibody Concentrations

We measured GnRH antibody concentrations (pmol ^{125}I -GnRH bound/mL of serum) using a previously described radioimmunoassay technique (Powers et al. 2011). All samples were run in a single batch. The intra-assay coefficient of variation was 7.0%. We measured GnRH binding capacity from serum samples collected prior to treatment and at the time of euthanasia, 1–3 years post-vaccination.

Adverse Side-Effects

We confirmed survival status weekly throughout the study using radiotelemetry. Additionally, we relocated each female at least bi-monthly and observed the injection site from a distance of approximately 20–100 m using binoculars. We noted obvious lameness and injection-site swelling or discharge. Similarly, prior to darting and re-capture (2009–2011), we observed each female at a distance of 10–40 m for evidence of changes in gait or lameness as well as injection-site swelling or discharge. At the time of necropsy (approx. 2–6 hr post-euthanasia), we relocated the injection site, collected a swab of the area if purulent inflammation was present, and collected 5–20 g of affected muscle tissue, which was preserved in 10% neutral buffered formalin. During the final 2 years, we measured lesion length, height, and width (cm) and calculated volume (cm^3). In 77 of 79 necropsies, we collected and preserved the draining internal iliac lymph node from the leg containing the injection site. We collected sections of uterine wall, cotyledon (if gravid), ovary (with corpus luteum, if present), hypothalamus, and pituitary gland, and preserved all tissues in formalin. Finally, we visually evaluated all major organs including cardiovascular, respiratory, renal, immune, and hepatic systems. If gross abnormalities were observed, we collected tissue for histopathology.

We submitted swabs collected from the site of injection to the Colorado State University Veterinary Diagnostic Laboratory for aerobic, anaerobic, and mycobacterial culture. We allowed all preserved tissues to fix for 1 week and used standard histology techniques to paraffin embed, section, and stain tissues. Sections of muscle taken from the injection site were stained with Ziehl–Neelsen stain to identify acid-fast microbial organisms such as mycobacteria. A veterinary pathologist (T.R. Spraker) examined all slides for pathologic changes in tissue architecture and evidence of inflammation.

Analysis

We used information-theoretic model selection to evaluate the ability of treatment and individual characteristics to explain the pregnancy status of adult female elk. To assess the importance of these parameters on pregnancy, we developed 11 candidate models that included treatment group (GonaCon-treated or saline control), time since injection (yr of study), age, and body condition. *A priori* hypotheses and model formulation was based on factors known to influence pregnancy status in elk (Stewart et al. 2005), and

we examined both the additive and interactive effects of study year and treatment and study year and body condition. Intercept-only and global models were also included in model selection procedures.

We used generalized linear models with a binomial distribution and logit link for model selection (Hardin and Hilbe 2007). Pregnancy status of each individual was the sample unit. We conducted a goodness-of-fit test to assess the ability of model parameters to explain pregnancy by comparing the global model against the intercept-only model (Franklin et al. 2000). We proceeded with model-selection procedures only if global models provided a better fit than intercept-only models ($\alpha = 0.05$). We calculated Akaike's Information Criterion (corrected for small sample size; AIC_c) and ranked the models based on differences between the best approximating model and all other models (ΔAIC_c) in the candidate set. Models with a ΔAIC_c value ≤ 2 of the best-fitting model were considered to have substantial empirical support as a best-fitting model. To better assess model structure and factors, we calculated the overdispersion factor of the best-fit model, model weight (i.e., the relative likelihood that a particular model is the best-fit model), and model-averaged estimates ($\pm 95\%$ unconditional confidence interval [CI]) for the effect size of each parameter in the 95% confidence set of models ($\sum \text{model wt} \geq 0.95$; Burnham and Anderson 2002).

We report pregnancy proportions, antibody concentrations, lesion size, and body condition scores as arithmetic means with 95% CI.

RESULTS

Vaccine Efficacy

At the time of initial capture and treatment application, the proportion pregnant in GonaCon-vaccinated females was 0.85 (CI = 0.73–0.93) and in control females was 0.92 (CI = 0.82–0.97). During our study, proportion of pregnant females in the treated group increased from 0.0 (CI = 0.0–0.22) 1 year post-treatment to 0.65 (CI = 0.41–0.85) 3 years post-treatment (Fig. 1). Proportion pregnant in the control group varied from a low of 0.75 (CI = 0.43–0.95) to a high of 0.90 (CI = 0.56–1.00; Fig. 1).

Goodness-of-fit tests that compared the ability of the global and intercept-only model to explain pregnancy were significantly different (likelihood ratio $\chi^2 = 37.65$, $\text{df} = 9$, $P < 0.001$). Only 2 models were considered to have substantial support as the best-fit model for pregnancy (ΔAIC_c of 0–2); both included the interaction treatment \times year, and one also included body condition (Table 1; overdispersion of best-fit model = 0.92). Model-averaged estimates clearly indicated that the interactive effects of treatment and year had the largest influence on pregnancy status, with the greatest effects of vaccination occurring in the first year of the study (Table 2 and Fig. 1). The effects of vaccination persisted at a reduced level into the second year of the study, but were absent by the third year, when the pregnancy rate of treated elk more than doubled from the prior year's value (Table 2 and Fig. 1).

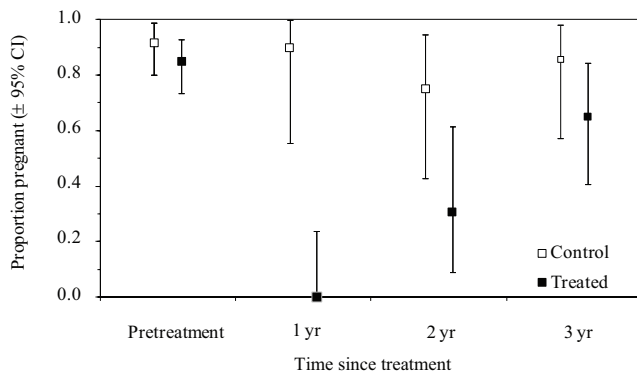


Figure 1. Proportion ($\pm 95\%$ CI) of female elk sampled at Rocky Mountain National Park, Colorado that were pregnant prior to treatment (January 2008) with either GonaCon Immunocontraceptive Vaccine (treated group) or saline (control group) and pregnancy proportions 1–3 years post-treatment (winters of 2009–2011). Sample sizes at the time of treatment were 60/group and in each year after ranged from 10 to 20 elk/group; no elk were sampled more than once post-injection. Immunocontraception was effective for 2 years post-treatment but pregnancy proportions between treated and control elk were similar 3 years post-treatment.

Three-year mean serum GnRH antibody concentrations in non-pregnant GonaCon-treated females (28 pmol/mL; CI = 27–29) were higher than in pregnant treated females (7 pmol/mL; CI = 6–8; Fig. 2). There was no evidence of GnRH antibodies in pretreatment serum samples from any animal (data not shown) or post-treatment control serum samples (Fig. 2). In all GonaCon-treated females, regardless of pregnancy status, GnRH antibody concentrations were highest the first year after vaccination at 29 pmol/mL (CI = 22–37) and declined to a mean of 13 pmol/mL (CI = 7–18) by the third year post-treatment.

Body condition had little to no effect on pregnancy proportions (Table 2). Mean body condition 1–3 years post-treatment was 3.01 (CI = 2.77–3.24) in control females and 3.19 (CI = 2.97–3.41) in GonaCon-treated females.

Adverse Side-Effects

We did not observe any lameness or visible lesions at the site of injection prior to recapture and euthanasia. We could not

detect any abnormalities externally with direct palpation of the injection site prior to euthanasia. In contrast, at the time of necropsy, all 43 GonaCon-treated females had grossly visible subcutaneous or intramuscular lesions at the injection site. Lesion size varied greatly from 1 cm³ to 492 cm³. Mean lesion size in treated animals was 101 cm³ (CI = 2–199) 2 years post-treatment and 130 cm³ (CI = 87–173) 3 years post-treatment. Most contained purulent material that varied in consistency from liquid to caseate. Lesions varied from one large mass to complex multi-loculated granulomas that dissected along tissue planes. Granulomatous myositis tended to be encapsulated within a thick wall of fibroplasia with extensive collagen deposition and inflammatory cell infiltrates including macrophages, lymphocytes, plasma cells, and multinucleated giant cells.

We cultured 33 of 43 injection-site lesions for anaerobic and aerobic bacteria, including mycobacteria. Approximately 6% (2/33) had microbial growth. Light growth of *Staphylococcus* sp. and non-hemolytic *Streptococcus* sp. were each cultured once. No mycobacteria species were cultured. We found acid-fast organisms consistent with mycobacteria twice within fixed tissues taken from injection sites. On 3 occasions, the draining internal iliac lymph nodes had similar pyogranulomatous inflammation as that seen at the injection site, though not to the same severity. Histology of muscle tissue collected from the area of the injection sites of control females was within normal limits and we did not find evidence of inflammatory processes.

We did not identify any consistent lesions in tissues from the hypothalamic–pituitary–gonadal axis of treated or control elk. Hypothalami were within normal limits and showed no evidence of inflammatory cell infiltrates. We identified a granulosa cell tumor in the ovary of one treated female and an ovarian teratoma and a cystic ovary in 2 separate control females. All ovarian pathology was considered incidental.

DISCUSSION

A single vaccination against GnRH using GonaCon during mid-gestation successfully prevented pregnancy the following year, and was moderately effective 2 years after

Table 1. Rankings of *a priori* models used to determine pregnancy status in female elk at Rocky Mountain National Park, Colorado subjected to treatment with a contraceptive agent (GonaCon Immunocontraceptive Vaccine, $n = 44$) or a control injection of saline ($n = 36$). Rankings are based on generalized linear models with a binomial distribution and logit identity. Contraceptive treatment, year since treatment was given, and the interaction between treatment and year were the most important factors in predicting pregnancy.

Model	$\log_e(L)$	K	AIC_c	ΔAIC_c	ω_i
Treatment \times year + treatment + year	–36.71	6	86.58	0.00	0.58
Treatment \times year + condition + treatment + year	–36.16	7	87.87	1.29	0.30
Treatment + year + condition	–39.91	5	90.62	4.05	0.08
Global model	–35.40	10	93.98	7.40	0.01
Treatment + condition	–44.26	3	94.84	8.26	0.01
Treatment	–45.57	2	95.30	8.72	0.01
Treatment + condition + age	–43.60	4	95.74	9.16	0.01
Treatment + age	–45.34	3	96.99	10.42	0.00
Treatment + year	–51.30	3	108.91	22.34	0.00
Intercept-only model	–54.22	1	110.49	23.91	0.00
Year + condition	–51.05	4	110.63	24.06	0.00
Year \times condition + year + condition	–51.49	4	111.52	24.94	0.00
Condition	–53.83	2	111.82	25.24	0.00

Table 2. Model-averaged estimates of parameter effect size for those included in the 95% confidence set of models used to determine pregnancy status in female elk at Rocky Mountain National Park, Colorado subjected to treatment with a fertility control agent (GonaCon Immunocontraceptive Vaccine, $n = 44$) or a control injection of saline ($n = 36$). Estimates are based on generalized linear models with a binomial distribution and logit identity.

Parameter	Estimate	Unconditional SE	95% unconditional CI
Treatment \times year 1	-4.18	1.55	-7.21, -1.14
Treatment \times year 2	-2.64	0.98	-4.56, -0.72
Treatment \times year 3	-1.22	0.90	-2.99, 0.55
No treatment \times year 1	0.37	1.31	-2.19, 2.93
No treatment \times year 2	-0.64	1.02	-2.64, 1.36
No treatment \times year 3	0.00	0.00	
Treatment	-2.54	0.67	-3.85, -1.24
No treatment	0.00	0.00	
Year 1	-1.97	0.75	-3.45, -0.049
Year 2	-1.31	0.67	-2.62, 0.01
Year 3	0.00	0.00	
Body condition	0.50	0.43	-0.39, 1.39

vaccination, but there were no clear differences in the treated and control groups by the third year of the study. Similar work in captive elk using the same vaccine formulation found that GonaCon reduced pregnancy by 50–100% for up to 3 years post-treatment (Powers et al. 2011), suggesting that this vaccine has a reduced duration of efficacy in free-ranging elk. This is consistent with our anti-GnRH antibody concentrations, which were neither as robust nor as persistent in free-ranging elk as captive elk (Powers et al. 2011).

This finding is also consistent with effects of GonaCon observed in captive versus free-ranging white-tailed deer (Miller et al. 2008; Gionfriddo et al. 2009, 2011a). No definitive cause for differences in efficacy between captive and free-ranging populations has been determined; however, it has been suggested that differences in immune-response and therefore efficacy may be attributable to variance in

nutritional status, micro- or macro-parasite load or exposure, previous pathogen exposure, environmental contact with mycobacteria, or other sources of physiologic stress (Tizard 1982, Gionfriddo et al. 2011b, Powers et al. 2011). All of these factors have the potential to potentiate or inhibit the response to a novel antigen such as GnRH coupled to a mollusk protein in the GonaCon vaccine. Thus, free-ranging cervids, which generally have a lower plane of nutrition and increased number of stressors compared with captive wildlife, may not produce as vigorous an immune response. This hypothesis is supported by prior work that found diminished and less persistent GnRH antibody concentrations in free-ranging versus captive white-tailed deer (Miller et al. 2008, Gionfriddo et al. 2011a) and is in accordance with our current antibody findings.

Although there were no outwardly visible signs of lameness or dysfunction associated with vaccination, every treated animal had grossly evident inflammation at the site of injection, which varied in size and shape and contained up to 500 mL of suppuration. There was no evidence to suggest that injection-site lesions decreased in size or severity between years. This is not surprising given the vaccine is composed of non-biodegradable mineral oil and contains strongly immunogenic-killed mycobacteria similar to vaccines made with Freund's complete (FCA) and modified Freund's complete (mFCA) adjuvants (Lyda et al. 2005, Powers et al. 2007, Roelle and Ransom 2009, Ransom et al. 2011). Other studies using GnRH vaccines or porcine zona pellucida vaccines (another type of immunocontraceptive vaccine), which use similar mycobacterial emulsion type adjuvants, did not identify injection-site lesions at the prevalence we did in this investigation (Curtis et al. 2002, Lyda et al. 2005, Roelle and Ransom 2009, Powers et al. 2011). However, many studies did not necropsy animals post-vaccination, and in most cases exact injection-site locations were not determined to ensure accurate reassessment. In all studies where post-mortem examinations were performed, prevalence of injection-site inflammation and abscesses were higher than those that were clinically apparent antemortem (Curtis et al. 2007, 2008; Powers et al. 2007; Gionfriddo et al. 2009, 2011b). Therefore, it should not be inferred that lack of clinically evident antemortem abscess

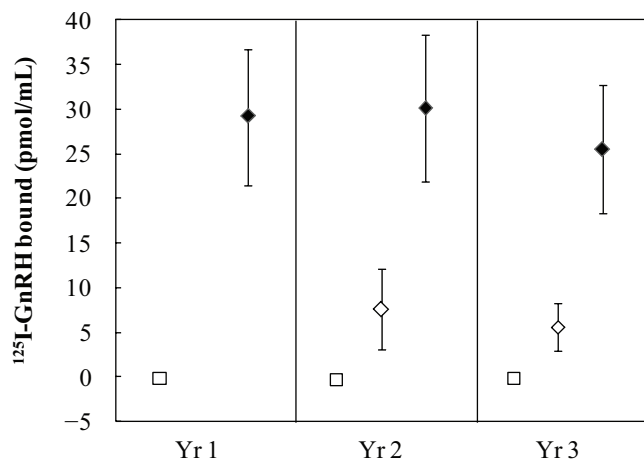


Figure 2. Yearly mean gonadotropin releasing hormone antibody concentrations presented as pmol of ^{125}I -GnRH bound (e.g., antibody binding capacity) in 1 mL of serum ($\pm 95\%$ CI), collected from female elk treated in January 2008 with either GonaCon Immunocontraceptive Vaccine (treated group) or saline (control group) at Rocky Mountain National Park, Colorado. Closed diamonds (\blacklozenge) represent non-pregnant—treated females (vaccine success); open diamonds (\diamond) represent pregnant treated females (vaccine failure); and open squares (\square) represent control females (both pregnant and non-pregnant). In year 1 no treated females were pregnant. Error bars are too small to present for yearly means in control females. Higher antibody concentrations were associated with contraception success.

formation means that these immunocontraceptive vaccines do not cause significant inflammation at the site of injection. Additional post-mortem studies across multiple species are required to determine whether this is a general trend among immunocontraceptive vaccines.

Injection-site lesions were most often sterile. Although bacteria were occasionally cultured from swabs taken of purulent inflammation at the site of injection, we postulate that these were surface contaminants. Non-hemolytic *Streptococcus* sp. and *Staphylococcus* sp. are common mammalian skin commensal organisms (Hirsh and Biberstein 2004a, b). Given clean but not sterile collection techniques at the time of necropsy, it is not surprising that we could have inadvertently introduced small amounts of contamination at this time. Additionally, cells found at injection sites were characteristic of granulomatous inflammation, which is classically associated with the presence of mycobacteria (Ackermann 2007). It is highly unlikely that the vaccine itself was responsible for bacterial growth at the site of injection. We suggest, as previously reported by others (Curtis et al. 2008, Gionfriddo et al. 2011b), that the combination of killed mycobacteria and a non-biodegradable mineral oil created a long-lasting depot of immune-stimulating antigen that continued to attract macrophages and lymphocytes and incite formation of persistent pyogranulomatous inflammation. Despite substantial injection-site lesions in every animal, we did not see clinical evidence of altered locomotion or detriment to the general health and fitness of treated elk. The cumulative effects of revaccination are unknown at this time; however, the potential exists for more intense immune reactions with additional doses of mycobacterial adjuvant once the animal has been primed with an initial dose (Broderson 1989). Additional studies, particularly on the effects of revaccination, are needed to understand the potential range of effects that could occur with long-term management programs that seek to use vaccines such as GonaCon to regulate population size.

It has been suggested that wildlife fertility control offers an alternative management technique to lethal removal. Although our study demonstrates that immunocontraception using GonaCon can decrease fertility of individual animals, there is little empirical evidence in the literature to indicate that fertility control techniques can be effectively applied on a scale large enough to limit population growth rates of free-ranging cervids, especially when immigration or emigration are important drivers of population size (Merrill et al. 2006, Ransom et al. 2014). Jurisdictional boundaries rarely contain entire populations of highly mobile and often migratory cervids, which poses a significant challenge for treating sufficient proportions of a functionally continuous population unless all affected wildlife management agencies are in agreement that this is a preferred management strategy. There are substantial limitations to the population-level efficacy of fertility control even within closed populations of cervids with high reproductive and survival rates (Hobbs et al. 2000). Additionally, there are potentially large ecological effects—such as changes to natural selection, effects on social structures and reproductive behavior, timing

of mating and birthing seasons, changes to longevity, and effects on migratory or movement patterns—that still need to be examined in free-ranging populations prior to use as a management tool (Cooper 2004, Powers 2011, Ransom et al. 2014).

Our data indicate that a single injection of GonaCon will significantly decrease reproduction in free-ranging female elk. However, this does not resolve the more important question, which asks whether this equates to a viable tool for managing human-wildlife conflicts in the future. Only by engaging in socio-political discourse with interested stakeholder groups informed by knowledge of population-level effects will we discover whether the costs and benefits of wildlife fertility control are adequately balanced to seriously consider contraceptive technology a practical wildlife management alternative.

ACKNOWLEDGMENTS

We thank M. Graham, S. Ratchford, V. Jameson, E. Wheeler, J. Spaak, and A. Graham, for invaluable field, laboratory, and data compilation assistance; and V. Baker, B. Bobowski, J. Mack, T. Johnson, M. K. Watry, J. Visty, and G. Miller from Rocky Mountain National Park for making this research possible and providing field assistance. The National Wildlife Research Center (K. Fagerstone, J. Rhyhan, C. Bens, J. Kemp, and L. Miller) kindly provided the vaccine and good laboratory practices (GLP) oversight for the project. This work was funded by the National Park Service.

LITERATURE CITED

- Ackermann, M. R. 2007. Chronic inflammation and wound healing. Pages 153–191 in M. D. McGavin, and J. F. Zachary, editors. Pathologic basis of veterinary disease. Fourth edition. Mosby, St. Louis Missouri, USA.
- Bradford, J. B., and N. T. Hobbs. 2008. Regulating overabundant ungulate populations: an example for elk in Rocky Mountain National Park, Colorado. *Journal of Environmental Management* 86:520–528.
- Broderson, J. R. 1989. A retrospective review of lesions associated with the use of Freund's adjuvant. *Laboratory Animal Science* 39:400–405.
- Burnham, K. P., and D. R. Anderson. 2002. Model selection and multimodel inference: a practical information-theoretic approach. Springer-Verlag, New York, New York, USA.
- Clarke, I. J., and J. T. Cummins. 1982. The temporal relationship between gonadotropin releasing hormone (GnRH) and luteinizing hormone (LH) secretion in ovariectomized ewes. *Endocrinology* 111:1737–1739.
- Conner, M. A., D. L. Baker, M. A. Wild, J. G. Powers, M. D. Hussain, R. L. Dunn, and T. M. Nett. 2007. Fertility control in free-ranging elk using gonadotropin-releasing hormone agonist leuprolide: effects on reproduction, behavior, and body condition. *Journal of Wildlife Management* 71:2346–2356.
- Cook, R. C., J. G. Cook, and L. D. Mech. 2004. Nutritional condition of northern Yellowstone elk. *Journal of Mammalogy* 85:714–722.
- Cook, R. C., J. G. Cook, D. L. Murray, P. Zager, B. K. Johnson, and M. W. Gratson. 2001a. Development of predictive models of nutritional condition for Rocky Mountain elk. *Journal of Wildlife Management* 65:973–987.
- Cook, R. C., J. G. Cook, D. L. Murray, P. Zager, B. K. Johnson, and M. W. Gratson. 2001b. Nutritional condition models for elk: which are the most sensitive, accurate, and precise? *Journal of Wildlife Management* 65:988–997.
- Cooper, D. W. 2004. Should immunocontraception be used for wildlife population management? *Australian Mammalogy* 26:61–65.
- Curtis, P. D., R. L. Pooler, M. E. Richmond, L. A. Miller, G. F. Mattfeld, and F. W. Quimby. 2002. Comparative effects of GnRH and porcine zona pellucida (PZP) immunocontraceptive vaccines for controlling reproduc-

- tion in white-tailed deer (*Odocoileus virginianus*). *Reproduction Supplement* 60:131–141.
- Curtis, P. D., M. E. Richmond, L. A. Miller, and F. W. Quimby. 2007. Pathophysiology of white-tailed deer vaccinated with porcine zona pellucida immunocontraceptive. *Vaccine* 25:4623–4630.
- Curtis, P. D., M. E. Richmond, L. A. Miller, and F. W. Quimby. 2008. Physiological effects of gonadotropin releasing hormone vaccination immunocontraception on white-tailed deer. *Human–Wildlife Conflicts* 2:68–79.
- Fagerstone, K. A., L. A. Miller, G. Killian, and C. A. Yoder. 2010. Review of issues concerning the use of reproductive inhibitors, with particular emphasis on resolving human–wildlife conflicts in North America. *Integrative Zoology* 5:15–30.
- Franklin, A. B., D. R. Anderson, R. J. Gutiérrez, and K. P. Burnham. 2000. Climate, habitat quality, and fitness in northern spotted owl populations in northwestern California. *Ecological Monographs* 70:539–590.
- Gionfriddo, J. P., A. J. DeNicola, L. A. Miller, and K. A. Fagerstone. 2011a. Efficacy of GnRH immunocontraception of wild white-tailed deer in New Jersey. *Wildlife Society Bulletin* 35:142–148.
- Gionfriddo, J. P., A. J. DeNicola, L. A. Miller, and K. A. Fagerstone. 2011b. Health effects of GnRH immunocontraception of wild white-tailed deer in New Jersey. *Wildlife Society Bulletin* 35:149–160.
- Gionfriddo, J. P., J. D. Eisemann, K. J. Sullivan, R. S. Healey, L. A. Miller, K. A. Fagerstone, R. M. Engeman, and C. A. Yoder. 2009. Field test of a single-injection gonadotropin-releasing hormone immunocontraceptive vaccine in female white-tailed deer. *Wildlife Research* 36:177–184.
- Greer, K. R., and W. W. Hawkins. 1967. Determining pregnancy in elk by rectal palpation. *Journal of Wildlife Management* 31:145–149.
- Haigh, J. C., and R. J. Hudson. 1993. *Farming wapiti and red deer*. Mosby, St. Louis, Missouri, USA.
- Hamlin, K. L., D. F. Pac, C. A. Sime, R. M. DeSimone, and G. L. Dusek. 2000. Evaluating the accuracy of ages obtained by two methods for Montana ungulates. *Journal of Wildlife Management* 64:441–449.
- Hardin, J. W., and J. M. Hilbe. 2007. *Generalized linear models and extensions*. Stata Press, College Station, Texas, USA.
- Hazum, E., and P. M. Conn. 1988. Molecular mechanism of gonadotropin releasing hormone (GnRH) action. I. The GnRH receptor. *Endocrine Reviews* 9:379–386.
- Hein, R. G., J. L. Musser, and E. F. Bracken. 1991. Serologic, parasitic and pregnancy survey of the Colockum elk herd in Washington. *Northwest Science* 65:217–222.
- Hirsh, D. C., and E. L. Biberstein. 2004a. *Staphylococcus*. Pages 153–158 in D. C. Hirsh, N. J. MacLachlan, and R. L. Walker, editors. *Veterinary microbiology*. Second edition. Blackwell, Ames, Iowa, USA.
- Hirsh, D. C., and E. L. Biberstein. 2004b. *Streptococcus and enterococcus*. Pages 159–167 in D. C. Hirsh, N. J. MacLachlan, and R. L. Walker, editors. *Veterinary microbiology*. Second edition. Blackwell, Ames, Iowa, USA.
- Hobbs, N. T., D. C. Bowden, and D. L. Baker. 2000. Effects of fertility control on populations of ungulates: general, stage-structured models. *Journal of Wildlife Management* 64:473–491.
- Huang, F., D. C. Cockrell, T. R. Stephenson, J. H. Noyes, and R. G. Sasser. 2000. A serum pregnancy test with a specific radioimmunoassay for moose and elk pregnancy-specific protein B. *Journal of Wildlife Management* 64:492–499.
- Killian, G., T. J. Kreeger, J. Rhyhan, K. Fagerstone, and L. Miller. 2009. Observations on the use of GonaCon in captive female elk (*Cervus elaphus*). *Journal of Wildlife Diseases* 45:184–188.
- Lyda, R. O., J. R. Hall, and J. F. Kirkpatrick. 2005. A comparison of Freund's complete and Freund's modified adjuvants with a contraceptive vaccine in wild horses (*Equus caballus*). *Journal of Zoo and Wildlife Medicine* 36:610–616.
- Merrill, J. A., E. G. Cooch, and P. D. Curtis. 2006. Managing an overabundant deer population by sterilization: effects of immigration stochasticity and the capture process. *Journal of Wildlife Management* 70:268–277.
- Miller, L. A., J. P. Gionfriddo, K. A. Fagerstone, J. C. Rhyhan, and G. J. Killian. 2008. The single-shot GnRH immunocontraceptive vaccine (GonaCon) in white-tailed deer: comparison of several GnRH preparations. *American Journal of Reproductive Immunology* 60:214–223.
- Monello, R. J., J. G. Powers, N. T. Hobbs, T. R. Spraker, K. I. O'Rourke, and M. A. Wild. 2013. Efficacy of antemortem rectal biopsies to diagnose and estimate prevalence of chronic wasting disease in free-ranging cow elk (*Cervus elaphus nelsoni*). *Journal of Wildlife Diseases* 49:270–278.
- National Park Service. 2007. Final elk and vegetation management plan/ Environmental Impact Statement. Rocky Mountain National Park, Estes Park, Colorado, USA. http://www.nps.gov/romo/parkmgmt/elk-veg_mgmt_plan_feis.htm. Accessed 21 Mar 2014.
- Powers, J. G. 2011. Reproductive, behavioral, and first generational effects of gonadotropin releasing hormone vaccination in female Rocky Mountain elk (*Cervus elaphus nelsoni*). Dissertation, Colorado State University, Fort Collins, USA.
- Powers, J. G., D. L. Baker, T. L. Davis, M. M. Conner, A. H. Lothridge, and T. M. Nett. 2011. Effects of gonadotropin-releasing hormone immunization on reproductive function and behavior in captive female Rocky Mountain elk (*Cervus elaphus nelsoni*). *Biology of Reproduction* 85:1152–1160.
- Powers, J. G., P. B. Nash, J. C. Rhyhan, C. A. Yoder, and L. A. Miller. 2007. Comparison of immune and adverse effects induced by AdjuVac and Freund's complete adjuvant in New Zealand white rabbits (*Oryctolagus cuniculus*). *Lab Animal* 36:51–58.
- Ransom, J. I., J. G. Powers, N. T. Hobbs, and D. L. Baker. 2014. Ecological feedbacks can reduce population-level efficacy of wildlife fertility control. *Journal of Applied Ecology* 51:259–269.
- Ransom, J. I., J. E. Roelle, B. S. Cade, L. Cotes-Markle, and A. J. Kane. 2011. Foaling rates in feral horses treated with the immunocontraceptive porcine zona pellucida. *Wildlife Society Bulletin* 35:343–352.
- Roelle, J. E., and J. I. Ransom. 2009. Injection-site reactions in wild horses (*Equus caballus*) receiving an immunocontraceptive vaccine. U.S. Geological Survey Scientific Investigations Report 2009-5038, Reston, Virginia, USA.
- Sargeant, G. A., and M. W. Oehler Sr. 2007. Dynamics of newly established elk populations. *Journal of Wildlife Management* 71:1141–1148.
- Stewart, K. M., R. T. Bowyer, B. L. Dick, B. K. Johnson, and J. G. Kie. 2005. Density-dependent effects on physical condition and reproduction in North American elk: an experimental test. *Oecologia* 143:85–93.
- Thompson, M. J., and R. E. Henderson. 1998. Elk habituation as a credibility challenge for wildlife professionals. *Wildlife Society Bulletin* 26:477–483.
- Tizard, I. 1982. *An introduction to veterinary immunology*. First edition. W.B. Saunders, Philadelphia, Pennsylvania, USA.

Associate Editor: Rominger.