University of Nebraska - Lincoln
DigitalCommons@University of Nebraska - Lincoln

Historical Materials from University of Nebraska-Lincoln Extension

Extension

1969

EC69-1902 Cost You Money : Controlling Internal Parasites in Swine

Donald Ferguson

E. Crosby Howe

Follow this and additional works at: http://digitalcommons.unl.edu/extensionhist

Ferguson, Donald and Howe, E. Crosby, "EC69-1902 Cost You Money : Controlling Internal Parasites in Swine" (1969). *Historical Materials from University of Nebraska-Lincoln Extension*. 3950.
http://digitalcommons.unl.edu/extensionhist/3950

This Article is brought to you for free and open access by the Extension at DigitalCommons@University of Nebraska - Lincoln. It has been accepted for inclusion in Historical Materials from University of Nebraska-Lincoln Extension by an authorized administrator of DigitalCommons@University of Nebraska - Lincoln.

AGRI
2
EC
1
69-1902
c. 1



EC 69-1902

worms cost you money

CONTROLLING INTERNAL PARASITES IN SWINE

Cooperative Extension Service, University of Nebraska, College of Agriculture and Home Economics, and U.S. Department of Agriculture Cooperating
E.F. Frolik, Dean J.L. Adams, Director

Acknowledgments

Financial assistance from the following companies made possible the printing of this publication in color:

1. American Cyanamid Company
   Agricultural Division
   P.O. Box 400
   Princeton, N. J. 08540

2. Interstate Chemical Company
   A Division of West Chemical Products, Inc.
   501 Santa Fe
   Kansas City, Mo. 64105

3. Shell Chemical Company
   Agricultural Chemicals Division
   P.O. Box 813
   Princeton, N. J. 08540

4. Smith Kline & French Laboratories
   1600 Paoli Pike
   West Chester, Pa. 19380

Controlling Internal Parasites In Swine

Donald L. Ferguson
Asst. Professor (Parasitology)
E. Crosby Howe
Extension Animal Hygienist

The large intestinal roundworm, *Ascaris suum,* is the most common internal parasite of pigs (Fig. 1). These worms cost swine producers of the United States an estimated $50 million a year.

This parasite is found in almost every herd in Nebraska and it is not unusual to find several hundred worms per pig. Control this parasite and you can increase your swine program profit.

Life Cycle: Eggs of *Ascaris suum* are oval and have thick shells covered by a layer of proteinaceous material, the surface of which is rough and uneven (Fig. 2). Each egg is about the diameter of a human hair and is almost invisible to the naked eye.

Eggs can withstand severe cold, dryness and most chemical disinfectants and can live at least seven years in soil.

These microscopic eggs pass from pigs in manure. When they leave the body with the feces, the eggs are in an early stage of development and are not infective. Within a few weeks, especially when the weather is warm and the eggs remain moist, a tiny larva develops inside the egg shell.

Pigs become infected by consuming food and water contaminated with infective worm eggs. When a pig swallows ascarid eggs, the shell membranes rupture in the small intestine and larvae are liberated. The larvae leave the intestine by burrowing into the intestinal wall

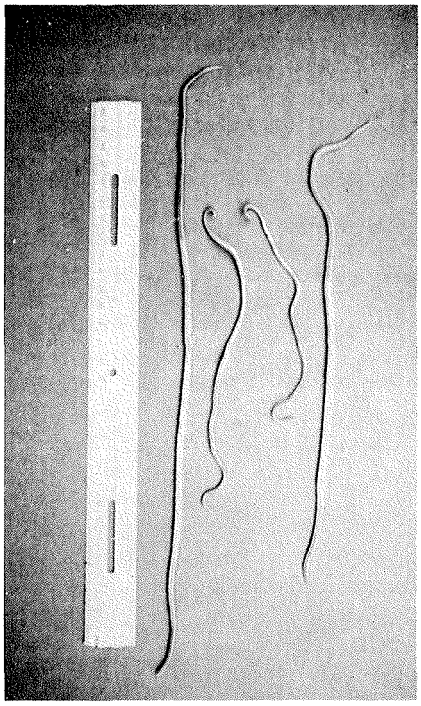

Fig. 1—Male worms (center) are identified by the sharply curled tail and small size. The females are filled with reproductive organs and can deposit one million eggs per day.

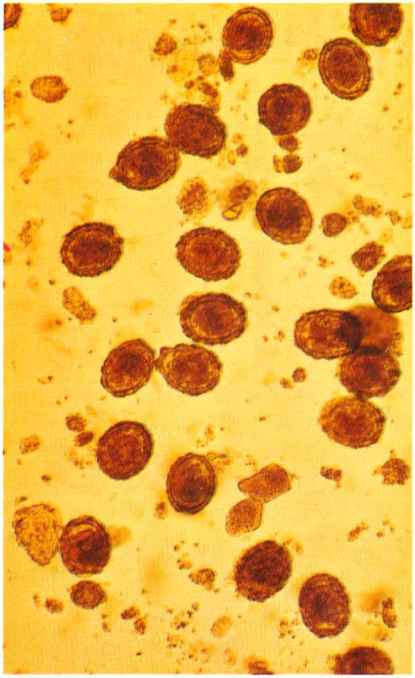

Fig. 2—Eggs of the large roundworm are about the same diameter as a hair and are resistant to physical, chemical and bacterial action.

and entering the blood stream, which carries them to the liver. From the liver larvae travel in the bloodstream through the heart on the way to the lungs.

In the lungs larvae leave the blood, burrow through lung tissue and enter large air passages. Coughing forces worms into the throat where they are swallowed and passed into the small intestine—this time to mature and grow to adults.

It takes about four days for the majority of the larvae to reach the liver and about nine days to reach the lungs. Almost all of the larval worms are back in the small intestine 15 days after the eggs are eaten. Worms grow to egg-laying adults in about 60 days.

Clinical Signs: In pigs infected with *Ascaris suum,* clinical signs are usually directly associated with the migratory phase of the larvae in the lungs. Typical signs are a dry nonproductive cough, loss of appetite and weight, rough hair coat, rise in temperature, and an increased rate of respiration accompanied by thumping.

When virus pig pneumonia (VPP) and ascarid larvae are present in the lungs at the same time, the lung consolidation (pneumonia) is 10 times greater than that caused by VPP alone (Fig. 3). Since about 60% of the swine herds in the United States have VPP, it is important to control ascarids, since there is no effective treatment or vaccine for this disease.

Both young and adult worms cause damage. Young worms destroy liver tissue, causing abscesses and scars (Fig. 4). In the lungs they penetrate blood vessels, destroy tissue and plug smaller air passages. The result is labored breathing accompanied by thumping and pneumonia (Fig. 5).

Adult worms in the intestine rob the pig of food, block the gut and excrete substances which interfere with digestion. Worms in the bile duct stop the flow of bile into the intestine (Fig. 6). When bile is not discharged into the intestine, it is absorbed by the blood and carried to all parts of the body. Bile-stained meat is inedible. Such carcasses are condemned and destroyed.

Diagnosis: Microscopic identification of characteristic eggs in the feces. Adult worms are easily seen

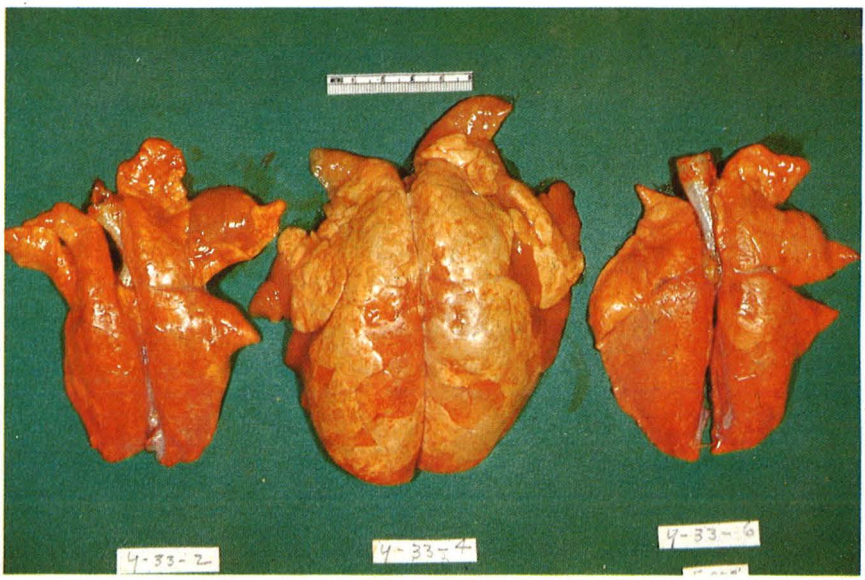

Fig. 3—Migrating ascarid larvae increase the severity of respiratory infections. Lungs on the left had only virus pneumonia (VPP) while the lungs in the center were inoculated with VPP when larvae were migrating through the lungs. Lungs on the right had ascarid larvae but no VPP virus and had recovered.

upon postmortem examination of intestinal contents.

Treatment: Piperazine and Atgard V are drugs of choice.

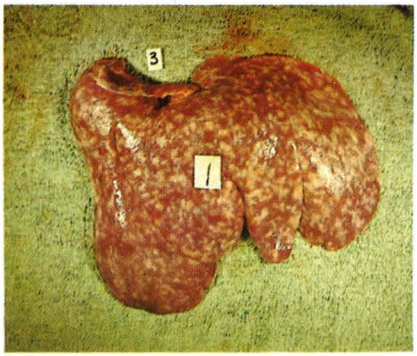

Fig. 4—Liver damage caused by migrating larvae of *Ascaris suum*.

Fig. 5—Hemorrhages on swine lungs 5 days after exposure to migrating larvae of the large roundworm—*Ascaris suum*.

Fig. 6—Ascarids often migrate into the bile duct of the gall bladder obstructing bile flow and causing jaundice in the pig.

Whipworms

The whipworm, *Trichuris suis,* is given this name because the front two-thirds of its body is much thinner than the back third, so that the whole worm looks like a whiplash and its handle. Mature whipworms are 1½ to 2 inches long.

Life Cycle: It is one of the simplest life cycles known. Mature females lay eggs in the lumen of the cecum or large intestine. Worm eggs pass from the body in manure (Fig. 7) and under favorable conditions of moisture and temperature, develop to form infective larvae in 21 days.

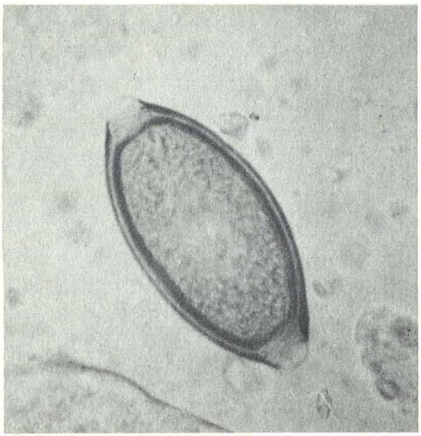

Fig. 7—Whipworm eggs may remain alive in the soil for 6 years or longer.

Upon being swallowed by a pig, the young larvae burrow into the mucosa of the large intestine and cecum. Within a few days, the young worms emerge, attach to the lining of the cecum or large intestine and grow to maturity. The prepatent period (from egg to egg) is 70–90 days.

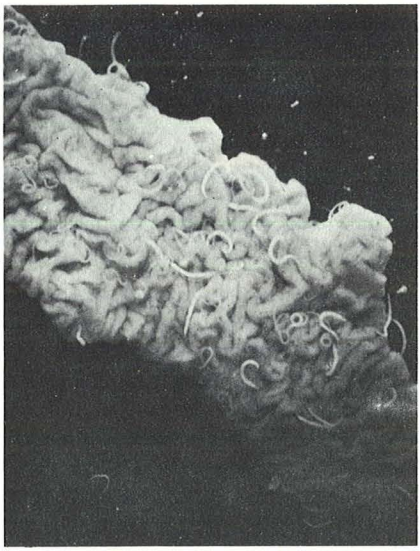

Fig. 8—Whipworms attached to the lining of the large intestine.

Clinical Signs: Whipworms attach to the lining of the cecum or large intestine of the pig where they obtain nourishment from body fluids (Fig. 8). They may cause considerable inflammation and irritation. Young pigs which show signs of enteritis should be examined for the presence of whipworms before prescribing therapy. In so doing,

keep in mind that sexually immature worms may be causing the damage, in which instance worm eggs may not be present in the feces.

Diagnosis: It is made by demonstrating worm eggs in the feces, or by recovery and identification of worms at necropsy.

Treatment: Until the recent development of organic phosphates as wormers, a suitable drug for whipworm treatment in pigs was not available. Atgard V is the drug of choice.

Lungworms

Three species of lungworms are considered important: *Metastrongylus apri, Metastrongylus salmi* and *Metastrongylus pudenodtectus.* Lungworms are thread-like, white worms which may reach 2½ inches in length, although some are considerably longer.

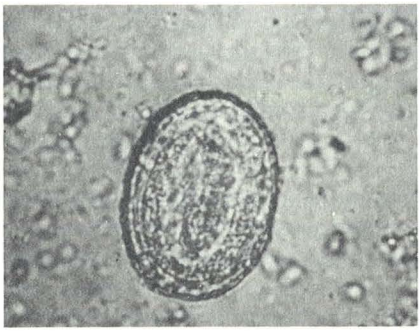

Fig. 9—Lungworm egg containing larva.

Life Cycle: Female lungworms live in air passages in the lungs. Here they produce large numbers of thick-shelled eggs, which the infected pig coughs up, swallows and passes in manure (Fig. 9). Various species of earthworms swallow the eggs, which hatch in the earthworm's intestine (Fig. 10). The larvae penetrate the walls of the esophagus, crop, gizzard and intestine of the earthworm. A single earthworm may harbor 2,000 lungworm larvae (Fig. 11). The larvae develop and become infective to pigs in three or four weeks.

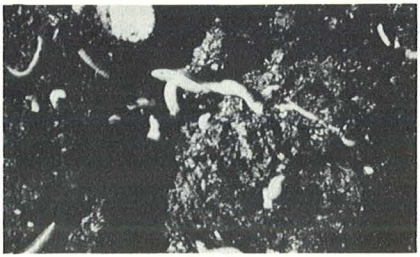

Fig. 10—Various species of earthworms are the intermediate host for swine lungworms.

Pigs become infected by eating earthworms which harbor the infective larvae. Lungworm larvae penetrate the pig's intestinal wall and are carried by the lymphatic and circulatory systems to the lungs. Here they burrow through the walls of the capillaries into the alveoli, become localized in the bronchioles, complete their development and mate (Fig. 12). The females produce eggs about 33 days after the pig ingests the infective larvae.

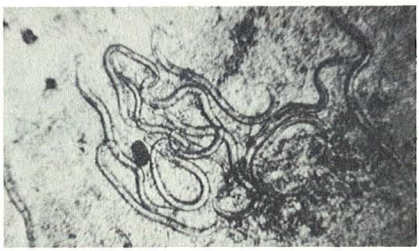

Fig. 11—Lungworm larvae from an infected earthworm.

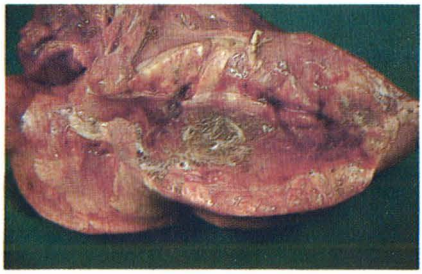

Fig. 12—Lungworms in the bronchioles of a pig 21 days after receiving an oral dose of infective lungworm larvae.

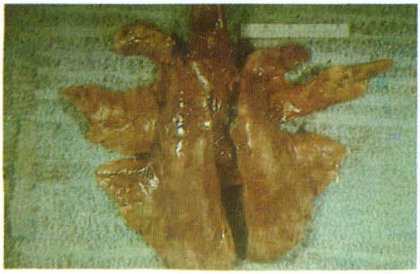

Fig. 13—Lungs of a pig 24 days after receiving an oral dose of 7,000 infective lungworm larvae.

Clinical Signs: Signs from lungworm infection arise from irritation and obstruction of air passages by adult worms and presence of larvae in the alveoli and lung tissue. The most consistent clinical sign is abnormal frequency of respiration. Rapid shallow breathing is characteristic of either light or heavy infection. Affected animals usually develop a loose, husky cough derived from the irritation and excessive mucus formation. There is an increased nasal discharge.

Hemorrhages are observed on the surface of the pig's lungs during early stages of lungworm invasion. Constant irritation by lungworms can bring about consolidation of lung tissue around sites occupied by worms. Tips of lungs become grayish or whitish and very hard in some cases (Fig. 13).

Lungworm infection may be the direct cause of verminous pneumonia or a predisposing cause of viral or bacterial pneumonia. In swine, lungworm larvae may serve as actual vectors of influenza virus.

Pigs infected with lungworms tend to go off feed, become unthrifty and fail to grow normally.

Diagnosis: It is made by isolation of eggs or larvae from feces passed or by demonstrating larvae in nasal secretions. Frothy mucus may be found at necropsy. When it is collected in a dish containing water and examined microscopically, the worms are easily observed.

Examination of feces or nasal secretions for larvae or eggs is not always a satisfactory method of diagnosis. A positive result is helpful but when negative the result is of little significance. In such instances, diagnosis is dependent largely on clinical signs, history of the herd and postmortem findings.

Treatment and Control: An effective wormer for removing lungworms from swine is not available.

Infected pigs should be removed from lots on which they acquired lungworms and put in dry, clean pens that have slatted or concrete floors. They may be placed on temporary pastures that have not been used for pigs for several years to insure against further infection from eating infected earthworms. Sick pigs kept in isolation should be supplied with nutritious feed, safe drinking water and good bedding.

Lungworm infection can be prevented by keeping pigs in lots where they cannot come in contact with earthworms. Earthworms thrive in old hog lots in which manure and litter have accumulated, or on permanent pastures and in low fields that receive drainage from higher ground. Farmers who avoid grazing swine on such areas will do much to control lungworm infection.

Anthelmintics for Swine

When selecting a wormer for swine, the following factors should be considered: Efficacy of compound, spectrum of activity, mode of administration, margin of safety and cost of treatment.

The efficacy of the wormer will determine the success or failure of the operation. It is worthless to administer a product that does not kill or remove worms.

The spectrum of anthelmintic activity determines the number of different species affected by the wormer. Certain swine anthelmintic drugs are highly effective against only one species. If the herd problem involves only one species of parasite, then the product is worthy of consideration. However, if several different species of parasites are present in the herd, then a wormer that will effectively remove as many species as possible should be used.

Early anthelmintic drugs required administration directly to the individual pig. Cost of wormer and labor involved in treating pigs individually restricts control programs based on standards of present day swine production.

The wormer must have a wide margin of safety. Toxicity must be low enough that dosing can be tolerated at levels many times above the suggested level of treatment. Recommended doses should be safe for young, old or pregnant females and special precautions should not be required for administration.

Cost of medication is an important consideration in selecting an anthelmintic drug. The profit-minded swine producer must use modern production methods to live within ever-narrowing profit margins. Better swine, better rations, growth-stimulating feed additives and mechanization all help to produce more pork with less feed.

However, swine parasites also thrive under these up-to-date production practices. Swine infected with worms require more feed to produce a pound of gain.

Piperazines

In 1954, two piperazine compounds were brought to the United States from England. The two piperazines were introduced primarily as ascaricides but the two drugs also exhibited activity against other parasites of swine, particularly nodular worms. Piperazines are the most popular swine anthelmintic drugs at this time.

Mode of Action: Piperazines are not designed as worm killers. The drugs paralyze the ascarids and the live worms are expelled from the pig.

Mode of Administration: The effective dose is 50 mg. piperazine base/lb. body weight regardless of the piperazine used. Because both

soluble and insoluble preparations are available, administration of these drugs does not involve extra labor; formulations have been administered effectively in drinking water and mixed in the feed.

Safety: The most outstanding feature of piperazine is its great margin of safety. The effective dose is much lower than the toxic dose. If administered properly, piperazine can be safely given to pregnant sows within one month of farrowing.

Hygromycin B

Hygromycin B, a fermentation product of *Streptomyces hygroscopicus,* is an antibiotic that has activity against ascarids, whipworms and nodular worms from swine.

Mode of Action: The initial action of hygromycin against internal parasites evidently is directed at the capacity of the female worm to produce worm eggs. The drug apparently is fatal to the worms but its action seems to be a cumulative one. Rapid expulsion of mature ascarids, so common following piperazine therapy, is not characteristic of hygromycin.

Mode of Administration: Ease of administering hygromycin is its greatest advantage. It is added to a complete feed or to protein supplement. When administered as a farm-mixed supplement, care should be used since 6,000 units/lb. is near borderline for effectiveness and in a farm-mixed ration this could easily be reduced.

Safety: Hygromycin B has a wide margin of safety. But, since it is a streptomycin-like substance, it also has some toxic effects. The incidence of deafness increases as pigs are left on medication for long periods. For this reason it is recommended that medication be removed after the pigs reach 125 lbs. This allows for recovery of some of the hearing damage produced early in treatment.

Organic Phosphates

Organic phosphates are the newest group of anthelmintic drugs. In tests throughout the country, excellent activity has been found against a broad spectrum of worms. Until the recent development of organic phosphates for worming of pigs, a suitable drug for treatment of whipworm infection was not available. It is interesting that organic phosphates as anthelmintic drugs are derived from insecticides.

Mode of Action: Worms expelled from pigs following treatment with organic phosphates are dead. The cholinesterase levels of the worms are suppressed sufficiently to result in the death of the parasites. Organic phosphates are recommended for the removal of ascarids, whipworms and nodular worms.

Mode of Administration: Mix the wormer into a meal-type ration shortly before use. Do not store the medicated feed as prolonged exposure lowers the anthelmintic efficiency. Preconditioning pigs by withdrawing the feed for 24 hours is neither necessary nor recommended. Post treatment purging is not required.

Safety: Characteristically, the organic phosphates have a lesser mar-



Fig. 14—Keep the baby pig away from worm eggs. Scrub the sow with tamed iodine before farrowing. Farrow in a cleaned house. Move the sow and baby pigs to a cleaned slab or newly tilled pasture.

gin of safety in the host than other swine anthelmintic drugs. The primary action of organic phosphates in the pig is on the nervous system where it depresses the enzyme cholinesterase. Swine showing signs of diarrhea or scours such as that caused by bacterial or viral enteritis, or by certain feeds such as alfalfa should not be wormed until these signs subside or are brought under control by proper therapy.

The information given herein is for educational purposes only. Reference to commercial products or trade names is made with the understanding that no discrimination is intended and no endorsement by the Cooperative Extension Service is implied.

BEFORE USING
ANY WORMER

STOP

READ THE LABEL