

September 2000

Intestinal lesions caused by a strain of *Chlamydia suis* in weanling pigs infected at 21 days of age

Douglas G. Rogers

University of Nebraska - Lincoln, drogers1@unl.edu

Arthur A. Andersen

National Animal Disease Center, USDA, ARS, Ames, IA

Follow this and additional works at: <http://digitalcommons.unl.edu/vetscipapers>



Part of the [Veterinary Medicine Commons](#)

Rogers, Douglas G. and Andersen, Arthur A., "Intestinal lesions caused by a strain of *Chlamydia suis* in weanling pigs infected at 21 days of age" (2000). *Papers in Veterinary and Biomedical Science*. 35.

<http://digitalcommons.unl.edu/vetscipapers/35>

This Article is brought to you for free and open access by the Veterinary and Biomedical Sciences, Department of at DigitalCommons@University of Nebraska - Lincoln. It has been accepted for inclusion in Papers in Veterinary and Biomedical Science by an authorized administrator of DigitalCommons@University of Nebraska - Lincoln.

Intestinal lesions caused by a strain of *Chlamydia suis* in weanling pigs infected at 21 days of age

Douglas G. Rogers, Arthur A. Andersen

Abstract. The objective of this study was to determine whether a strain of *Chlamydia suis* shown previously to be an intestinal pathogen in gnotobiotic piglets could cause diarrhea and intestinal lesions in young weanling pigs. Pigs from 2 sows were randomly assigned to 2 groups. Group 1 included 13 pigs that were weaned at 24 hours of age and then housed in isolator units and fed milk replacer and unmedicated starter ration. Group 2 included 8 pigs that nursed their respective sows, consumed unmedicated starter ration, and were weaned at 21 days of age. Ten pigs in group 1 and 6 pigs in group 2 were inoculated orally with 4×10^8 inclusion-forming units of *C. suis* strain R27 at 21 days of age. Control pigs were inoculated with sham inoculum. The pigs were necropsied 5–14 days postinoculation (DPI). None of the *Chlamydia*-infected pigs developed diarrhea. Villus atrophy was seen histologically in sections of ileum from *Chlamydia*-infected pigs in both groups 5 and 7 days DPI. Lymphangitis and multiple lymphohistiocytic and neutrophilic aggregates were seen in the submucosa, tunica muscularis, and serosa of the distal jejunum, ileum, and colon from *Chlamydia*-infected pigs in both groups 5–14 DPI. Immunostaining of sections of distal jejunum, ileum, and colon from infected pigs revealed chlamydial antigen in intestinal epithelium and in foci of lymphangitis/inflammation. The results indicated that *C. suis* strain R27 can cause intestinal lesions in young weanling pigs, and the lesions are similar to those seen in gnotobiotic piglets. The results also indicated that strain R27 causes asymptomatic intestinal infections in young weanling pigs, at least under the conditions of this study.

Intestinal chlamydial infections are common in swine,^{10,16,17} and the prevalence of these infections increases after pigs are 3–4 weeks of age.^{10,17} A number of chlamydial strains have now been isolated from the intestines of swine.^{4–6,12} Virtually all pigs have serologic titers to 1 or more of these strains by 8 weeks of age (Anderson et al., unpublished data). Swine strains analyzed thus far are phylogenetically related to human *Chlamydia trachomatis* strains, but they can be differentiated by genetic analysis.⁴ Recent revisions in chlamydial taxonomy have placed the swine strains in the new species *Chlamydia suis*.⁴

Although chlamydiae have been isolated from or detected in the intestines of diarrheic swine,^{9,10,17} the results of several field surveys suggest that most intestinal chlamydial infections are asymptomatic.^{10,16,17} The objective of the present study was to determine whether a chlamydial strain originally isolated from diarrheic nursery pigs could cause intestinal lesions and diarrhea in young weanling pigs. This chlamydial strain has been previously shown to be an intestinal pathogen in gnotobiotic piglets.¹¹

Materials and methods

Isolation of chlamydiae. Fecal swab and intestinal specimens collected at necropsy from 2 6-wk-old diarrheic pigs

were processed for the isolation of chlamydiae as previously described.^{13,15} Chlamydial isolates were analyzed by polymerase chain reaction (PCR) amplification of the major outer membrane protein genome using the primers and basic techniques as reported previously.² The PCR product was verified by electrophoresis in 1.5% agarose. The product was then digested with the *Alu* I restriction endonuclease for restriction fragment length polymorphism analysis. Resulting fragments were electrophoresed on a 4% low-melting-point agarose gel and stained with ethidium bromide. One of the 2 distinct chlamydial strains isolated was designated R27.

Chlamydial inoculum. *Chlamydia suis* strain R27 was grown in confluent Vero cell monolayers and harvested as previously described.¹³ Chlamydiae were concentrated approximately 10-fold by pelleting in a centrifuge and resuspending in sucrose-phosphate-glutamine buffer.¹⁵ The inoculum was stored in ampules at -70 C. The dosage of inoculum was determined to be approximately 10^{10} inclusion-forming units (IFU)/ml by titration in 24-hr Vero cell monolayers grown in 96-well multiwell dishes. Immediately prior to the inoculation of pigs, frozen stock inoculum (10^{10} IFU/ml) was allowed to thaw, and serial dilutions were made in sterile phosphate-buffered saline (PBS). The final dosage of diluted inoculum was approximately 4×10^8 IFU/ml. One milliliter of diluted inoculum was then added to 4 ml of sterile PBS, and this solution was used to inoculate pigs. Sham inoculum was prepared in an identical manner from uninfected cell culture lysates.

Sows. Two multiparous pregnant sows at 110 days of gestation were obtained from a private source. The sows were determined to be seronegative for pseudorabies and porcine reproductive and respiratory syndrome viruses immediately

From the Veterinary Diagnostic Center, Department of Veterinary and Biomedical Sciences, University of Nebraska, Lincoln, NE 68583-0907 (Rogers), and the National Animal Disease Center, USDA, ARS, Ames, IA 50010 (Andersen).

Received for publication April 6, 1999.

prior to transfer to the University of Nebraska–Lincoln. The sows were housed in standard farrowing facilities that had been scrubbed and rinsed with dilute chlorhexidine^a solution and subsequently sealed and fumigated for 24 hr with formaldehyde gas.¹⁴ Serum for the detection of chlamydial antibodies¹ was collected from each sow prior to farrowing. Vaginal and fecal swab specimens were collected from each sow at farrowing and processed for the isolation of chlamydiae as previously described.¹³

Pigs and experimental design. Twenty-one newborn pigs were identified by ear tags, and each pig was given 200 mg of iron dextran intramuscularly after they had nursed their respective sows for 24 hr. The needle teeth of each pig also were clipped at that time.

Thirteen randomly selected pigs designated as group 1 were weaned from their respective sows after they had nursed for 24 hr. The pigs were scrubbed with dilute chlorhexidine^a solution and dried.¹⁴ They were then placed into stainless steel isolator units covered with flexible plastic where they were housed for the duration of the study. The pigs were fed sterile milk replacer^b throughout the study, and they were exposed to an unmedicated pelleted starter ration at 10 days of age. Fecal swab specimens were collected from each pig at 7, 14, and 21 days of age and processed for the isolation of chlamydiae as reported earlier.¹³

The remaining 8 pigs, designated as group 2, were allowed to nurse their respective sows until they were 21 days of age. While nursing, the pigs had access to nipple-type waterers, and they were allowed access ad libitum to an unmedicated pelleted starter ration at 10 days of age. Fecal swab specimens were collected from each pig at 7, 14, and 21 days of age and processed for the isolation of chlamydiae as previously described.¹³ The pigs were weaned onto raised decks with wire mesh flooring when they were 21 days of age. Once weaned, the pigs had access to nipple-type waterers, and they were fed an unmedicated pelleted starter ration.

Pig serology and inoculation. Serum for the detection of chlamydial antibodies¹ was collected from each group-1 and group-2 pig just prior to inoculation at 21 days of age. Using a plastic syringe, 10 group-1 pigs and 6 group-2 pigs were then inoculated orally with strain R27 (4×10^8 IFU). Three group-1 pigs and 2 group-2 pigs received sham inoculum in an identical manner. Sham-infected group-1 pigs were housed together in a single isolator unit. Sham-infected group-2 pigs were housed separately from the *Chlamydia*-infected group-2 pigs.

Necropsy and histopathology. Pigs were monitored for diarrhea, dehydration, and lethargy 3 times daily. Rectal temperatures were recorded just prior to necropsy. Necropsies were done immediately after euthanasia.

Tissue specimens from the following anatomic sites were collected from each pig for histopathology (number of samples/site): duodenum (2), proximal jejunum (8), midjejunum (8), distal jejunum (8), ileum (8), cecum and proximal spiral colon (4), and distal spiral colon (4). Specimens were fixed in neutral-buffered 10% formalin, routinely processed, embedded in paraffin, sectioned at 4 μ m, stained with hematoxylin and eosin (HE), and examined by light microscopy.

Reisolation of chlamydiae, bacteriology, virology, and

parasitology. Fecal swab specimens and specimens of duodenum, jejunum, ileum, and spiral colon from all pigs were processed for the isolation of chlamydiae as previously described.¹³ Specimens of jejunum, ileum, and spiral colon from all pigs were processed for aerobic and anaerobic^c bacteriologic culture.¹³ Specimens of jejunum and ileum from all pigs were examined for rotavirus (RV) and transmissible gastroenteritis virus (TGEV) by fluorescent antibody techniques. Feces from all pigs were examined for viruses by negative contrast electron microscopy and for coccidial oocysts by flotation.

Immunohistochemistry. After histologic examination, 4–8 paraffin-embedded specimens each of distal jejunum, ileum, and cecum/colon from each principal pig were processed for immunohistochemistry. Two specimens from each of these anatomic sites were processed from each of the respective age-matched, sham-infected control pigs. Sections were cut at 4 μ m and attached to glass microslides that had been precoated with poly-L-lysine.^d After deparaffinization and rehydration, sections were washed 3 times in buffer and then stained using a labeled streptavidin–biotin (LSAB) alkaline phosphatase technique. The staining procedure was done with an automated immunostainer^e and used the washing buffer and rinsing times recommended by the manufacturer. The automated procedure was done as follows: 0.05% protease^f digestion (10 min), rinse, blocking antibody (10 min), primary polyclonal (rabbit origin) anti-*Chlamydia* antibody¹³ diluted 1:1,000 (30 min), rinse, biotinylated secondary antibody^g (10 min), rinse, streptavidin–alkaline phosphatase^g (10 min), and substrate–chromagen solution^h (up to 30 min). Performance controls incorporated into each staining procedure included the substitution of an irrelevant antibody for the primary antibody in the staining procedure (serum control), the staining of sections of gnotobiotic piglet lung that had large numbers of chlamydiae (positive tissue control), and the staining of counterpart tissue specimens from age-matched, sham-infected pigs (negative tissue control). After immunostaining was completed, sections were placed in an automated stainerⁱ and stained with hematoxylin^j (5.5 min), rinsed, clarified^j (1.5 min), rinsed, exposed to a bluing reagent^j (2 min), dehydrated in graded alcohols,^j and cleared in xylene. Coverslips were mounted with water-insoluble medium, and sections were examined by light microscopy.

Results

Both sows were seropositive for chlamydial antibodies prior to farrowing, and all pigs were seropositive for chlamydial antibodies prior to inoculation. Chlamydiae were not isolated from vaginal or fecal swab specimens collected from the sows at farrowing, and they were not isolated from fecal swab specimens collected from the pigs prior to inoculation. All pigs had started consuming unmedicated starter ration by 15 days of age.

Clinical signs and necropsy findings. The necropsy schedule is shown in Table 1. None of the *Chlamydia*-infected or sham-infected pigs exhibited clinical symptoms during the study. Rectal temperatures of the

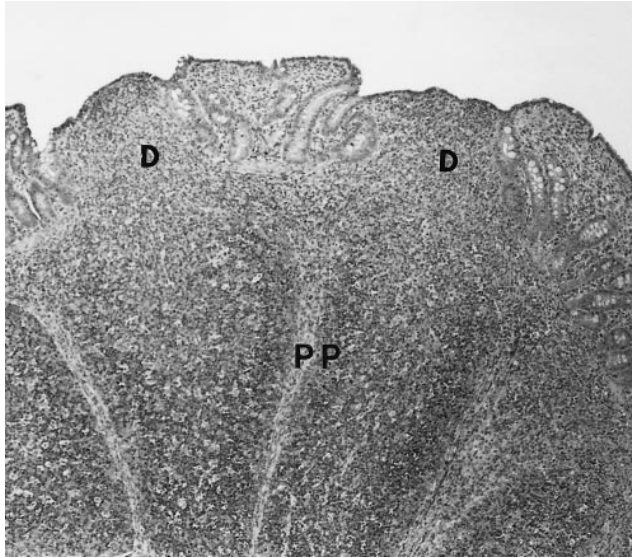


Figure 1. Ileum from pig inoculated with *C. suis* strain R27; 7 days postinoculation. Note atrophy of villi and domes (D) overlying Peyer's patches (PP). HE.

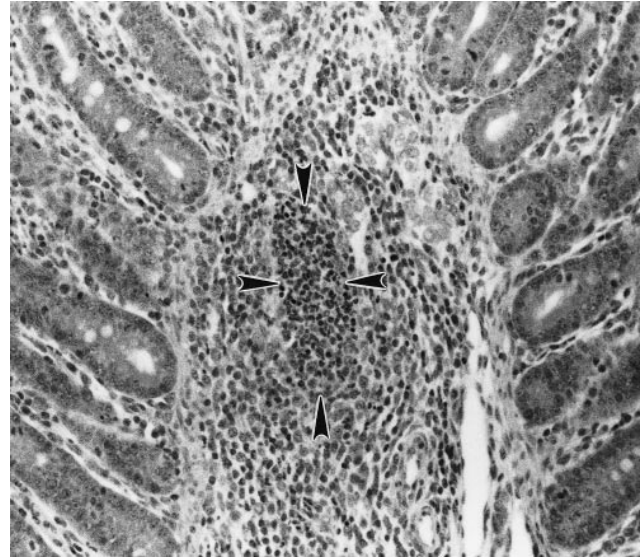


Figure 2. Ileum from pig inoculated with *C. suis* strain R27; 7 days postinoculation. A cluster of predominantly neutrophils in the submucosa (arrowheads) is surrounded by mixed inflammatory cells. HE.

Chlamydia-infected pigs did not differ from those of the sham-infected pigs.

Chyle was absent or had a patchy distribution in mesenteric lymphatics draining the ilea of *Chlamydia*-infected pigs necropsied 5 and 7 days postinoculation (DPI). Cecal contents from these pigs had watery brown or yellow-brown contents, but contents became progressively formed and solid in the spiral colons and rectums.

There were no gross lesions in the *Chlamydia*-infected pigs necropsied 10–14 DPI or in any of the sham-infected pigs.

Histopathology. There were no histologic lesions in sections of intestine from the sham-infected pigs. Ileal sections from *Chlamydia*-infected pigs in both groups necropsied 5 and 7 DPI were characterized by moderate multifocal to diffuse villus atrophy (Fig. 1). Epithelium lining blunted, atrophic villi were attenuated or low columnar to cuboidal. Scattered villi had dilated lacteals, and small to moderate numbers of neutrophils had infiltrated the villus lamina propria. Crypts had increased numbers of mitotic figures and occasionally were filled with neutrophils. Villus atrophy or other villus lesions were not seen in *Chlamydia*-infected pigs necropsied 10–14 DPI.

Chlamydia-infected pigs consistently had lymphangitis, perilymphangitis, and discrete, multifocal lymphohistiocytic aggregates in the submucosa, serosa, and occasionally in the tunica muscularis of the distal jejunum, ileum, cecum, and spiral colon. These lesions also were present in the midjejunum from several pigs. Foci of inflammatory cell infiltrates in infected pigs necropsied 5–10 DPI were generally characterized by clusters of predominantly neutrophils surrounded by

macrophages, lymphocytes, plasma cells, and occasional eosinophils (Fig. 2). These inflammatory lesions were mild (Fig. 2) to severe (Fig. 3) and extended from the submucosa through the tunica muscularis and into the serosa in sections of distal jejunum and ileum (Fig. 3) from several pigs. Mild to severe lymphohistiocytic to neutrophilic-lymphohistiocytic lymphangitis and perilymphangitis were present in infected pigs necropsied 5–10 DPI (Fig. 4). Lymphangitis and perilym-

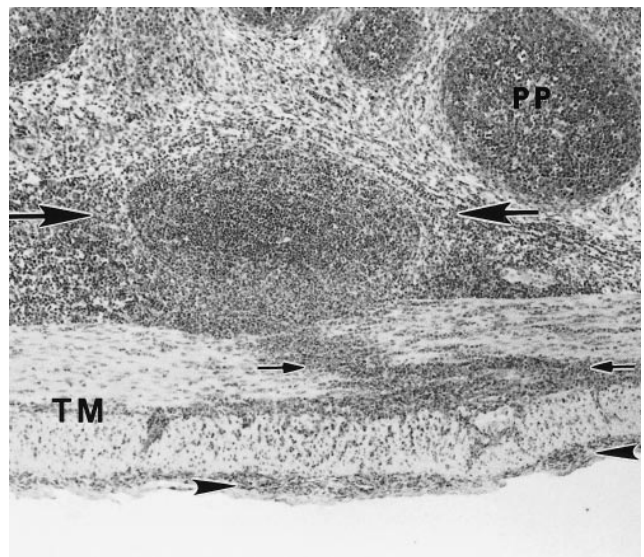


Figure 3. Ileum from pig inoculated with *C. suis* strain R27; 7 days postinoculation. Lymphohistiocytic and neutrophilic aggregates in the submucosa (large arrows). Inflammatory cells have infiltrated into the subjacent tunica muscularis (TM; small arrows) and serosa (arrowheads). Peyer's patch (PP). HE.

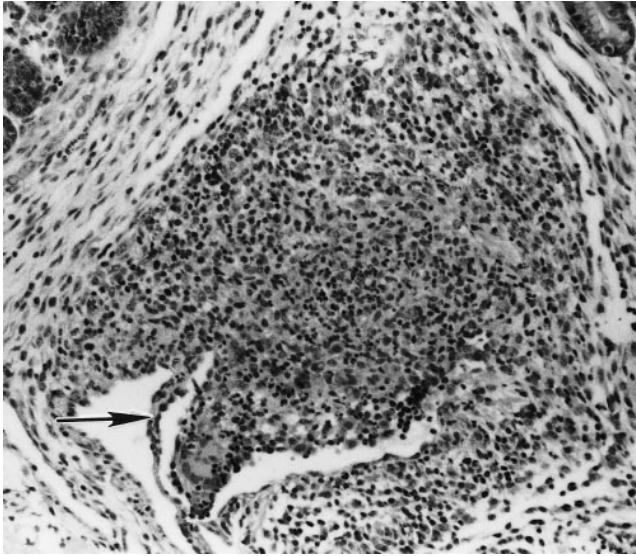


Figure 4. Ileum from pig inoculated with *C. suis* strain R27; 10 days postinoculation. Severe lymphangitis and perilymphangitis in the submucosa. Note valve of lymph vessel (arrow). HE.

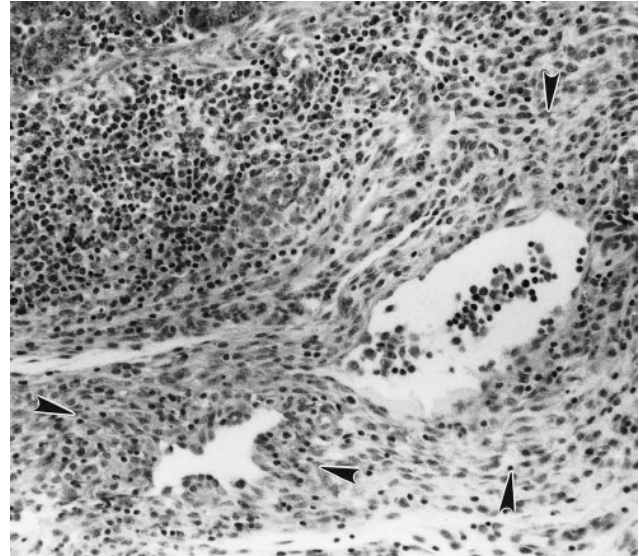


Figure 5. Spiral colon from pig inoculated with *C. suis* strain R27; 14 days postinoculation. Perilymphatic fibrosis (arrowheads). HE.

phangitis were lymphohistiocytic and mild in infected pigs necropsied 12 and 14 DPI, and perilymphatic fibrosis was occasionally seen in these pigs (Fig. 5).

Intracellular structures consistent with chlamydiae were rarely seen in intestinal sections from the infected pigs, regardless of when they were necropsied. When present, these structures appeared as finely granular basophilic material or as barely discernible coccobacilli in cytoplasmic vacuoles in villus enterocytes (Fig. 6) and in superficial cecal/colonic epithelial cells.

Immunohistochemistry. Immunostaining of sections of distal jejunum and ileum from *Chlamydia*-infected pigs necropsied 5 and 7 DPI revealed a small amount of chlamydial antigen in villus enterocytes, in villus lamina propria, in foci of lymphangitis and perilymphangitis, and in foci of inflammation in the submucosa (Fig. 7) and serosa. Small amounts of chlamydial antigen with a similar distribution were seen in the distal jejunum and ileum from infected pigs necropsied 10–14 DPI, but repeated attempts at immunostaining were occasionally required to find antigen. Small to moderate amounts of chlamydial antigen were consistently seen in superficial epithelial cells (Fig. 8) and lamina propria of the ceca and spiral colons from infected pigs necropsied throughout the study. Small amounts of chlamydial antigen were seen in foci of lymphangitis and perilymphangitis and in foci of inflammation in the submucosa and serosa at these sites in infected pigs necropsied 5–10 DPI. However, repeated attempts at immunostaining were occasionally required to find antigen. Chlamydial antigen was not detected in intestinal sections from the sham-infected pigs.

Microbiology and parasitology. Chlamydiae were reisolated from fecal swab specimens and from specimens of ileum and spiral colon from all principal pigs, but they were not isolated from specimens from the sham-infected pigs.

Escherichia coli was isolated from intestinal specimens from all principal and sham-infected pigs; *Bacillus* sp., *Klebsiella pneumoniae*, and coagulase-neg-

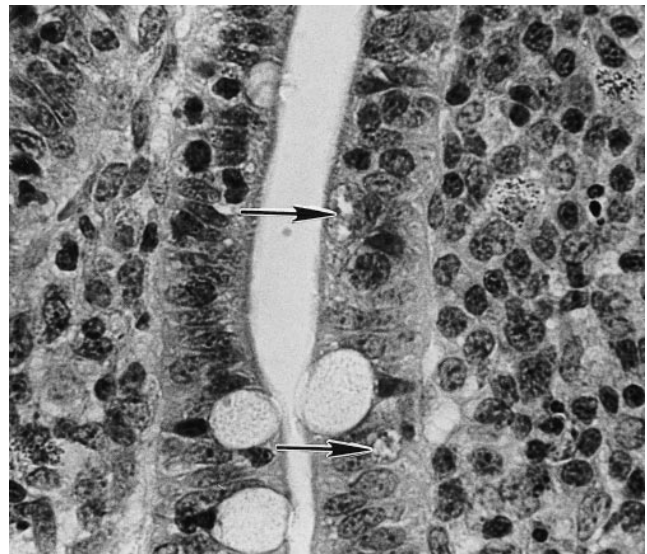


Figure 6. Ileum from pig inoculated with *C. suis* strain R27; 7 days postinoculation. Barely discernible coccobacilli resembling chlamydiae are in cytoplasmic vacuoles in villus enterocytes (arrows). HE.

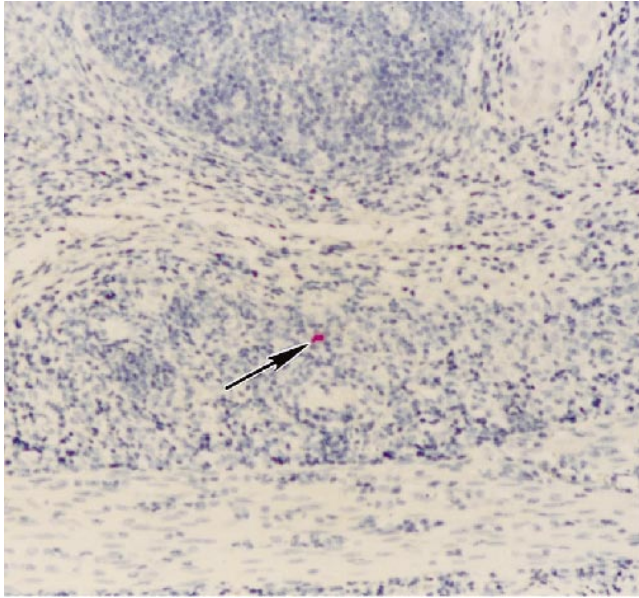


Figure 7. Ileum from pig inoculated with *C. suis* strain R27; 7 days postinoculation. Chlamydial antigen in a focus of inflammation in the submucosa (arrow). LSAB-alkaline phosphatase stain, hematoxylin counterstain.

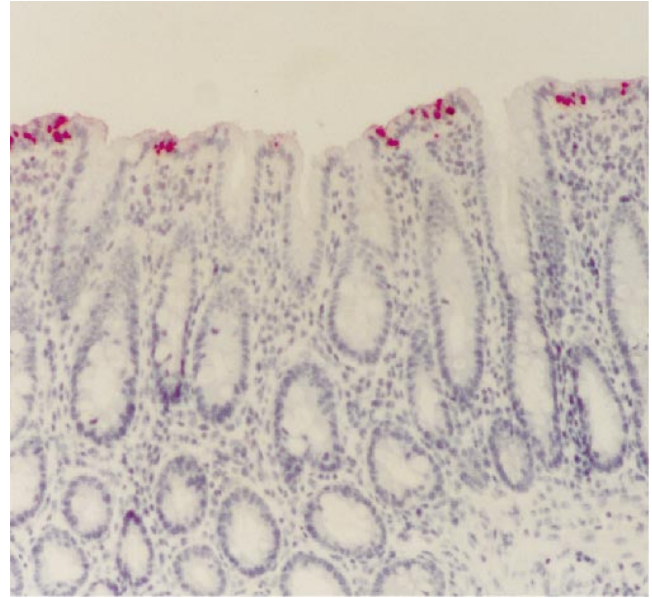


Figure 8. Spiral colon from pig inoculated with *C. suis* strain R27; 10 days postinoculation. Chlamydial antigen in superficial colonic epithelium. LSAB-alkaline phosphatase stain, hematoxylin counterstain.

ative staphylococci were isolated inconsistently. Salmonellae were not isolated from any of the pigs.

Fluorescent antibody tests for RV and TGEV done on jejunum and ileum from all pigs were negative, and viruses were not seen in feces by negative contrast electron microscopy. Small numbers of *Eimeria* sp. were seen in the feces of 1 group-2 sham-infected pig and 1 group-2 *Chlamydia*-infected pig necropsied 12 and 14 DPI, respectively.

Discussion

The results of this study indicate that *C. suis* strain R27 can cause intestinal lesions in weanling pigs infected at 21 days of age. The lesions are similar to those caused by strain R27 in gnotobiotic piglets except that necrosis of villi occurred in gnotobiotic piglets fed large numbers of chlamydiae.¹² Lymphangitis associated with the translocation of strain R27 across the intestine was a consistent lesion in both the gnotobiotic piglets and in the weanling pigs. The foci of inflammatory cells seen histologically in the submucosa, tunica muscularis, and serosa of the weanling pigs presumably was an extension of this process. Similar lesions have been reported in young calves experimentally infected with chlamydiae.³

The results also indicate that intestinal infections with strain R27 are asymptomatic, at least under the conditions of this study. Although chlamydiae have been associated with diarrhea and enteritis in nursing and young weanling pigs,⁹ some investigators have

speculated that a majority of intestinal chlamydial infections are asymptomatic.^{10,16,17} The ability of chlamydiae to cause diarrhea and/or intestinal lesions may depend on virulence of the strain, infectious dose of the strain, age and immunologic status of the pig,^{7,16} and presence of other intestinal pathogens.¹¹ Age of the pig when infected with *C. suis* is probably important because enterocyte replacement in the small intestine requires 7–10 days in neonatal pigs but requires only 2–4 days in pigs 3 weeks of age.⁸ In an experiment similar to that reported here, strain R27 did not cause intestinal lesions in weanling pigs inoculated at 5 weeks of age (Rogers et al., unpublished data), and this finding further supports the age-dependency concept. In addition, the dose of chlamydiae to which neonatal pigs are exposed is probably important because dose-related responses were seen when strain R27 was fed to gnotobiotic piglets.¹² In that study, strain R27 caused diarrhea and villus atrophy when 10^6 IFU were fed to the piglets, and it induced anorexia, recumbency, and necrosis of villi when 10^9 IFU were fed. Necrosis of villi has been reported in diarrheic nursing pigs naturally infected with chlamydiae.⁹

After nursing for 24 hours after farrowing, group-1 pigs were reared in isolator units to minimize exposure to any pathogens shed by the sow. The lesions caused by strain R27 in group-1 pigs were indistinguishable from those in group-2 pigs that had nursed their sows prior to inoculation. Two group-2 pigs became infected with *Eimeria* sp., but there were no clinical symptoms

or lesions in these pigs that indicated the coccidia were pathogenic. There also was no clinical or histologic evidence that the *E. coli* isolated from all pigs was pathogenic.

The degree to which humoral immunity protects pigs against intestinal chlamydial infections or contributes to the resolution of chlamydiae-induced lesions is unknown. The fact that pigs in both groups were seropositive for chlamydial antibodies prior to inoculation suggests that humoral immunity is not protective. Results of a recent survey indicate that chlamydial antibodies in swine sera are common, but they are strain specific (Andersen et al., unpublished data).

From a diagnostic perspective, the lesions seen in the young weanling pigs in this study are not pathognomonic for chlamydial enteritis. Villus atrophy in the ileum could indicate a viral etiology or coccidiosis, and arriving at a diagnosis of chlamydial enteritis could be difficult. However, the immunohistochemical detection of chlamydial antigen in foci of lymphangitis, a lesion consistent with *C. suis* infection, and failure to demonstrate the presence of other agents should be evidence that *C. suis* also caused villus atrophy. Only small amounts of chlamydial antigen were detected in ileal lesions from infected pigs in this study, and repeated immunostaining was occasionally required to detect it. Because chlamydial antigen was detected most consistently in sections of colon from the infected pigs, concurrent immunohistochemical evaluation of colon could aid in diagnosis when chlamydial antigen is not detected in ileal lesions and the presence of other agents cannot be demonstrated. Fluorescent antibody techniques might be employed in lieu of immunohistochemistry, but positive results would have to be interpreted in accordance with histologic findings and the presence or absence of other agents. Although many diagnostic laboratories do not routinely attempt chlamydial isolation from swine intestinal and/or fecal specimens, positive results would again have to be interpreted in accordance with histologic findings and the presence or absence of other agents.

The results of this study suggest that *C. suis* strain R27 by itself probably is not an economically significant intestinal pathogen in young weanling pigs. However, the fact that this strain can cause intestinal lesions that mimic those caused by other pathogens should be considered when examining sections histologically. There also is the possibility that strain R27 and other chlamydial strains could act in a synergistic fashion to exacerbate intestinal infections caused by more significant pathogens.¹¹

Acknowledgements

We thank Linda Hornung, Steve Tucker, Steve Christian, Monty Klintworth, Ginger Mills, Tina Green, and Mavis

Seelmeyer for assistance. This work was supported by funds from USDA Specific Cooperative Agreement 58-3630-4-125. This report is published as article 12576, Agricultural Research Division, Institute of Agriculture and Natural Resources, University of Nebraska-Lincoln.

Sources and manufacturers

- a. Nolvasan, Ft. Dodge Laboratories, Ft. Dodge, IA.
- b. SPF-Lac, Borden, Norfolk, VA.
- c. BBL GasPak, Becton Dickinson and Co., Cockeysville, MD.
- d. Sigma Diagnostics, St. Louis, MO.
- e. DAKO Autostainer, DAKO Corp., Carpinteria, CA.
- f. Protease XIV, Sigma Chemical Co., St. Louis, MO.
- g. DAKO LASB+ Kit, Alkaline Phosphatase, DAKO Corp., Carpinteria, CA.
- h. Vector Red Alkaline Phosphatase Substrate Kit J, Vector Laboratories, Burlingame, CA.
- i. Jung Autostainer XL, Leica Instruments, Nussloch, Germany.
- j. Richard-Allan Medical, Richland, MI.

References

1. Andersen AA: 1991, Serotyping of *Chlamydia psittaci* isolates using serovar-specific monoclonal antibodies with the immunofluorescence test. *J Clin Microbiol* 29:707-711.
2. Denamur F, Sayada C, Souriau A, et al.: 1991, Restriction pattern of the major outer-membrane protein gene provides evidence for a homogenous invasive group among ruminant isolates of *Chlamydia psittaci*. *J Gen Microbiol* 137:2525-2530.
3. Doughri AM, Young S, Storz J: 1974, Pathologic changes in intestinal chlamydial infection of newborn calves. *Am J Vet Res* 35:939-944.
4. Everett KDE, Bush RM, Andersen AA: 1999, Emended description of the order Chlamydiales, proposal of Parachlamydiaceae fam. nov. and Simkaniaceae fam. nov., each containing one monotypic genus, revised taxonomy of the family Chlamydiaceae with descriptions of five new species, and standards for the identification of organisms. *J Syst Bacteriol* 49:415-440.
5. Kaltenboeck B, Storz J: 1992, Biological properties and genetic analysis of the *omp A* locus in chlamydiae isolated from swine. *Am J Vet Res* 53:1482-1487.
6. Kölbl V: 1969, Untersuchungen über das vorkommen von myagawanellen beim schwein. *Wien Tierärztl Monatsschr* 56: 332-335.
7. Leonhard I, Wittenbrink MM, Bisping W: 1988, Nachweis von *Chlamydia psittaci* im kot von schweinen. *Berl Münch Tierärztl Wochenschr* 101:124-128.
8. Moon HW: 1971, Epithelial cell migration in the alimentary mucosa of the suckling pig. *Proc Soc Exp Biol Med* 137:1651.
9. Nietfeld JC, Janke BH, Leslis-Steen P, et al.: 1993, Small intestinal *Chlamydia* infection in piglets. *J Vet Diagn Invest* 5:114-117.
10. Nietfeld JC, Leslie-Steen P, Zeman DH, Nelson D: 1997, Prevalence of intestinal chlamydial infection in pigs in the Midwest, as determined by immunoperoxidase staining. *Am J Vet Res* 58: 260-264.
11. Pospischil A, Wood RL: 1987, Intestinal *Chlamydia* in pigs. *Vet Pathol* 24:568-570.
12. Rogers DG, Andersen AA: 1996, Intestinal lesions caused by two swine chlamydial isolates in gnotobiotic pigs. *J Vet Diagn Invest* 8:433-440.
13. Rogers DG, Andersen AA, Hunsaker BD: 1996, Lung and nasal lesions caused by a swine chlamydial isolate in gnotobiotic pigs. *J Vet Diagn Invest* 8:45-55.
14. Shaw DP, Morehouse LG, Solorzano RF: 1989, Experimental

- rotavirus infection in three-week-old pigs. Am J Vet Res 50: 1961–1965.
15. Spence WN, Johnson FWA: 1983, Simple transport medium for the isolation of *Chlamydia psittaci* from clinical material. Vet Rec 113:535–536.
 16. Szeredi L, Schiller I, Sydler T, et al.: 1996, Intestinal *Chlamydia* in finishing pigs. Vet Pathol 33:369–374.
 17. Zahn I, Szeredi L, Schiller I, et al.: 1995, Immunhistologischer nachweis von *Chlamydia psittaci/pecroum* and *C. trachomatis* im ferkel-darm. J Vet Med B 42:266–276.