

2005

A SURVEY OF INFECTIOUS DISEASES AND PARASITES IN WILD TURKEYS FROM NEBRASKA

David W. Oates

Nebraska Game and Parks Commission, doates@ngpc.state.ne.us

Eva A. Wallner-Pendleton

University of Nebraska-Lincoln

Ivan Kanev

University of Nebraska-Lincoln

Mauritz C. Sterner

University of Nebraska-Lincoln

Henry E. Cerny

University of Nebraska-Lincoln

See next page for additional authors

Follow this and additional works at: <http://digitalcommons.unl.edu/tnas>

 Part of the [Life Sciences Commons](#)

Oates, David W.; Wallner-Pendleton, Eva A.; Kanev, Ivan; Sterner, Mauritz C.; Cerny, Henry E.; Collins, Megan; Bischof, Richard; and Boyd, Ed D., "A SURVEY OF INFECTIOUS DISEASES AND PARASITES IN WILD TURKEYS FROM NEBRASKA" (2005).

Transactions of the Nebraska Academy of Sciences and Affiliated Societies. 45.

<http://digitalcommons.unl.edu/tnas/45>

This Article is brought to you for free and open access by the Nebraska Academy of Sciences at DigitalCommons@University of Nebraska - Lincoln. It has been accepted for inclusion in Transactions of the Nebraska Academy of Sciences and Affiliated Societies by an authorized administrator of DigitalCommons@University of Nebraska - Lincoln.

Authors

David W. Oates, Eva A. Wallner-Pendleton, Ivan Kanev, Mauritz C. Sterner, Henry E. Cerny, Megan Collins, Richard Bischof, and Ed D. Boyd

A SURVEY OF INFECTIOUS DISEASES AND PARASITES IN WILD TURKEYS FROM NEBRASKA

David W. Oates^{1,4}, Eva A. Wallner-Pendleton², Ivan Kanev³, Mauritz C. Sterner³, Henry E. Cerny²,
Megan Collins³, Richard Bischof¹, and Ed D. Boyd¹

¹Nebraska Game and Parks Commission
2200 N. 33rd St.
Lincoln, Nebraska 68503-0370

²Veterinary Diagnostic Center
University of Nebraska–Lincoln
Lincoln, Nebraska 68583-0907.

³Harold W. Manter Laboratory of Parasitology
Nebraska State Museum,
University of Nebraska–Lincoln
Lincoln, Nebraska, 68588-0514

⁴Corresponding author (e-mail:doates@ngpc.state.ne.us)

ABSTRACT

During the 1997-98 fall hunting season, samples from 154 Wild Turkeys were donated by hunters to the Nebraska Game and Parks Commission (NGPC) Genetic and Forensic Laboratory. Assistance was provided by the Veterinary Diagnostic Center, and the Harold W. Manter Laboratory of Parasitology, University of Nebraska, Lincoln, for this survey of infectious diseases and internal parasites. One hundred and thirteen sinus swabs were cultured for pathogenic bacteria, and fecal samples were examined for parasite ova and protozoa. One hundred and six gastrointestinal samples were examined for helminth parasites. Intestinal coccidiosis was present in 42 birds. *Salmonella* was isolated from fecal samples from four birds. *Mycobacterium avium* (avian tuberculosis) infection was suspected in one bird. No evidence of *Pasteurella multocida* (fowl cholera) or *Histomonas meleagridis* (blackhead) were seen. Thirty-three species of helminth parasites belonging to 4 taxa were identified: 13 species of Cestoda, 12 species of Nematoda, 7 species of Trematoda, and 1 species of Acanthocephala. Four helminths, not previously documented in North American Wild Turkeys, but known to exist in Europe, were identified in these birds.

† † †

Reintroduction and relocation of Wild Turkeys has occurred throughout much of the United States in the last fifty years, and due to these efforts, the Wild Turkey is well-established in Nebraska. Presently, trapping and relocation of Wild Turkeys occurs in areas

where their numbers are high and they are perceived to be a nuisance to local agriculture. However, relocation of wildlife, including turkeys, may have potential disease risks (Cunningham 1996, Davidson and Nettles 1992). Several infectious diseases such as histomoniasis, salmonellosis, mycoplasmosis, and helminths could easily be spread by moving birds from one region to another. Natural migrations also occur, as when birds move during the winter months in search of a better food source. These events could pose a health threat both to the local Wild Turkey populations and to the domestic turkeys raised in the state.

Disease surveys in Wild Turkeys have been performed in several regions of the United States (Davidson et al. 1985, Fritz et al. 1992, Gardiner and Wehr 1949, Hon et al. 1975, Hopkins et al. 1990, Maxfield et al. 1963, Rocke and Yuill 1987, Veatch et al. 1998). The purpose of this study was to access the health and parasite status in Wild Turkeys of Nebraska. Selected organ samples from hunter-harvested turkeys were screened for common bacterial, protozoan, and helminth infections.

METHODS AND MATERIALS

From November 1997 through January 1998, hunters purchasing turkey permits were given an instructional sheet in the permit envelopes asking them to

voluntarily save the head, neck, and gastrointestinal tracts, including livers, from harvested Wild Turkeys. The organs were kept refrigerated at 4°C until delivery to the Nebraska Game and Parks Commission, then transported to the Veterinary Diagnostic Center (University of Nebraska–Lincoln) for testing. The organs were first visually examined for abnormalities such as enlargement, discoloration, hemorrhages, or inflammatory foci.

Bacterial cultures were obtained aseptically from the infraorbital sinuses and intestinal tracts. The infraorbital sinuses were cultured aerobically for pathogenic bacteria using standard techniques (Carter et al. 1995). Briefly, the external surface of the skin overlying the infraorbital sinus was sterilized by searing with a flamed spatula. An opening into the sinus was then created with a sterile scalpel blade. A sterile culture transport swab was then inserted into the sinus opening and a sample taken by obtaining mucus from the mucosal surface. The swabs were streaked onto the surface of trypticase soy agar plates containing 5% sheep blood (blood agar) with a *Staphylococcus aureus* streak, Mackonkey's agar plates (MAC), and trypticase agar plates containing 5% hemolyzed sheep blood (chocolate agar). The plates were incubated at 37°C with 5% CO₂ for 24 hours, then examined for bacterial growth. Any colonies with typical morphology of avian respiratory pathogens were streaked on a new blood agar plate and identification was carried out using standard laboratory methods (Carter et al. 1995).

Fecal material from the ceca and rectum were collected and inoculated in tetrathionate enrichment broth for *Salmonella* identification at a 1:10 ratio of sample:broth and incubated at 37°C for 24 hours. A dry sterile swab was inserted into the broth and streaked onto *Salmonella* selective enrichment media plates [Hektoen enteric (HE) agar and xylose, lysine, and Tergitol (XLT-4) plates], which were incubated at 37°C for 24 hours. Suspect *Salmonella* colonies were inoculated in triple sugar iron (TSI) and lysine iron agar (LIA) slants. Isolates that had typical colony morphology of *Salmonella* and reactions in TSI slants of alkaline over acid H₂S production and reactions in LIA slants of alkaline over alkaline/no change with H₂S production and had a positive agglutination with *Salmonella* polyclonal antiserum were considered positive for *Salmonella*. All confirmed *Salmonella* isolates were checked for purity and then sent to the National Veterinary Services Laboratory in Ames, Iowa, for serotyping.

Fecal samples from the large intestine were collected for fecal flotation to detect parasite ova. One to two grams of fresh feces were mixed with 15 ml of a sucrose solution with a specific gravity of approximately 1.25 to 1.30. The sugar solution/feces mixture was

thoroughly combined, then strained through a previously sterilized tea strainer. The strained solution was drained into a centrifuge tube and centrifuged at 1500 r.p.m. for 10 minutes. The tube was then filled with additional sugar solution up to the top of the tube. A 22-mm cover slip was placed on top of the tube to be in contact with the sugar solution. The tube was left undisturbed for 15 minutes, allowing the parasite ova to rise to the solution surface. The cover slip was carefully removed and placed wet-side-down on top of a glass microscope slide. The slide was examined for ova under 100× magnification and intestinal parasite ova identification was performed using standard procedures (Foreyt 1990).

All organs were then opened to check for lesions and evidence of helminths. The gastrointestinal samples were placed in 10% neutral buffered formalin for further processing and helminth identification. One hundred and six turkey intestinal tracts that had been preserved in formalin were examined for helminth parasites. The remaining intestines were discarded because of advanced autolysis. Water was washed over the intestines to remove any excess preservative. The intestines were opened with scissors along their entire length. Next, a standard glass microscope slide was used to scrape the lining of the intestine to remove embedded parasites. Using a heavy stream of water, the scraped intestinal contents were first filtered through a large screen (350 µm) with mesh small enough to retain coarse debris. A second screen (150 µm) was placed under the first to catch all the parasites. Next, the contents were washed in a bowl filled with water. The helminths were allowed to settle to the bottom of the bowl. The unsettled particles and liquid were decanted. The procedure was repeated until the supernatant was relatively clear. The remaining contents were examined for helminths under a dissecting microscope. The parasites were separated into four major groups: cestodes, nematodes, trematodes, and acanthocephala. Each group was placed in its own vial containing AFA fixative (40 ml of 100% acetic acid, 60 ml of 10% formalin, 500 ml of 95% ethanol, and 400 ml of distilled water). After several hours, the parasites were removed and placed into a 70% alcohol and 2% glycerine solution until further examination.

For parasite identification, the specimens were stained in either hematoxylin or aceto-carmine using standard staining techniques and mounted on slides using Canada balsam. After light microscopic examination, individuals of each species were counted to obtain the total number of parasites and how many were found in each host. Specimens were entered into the parasite collection housed in the Harold W. Manter Laboratory of Parasitology (University of Nebraska–Lincoln, Lincoln, Nebraska, USA), accession numbers

HWML 15067–HWML 15193.

RESULTS

Samples from 154 Wild Turkeys harvested in 18 counties were collected. Because some submissions arrived too autolyzed to examine or some hunters did not include all requested organs, the number of tests performed (parasitology, bacteriology, fecal flotations) was less than the total number of bird specimens received.

One hundred and thirteen sinuses were cultured; none contained *Pasteurella multocida* (Fowl Cholera) or other aerobic pathogens. Of 97 intestinal cultures tested for *Salmonella*, 4 were positive. The isolated serotypes were *Salmonella oranienburg*, *S. anatum*, and *S. bredeney*; one *Salmonella* isolate could not be identified using serological typing. One liver had firm, white, nodules of various sizes throughout the organ. High numbers of minute acid-fast bacterial rods were seen on impression smears made from the liver, allowing a presumptive diagnosis of *Mycobacterium avium* (avian TB) infection. There was no visual evidence of *Histomonas meleagridis* (blackhead) in any of the livers or ceca.

One hundred and thirteen fecal flotation examinations were conducted. Forty-two (37%) were positive for coccidial oocysts. The oocysts were not determined to species. Three fecal samples contained double-operculated ova consistent with the nematode *Capillaria* spp. (Hurst et al. 1979).

All 106 turkey intestines examined were infected with helminths. Thirteen species of cestodes, twelve species of nematodes, seven species of trematodes and one species of Acanthocephala were recovered (Table 1).

DISCUSSION

Obtaining representative samples from wild bird populations for disease-survey purposes can be difficult in any field study. In several previous reports, samples from small numbers of live trapped birds were used (Hopkins et al. 1990, Roslien and Haugen 1970). Other studies, similar to this one, used carcass samples from hunter-killed birds (Maxfield et al. 1963, Prestwood et al. 1975). The advantage of using carcass samples obtained during hunting season is that large numbers of samples can be obtained from throughout the state. These organs originated from several areas of Nebraska; however, the majority came from the north central region (Fig. 1).

The disadvantages included difficulty in collecting

and preserving the samples for adequate testing. Autolysis, especially of the intestinal tract, can be considerable, even with available refrigeration. Since our survey started toward the end of turkey applications, only certain areas were still open to hunting, so these results are from only 18 counties. Only around 20% of Nebraska counties were included, but it should be representative and give us some insight to diseases and parasites in our Wild Turkeys.

Forty-two (37%) of the specimens contained coccidial oocysts, suggesting that this disease is widespread. Several species of coccidia infect both domestic and wild turkeys. Coccidiosis can cause abnormal weight loss in birds of all ages (Edgar 1986), although mortality seldom occurs after eight weeks of age. Infection with pathogenic coccidia species in young birds could potentially affect poult survival rate (Becker 1934, Kreier 1993).

Salmonella was found in four of the cultured intestines. *Salmonella* infection in Wild Turkeys has been previously described (Howerth 1985). Studies in domestic turkeys suggest a much higher prevalence (Irwin et al. 1994). This difference may be due to intensive hatching and rearing methods used by the commercial turkey industry. *Salmonella* infections can cause significant morbidity and mortality in young poults and can decrease hatchability of eggs. Improperly handled or prepared Wild Turkey meat could potentially become contaminated and cause food poisoning in humans.

Mycobacterium avium infection was suspected in one specimen. Avian tuberculosis has been reported in many species of birds including ducks, geese, chickens, turkeys, pigeons, cranes, pheasants, raptors, and wild passerines (Hinshaw et al. 1932, Singbeil et al. 1993, Svrcek et al. 1966). The disease was frequently reported in captive zoo birds (Montali et al. 1976). Infection usually occurs through ingestion of feces. The disease causes sporadic illness in older birds. Infection with *Mycobacterium avium* is rare in mammals with the exception of rabbits and swine. However, in both swine and cattle, exposure to avian tuberculosis may cause cross-reactions with the standard intradermal tuberculin skin test, which can lead to misinterpretation of that test.

Histomonas meleagridis (blackhead) was not visible on visual examination of the livers and ceca. Despite the identification of one of the principal vectors, *Heterakis gallinae* (the cecal worm), in several intestinal samples (Gibbs 1962, Lund et al. 1975) blackhead was not evident. Other studies (Hopkins et al. 1990, Maxfield et al. 1963) had reported the same findings.

Table 1. Helminths identified in Nebraska Wild Turkeys.

Parasite Name	No. of Turkeys infected	Total no. of parasites found	Maximum no. per bird
CESTODA			
1. <i>Choanotaenia infundibulum</i>	5	24	12
2. <i>Davainea meleagridis</i>	1	5	5
3. <i>Echinolepsis carioca</i>	8	18	7
4. <i>Fimbriaria fasciolaris</i>	2	2	1
5. <i>Microsomacanthus paracompressa</i> ¹	1	2	2
6. <i>Raillietina cestillus</i>	8	17	3
7. <i>Raillietina circumvallata</i>	4	7	2
8. <i>Raillietina echinobothrida</i>	3	7	3
9. <i>Raillietina ransomi</i>	1	2	2
10. <i>Raillietina tetragona</i>	16	37	15
11. <i>Raillietina williamsi</i>	4	6	2
12. <i>Sobolevicanthus gracilis</i>	6	9	2
13. Unidentified specimen	2	3	2
NEMATODA			
1. <i>Ascaridia dissimilis</i>	4	8	3
2. <i>Ascaridia galli</i>	5	7	2
3. <i>Capillaria bursata</i>	7	14	3
4. <i>Capillaria caudinflata</i>	5	8	2
5. <i>Capillaria obsignata</i>	3	8	3
6. <i>Eucoleus annulatus</i>	4	5	2
7. <i>Ganguleterakis dispar</i>	2	4	2
8. <i>Heterakis gallinarum</i>	10	24	3
9. <i>Syngamus trachea</i>	3	3	1
10. <i>Thominx phasiania</i> ¹	5	5	1
11. <i>Trichostrongylus tenuis</i>	5	24	7
TREMATODA			
1. <i>Echinoparyphium recurvatum</i>	3	196	108
2. <i>Echinoparyphium rubrum</i>	3	109	96
3. <i>Echinostoma revolutum</i> ¹	2	5	3
4. <i>Echinostoma trivolvis</i>	2	4	2
5. <i>Notocotylus attenuatus</i>	3	3	1
6. <i>Prosthogonimus cuneatus</i> ¹	2	3	2
7. <i>Prosthogonimus ovatus</i> ¹	1	1	1
ACANTHOCEPHALA			
1. <i>Mediorhynchus sp.</i>	3	3	1

¹European species never before reported in the USA from Wild Turkeys.

Blackhead has been well-documented in both domestic and wild turkeys (Hurst 1980) and has been diagnosed in previous years in Nebraska Wild Turkeys. For our samples the current incidence of this infection is zero, but blackhead incidence is unknown in Nebraska Wild Turkeys.

There was no evidence of *Pasteurella multocida* (fowl cholera) infection. Pasteurellosis occurred in

domestic turkeys, migrating waterfowl, and miscellaneous birds in Nebraska and other states (Faddoul et al. 1967, Gregg et al. 1974, Zinkl et al. 1975). In this study, the infraorbital sinus as it communicates with the nasal passages (a site believed to harbor the organism) was cultured. Fowl cholera was either uncommon in Wild Turkeys, or the incidence of asymptomatic carrier animals was rare because of high mortality rates in infected birds.

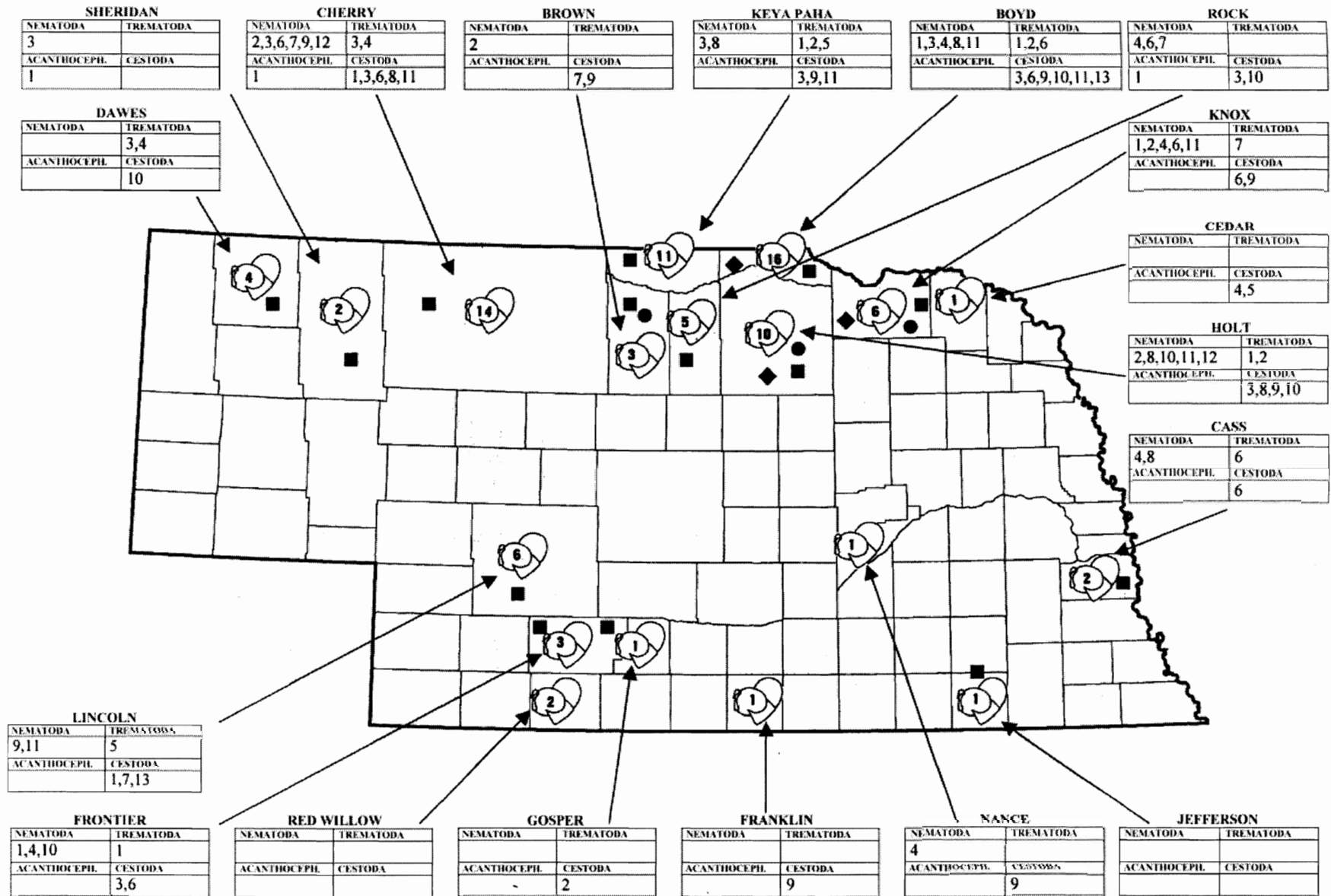


Figure 1. Map of Nebraska showing where turkey samples were obtained. Number inside turkey drawing indicates number of bird carcasses obtained from that county. The boxes surrounding the state, indicate the county and the parasites (the number assigned to them from Table 1.) found in that county. A black dot represents the finding of *Salmonella*. A black diamond represents the finding of *Capillaria* ova. A black square indicates the finding of coccidia.

Numerous studies have been conducted on the presence of parasites in Wild Turkey in the United States, and most helminths identified in Nebraska Wild Turkeys have been reported in previous studies. Two species of trematodes, *Prosthogonimus cuneatus* and *Echinostoma revolutum* (Fagasinski 1962, Kanev 1985), one cestode, *Microsomacanthus paracompressa* (Vassilev and Kamburov 1969) and one nematode, *Thominx phasianina*, (Vassilev and Kamburov 1965) are European species never reported in the United States (Table 1) in turkeys. Several reports have documented migration of European waterfowl and shorebirds into Canada and the United States (Ebbinge 1982, Ogilvie and Boyd 1975, Stegmann 1938, Yesou 1980, 1981). In connection with bird migration, Sorensen et al. (1997) described discovering larval stages of European trematodes in freshwater snails in Indiana for the first time. Based on these findings, it is certainly possible that these European helminth species may have been brought in by migratory birds from Europe.

The wide variety of parasites found in these turkeys is probably the result of their omnivorous food habits, including consumption of several species of insects, earthworms, snails, and other aquatic animals. These vertebrates serve as intermediate hosts for many of the aforementioned helminths. Internal parasites can negatively affect the health of turkeys in a variety of ways. In high numbers, they can rob the host of vital nutrients. Many cause damage and inflammation of the intestinal mucosa—*Davainea meleagridis*, *Railletina echinobothrida*, *Mediorhynchus* spp. (Morgan and Hawkins 1949). Several feed on blood (*Notocotylus attendus*, *Syngamus trachea*). *Syngamus trachea*, in high numbers, can also cause respiratory distress and asphyxiation (Levine 1980). Some helminths (*Heterakis gallinarum*) may predispose the host to secondary infections (Levine, 1980). Two parasites found in this study (*Prosthogonimus cuneatus*, *Prosthogonimus ovatus*) are found in the lower portion of the uterus and can mechanically block spermatozoa from reaching the ova in the upper oviduct, resulting in infertility (Morgan and Hawkins, 1949). Heavily parasitized birds may leave the nest unattended more frequently than healthy birds, which could result in nesting failure. This study was completed in this state to determine which parasites were present and whether they could potentially affect our future turkey population. More in-depth work is necessary to determine the long range effects due to parasitism in Wild Turkey populations throughout the United States.

ACKNOWLEDGMENTS

Funding for this project was obtained from the Nebraska Game and Parks Commission, Lincoln, Nebraska. The authors appreciate the assistance and use of facilities at the Department of Veterinary and Biomedical Sciences and the Manter Laboratory of Parasitology at the University of Nebraska—Lincoln, and thank these laboratories for their support of this project. We also appreciate the review by Ruth Wusk and Mace Hack and are grateful to the hunters who volunteered by donating carcass samples for this study.

LITERATURE CITED

- Becker, E. R. 1934. *Coccidia and Coccidiosis of Domesticated, Game and Laboratory Animals and of Man*. Ames, Iowa, Collegiate Press: 147 pp.
- Carter, G. R., M. M. Chengappa, and A. W. Roberts. 1995. *Essentials of Veterinary Microbiology*, 5th ed. Philadelphia, Lea and Febiger: 394 pp.
- Cunningham, A. A. 1996. Disease risks of wildlife translocation. *Conservation Biology* 10: 349–353.
- Davidson, W. R., and V. F. Nettles. 1992. Relocation of wildlife: Identifying and evaluating disease risks. *Transactions of the North American Wildlife and Natural Resources Conference* 57: 466–473.
- , ——, C. E. Couvillin, H. W. Yoder, and W. E. Howerth. 1985. Diseases diagnosed in Wild Turkeys (*Meleagris gallopavo*) of the southeastern United States. *Journal of Wildlife Diseases* 21: 386–390.
- Ebbinge, B. 1982. The status of *Branta leucopsis* in 1980–81. *Aquila* 89: 151–161.
- Edgar, S. A. 1986. Coccidiosis in turkeys: Biology and incidence. In: L. R. McDougald, J. P. Joyner, and P. L. Long (eds.), *Proceedings of the Georgia Coccidiosis Conference*. Athens, University of Georgia: pp.116–123.
- Faddoul, G. P., G. W. Fellows, and J. Baird. 1967. Pasteurellosis in wild birds in Massachusetts. *Avian Diseases* 11: 413–418.
- Fagasinski, A. 1962. Helminth parasites of domestic galliform birds in Poland. *Acta Parasitologica Polonica* 10: 347–368.
- Foreyt, W. 1990. Section 1. Diagnostic Parasitology. In: *Veterinary Parasitology Reference Manual*, 2nd ed. Ames, Iowa, Iowa State University Press: pp. 3–5.
- Fritz, B. A., C. B. Thomas, and T. M. Yuill. 1992. Serological and microbial survey of *Mycoplasma gallisepticum* in Wild Turkeys (*Meleagris gallopavo*) from six western states. *Journal of Wildlife Diseases* 28: 10–20.
- Gardiner, J. L., and E. E. Wehr. 1949. Some parasites of the Wild Turkey (*Meleagris gallopavo silvestris*)

- in Maryland. *Proceedings of the Helminthological Society of Washington* 16: 16–19.
- Gibbs, B. J. 1962. The occurrence of the protozoan parasite *Histomonas meleagridis* in the adult and eggs of the cecal worm *Heterakis gallinae*. *Journal of Protozoology* 59: 877–884.
- Gregg, D. A., L. O. Olsen, and E. L. McCune. 1974. Experimental transmission of *Pasteurella multocida* from raccoons to turkeys via bite wounds. *Avian Diseases* 18: 559–564.
- Hinshaw, W. R., K. W. Niemann, and W. H. Busic. 1932. Studies of tuberculosis of turkeys. *Journal of the American Veterinary Medical Association* 80: 765–777.
- Hon, L. T., D. J. Forester, and L. E. Williams, Jr. 1975. Helminths of Wild Turkeys in Florida. *Proceedings of the Helminthological Society of Washington* 42: 119–127.
- Hopkins, B. A., J. K. Skeeles, G. E. Houghten, D. Siagle, and K. Gardner. 1990. A survey of infectious diseases in Wild Turkeys (*Meleagris silvestris*) from Arkansas. *Journal of Wildlife Diseases* 26: 468–472.
- Howerth, W. E. 1985. Salmonellosis in a Wild Turkey. *Journal of Wildlife Diseases* 21: 433–434.
- Hurst, G. A. 1980. Histomoniasis in Wild Turkeys in Mississippi. *Journal of Wildlife Diseases* 16: 357–358.
- , L. W. Turner, and F. S. Tucker. 1979. Capillariasis in penned Wild Turkeys. *Journal of Wildlife Diseases* 15: 395–397.
- Irwin, R. J., C. Poppe, S. Messier, G. G. Finley, and J. Oggel. 1994. A national survey to estimate the prevalence of *Salmonella* species among Canadian registered commercial turkey flocks. *Canadian Journal of Research* 58: 263–267.
- Kanev, I., 1985. *On the Morphology, Biology, Ecology and Taxonomy of Echinostoma revolutum group (Trematoda: Echinostomatidae: Echinostoma)*. Doctoral dissertation, Sofia, Bulgarian Academy of Sciences: 467 pp.
- Kreier, J. P. 1993. *Parasitic Protozoa*, 2nd Ed., Vol. 4. New York, Academic Press: 323 pp.
- Levine, N. D. 1980. *Nematode Parasites of Domestic Animals and Man*. Minneapolis, Minnesota, Burgess Publishing Company: 477 pp.
- Lund, E. E., A. M. Chute, and G. C. Wilkens. 1975. The Wild Turkeys as a host for *Heterakis gallinarum* and *Histomonas meleagridis*. *Journal of Wildlife Diseases* 11: 376–381.
- Maxfield, B. G., W. M. Reid, and F. A. Hayes. 1963. Gastrointestinal helminths from turkeys in southeastern United States. *Journal of Wildlife Management* 27: 261–271.
- Montali, R. J., M. Bush, C. O. Thoen, and E. Smith. 1976. Tuberculosis in captive exotic birds. *Journal of the American Medical Association* 169: 920–927.
- Morgan, B. B., and P. A. Hawkins. 1949. *Veterinary Helminthology*. Minneapolis, Minnesota, Burgess Publishing Company: 400 pp.
- Ogilvie, M., and H. Boyd. 1975. Greenland Barnacle Geese in the British Isles. *Wildfowl* 26: 139–147.
- Prestwood, A. K., F. E. Kellogg, and G. L. Doster. 1975. Parasitism among Wild Turkeys in the Southeast. In: L. K. Halls (ed.), *Proceedings of the Third National Wild Turkey Symposium*. Austin, Texas, Texas Chapter, Wildlife Society: pp. 27–32.
- Rocke, T. E., and T. M. Yuill. 1987. Microbial infections in a declining Wild Turkey population in Texas. *Journal of Wildlife Management* 51: 778–782.
- Roslien, D. J., and A. O. Haugen. 1970. Some blood parasite and disease antibody findings in Wild Rio Grande Turkeys stocked in Iowa. *Proceedings of the Iowa Academy of Science* 77: 93.
- Stegmann, B. K. 1938. Bases of the ornithogeographic division of the Palearctic. In: *Fauna of the USSR, Birds*, Vol. 1. Moscow and Leningrad, Acad. Sci. USSR: 157 pp.
- Singbeil, B. A., A. A. Bickford, and J. H. Stolz. 1993. Isolation of *Mycobacterium avium* from Ringneck Pheasants (*Phasianus colchicus*). *Avian Diseases* 37: 612–615.
- Sorensen, R. E., I. Kanev, B. Fried, and D. J. Minchella. 1997. The occurrence and identification of *Echinostoma revolutum* from North American *Lymnea elodes* snails. *Journal of Parasitology* 83: 169–170.
- Svrcek, S., O. J. Vrtiak, B. Kapitancik, T. Pauer, and Z. Koppel. 1966. Wild birds and domestic pigeons as sources of avian tuberculosis. *Rozhledy v Tuberkulose a v Nemocech Plicnich* 26: 659–67.
- Vassilev, I., and P. Kamburov. 1965. Helminthofauna of the Wild Turkey (*Meleagris gallopavo silvestris*) in Bulgaria. *Izvestiia na Tsentralna Khelminthologichna Laboratoriia* 10: 5–9.
- , and ———. 1969. The turkey, a host of *Microsomacanthus paracompressa* (Czaplinski, 1956) Spasskaja et Spassky, 1961. *Izvestiia na Tsentralna Khelminthologichna Laboratoriia* 13: 29–31.
- Veatch, J. K., R. D. Applegate, and S. J. Osborne. 1998. Serologic incidence of some diseases in Kansas Wild Turkeys. *Avian Diseases* 42: 393–396.
- Yesou, P. 1980. L'oie des neiges *Anser caerulescens* en France. *Alauda* 48: 21–26.
- . 1981. De nouvelles données sur l'oie des neiges *Anser caerulescens* en Europe occidentale. *Alauda* 49: 145–146.
- Zinkl, J. G., N. Dey, J. M. Hyland, J. J. Hurt, and K. L. Heddleston. 1975. An epornitic of avian cholera in waterfowl and Common Crows in Phelps County, Nebraska, in the spring. *Journal of Wildlife Diseases* 13: 194–198.