

University of Nebraska - Lincoln

DigitalCommons@University of Nebraska - Lincoln

Other Publications in Zoonotics and Wildlife
Disease

Wildlife Disease and Zoonotics

July 2004

Parasites of Caribou (3): Tapeworm Cysts

Follow this and additional works at: <https://digitalcommons.unl.edu/zoonoticspub>



Part of the [Veterinary Infectious Diseases Commons](#)

"Parasites of Caribou (3): Tapeworm Cysts" (2004). *Other Publications in Zoonotics and Wildlife Disease*. 22.

<https://digitalcommons.unl.edu/zoonoticspub/22>

This Article is brought to you for free and open access by the Wildlife Disease and Zoonotics at DigitalCommons@University of Nebraska - Lincoln. It has been accepted for inclusion in Other Publications in Zoonotics and Wildlife Disease by an authorized administrator of DigitalCommons@University of Nebraska - Lincoln.



Wildlife Diseases FACTSHEET

Parasites of Caribou (3): Tapeworm Cysts

Introduction

All wild animals carry diseases. In some cases these might be of concern if they can spread to humans or domestic animals. In other cases, they might be of interest if they impact on the health of our wild herds, or simply if they have been noticed by hunters and you would like to know more.

This factsheet is one of a series produced on the common diseases of caribou and covers the cyst form of three common tapeworms. Two (*Taenia hydatigena* and *Taenia krabbei*) exist on both the island of Newfoundland and in Labrador, while the third (*Echinococcus granulosus*) is so far only reported in Labrador. The first two have no known public health importance while the third, known also as hydatid disease, can be a cause of human illness.

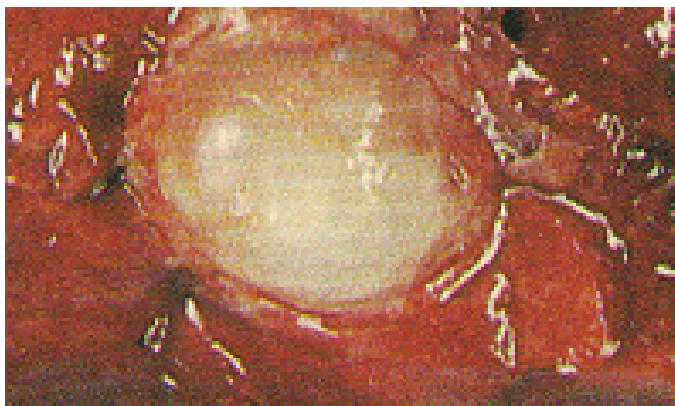


Figure 1: Hydatid cyst in a lung

Life Cycle of Tapeworms

Tapeworms are a type of parasite that usually require two different hosts to complete their life cycle (Figure 3). These hosts are a predator and a prey




Figure 2: *Taenia hydatigena* cyst in a liver

species. The common predators are wolves (Labrador), coyotes, bears, lynx, and dogs (depending on the parasite); the prey can be caribou, moose or domestic animals such as sheep and cattle. Humans can become an accidental host as will be described.

The adult stage of the parasite is called the tape and lives in the intestines of the predator, or final host. This tape can be very long or hardly visible depending on the parasite. When visible it looks like a long flat measuring tape. It has a head (or scolex) which attaches onto the wall of the intestine by way of a ring of hooks and 4 suckers (Figure 4). This allows the parasite to live off the food in the animal's gut.

This adult stage releases eggs into the gut which leave in the feces and contaminate the ground and possibly also the animal's fur.

Copies of this and other publications may be obtained from the Department's Regional Offices, the factsheet author or by visiting our website at <http://www.gov.nl.ca/agric/>.



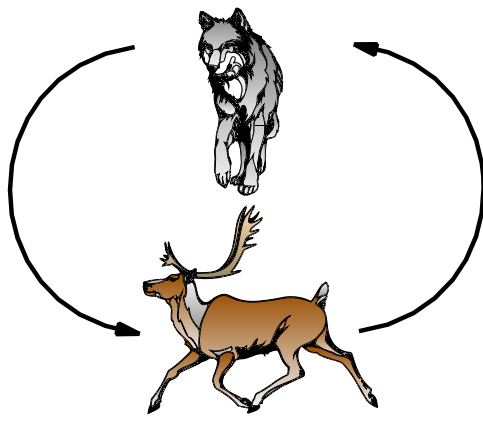


Figure 3: Predator - Prey Life Cycle

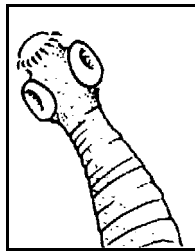


Figure 4: Scolex of the adult tapeworm

The eggs are eaten by the caribou and develop in the body into a cyst form. As it does not produce any eggs it is called the intermediate stage.

These cysts can be very small or large depending on the species of parasite and the part of the body they occupy. They either stay inactive in the body until the prey is eaten by the predator or else they may become neutralized by the body's immune system. Once in the predator again, the cyst is activated and the parasite develops into the tape form to continue the cycle.

The cyst looks different depending on the parasite. For *Taenia krabbei* (in muscle) it is small with almost no fluid in it. For *Taenia hydatigena* (liver), the cyst is about the size of a large grape with a lot of fluid. For *Echinococcus granulosus* (lungs) the cyst can be golf ball size with a lot of fluid.

Taenia krabbei

The cyst can be found occasionally in the muscles and heart of caribou though it is much more common in the moose. Sometimes there are only a few that can be easily picked out while other times there are hundreds visible. They are yellowish and a bit bigger than a grain of rice. Though there is no

direct risk to human health from eating the cooked meat it is not appetizing to look at if in large numbers.

Taenia hydatigena

This tapeworm cyst is fairly common, usually seen singly in the liver of caribou (Figure 2). There is a white spot in the cyst identifying the immature scolex of the tapeworm. As these can be easily removed there is no direct risk to eating these livers.

***Echinococcus granulosus* (Hydatid disease)**

This cyst is quite common in the lungs of Labrador caribou. Though not causing a serious health risk to the caribou, it can harm people. If infected lungs are fed to dogs, they can develop the adult tape which will shed eggs that can stick to the dog's fur. If someone then pets the dog and touches their mouth they can infect themselves with this parasite. It can also be picked up by handling contaminated pelts (such as wolf). In humans this cyst can develop in many parts of the body, sometimes causing serious illness.

Though there are no reports of hydatid disease on the island of Newfoundland, there is a potential for it to enter. Wolves are increasing in number in southern Labrador with the possibility existing of them crossing over on the ice onto the island. If this were to happen they could infect caribou and moose while also possibly introducing the disease to domestic sheep.

More Information

For more information please contact the author, a Regional Veterinarian or your local Conservation Officer.

Dr. Hugh Whitney
Provincial Veterinarian
Animal Health Division
P. O. Box 7400
St. John's, NL A1E 3Y5

(709) 729-6879 phone; (709) 729-0055 fax
e-mail: hughwhitney@gov.nl.ca

Photo credits:

Figure 1: Ontario Ministry of Natural Resources

Figure 2: Dr. Chris Harvey-Clarke